

Leydig Cell Tumor Presented as Retroperitoneal Mass: A Case Report

Dr. Shruthi Surendran¹, Dr Kalaranjini K V², Dr Vivek George³

¹Senior Resident, Sree Gokulam Medical College and Research Foundation, Trivandrum, Kerala - 695607

²Professor, Sree Gokulam Medical College and Research Foundation, Trivandrum, Kerala - 695607

³Professor and HOD, Sree Gokulam Medical College and Research Foundation, Trivandrum, Kerala - 695607

Abstract: Background: Leydig cell tumour is a rare tumour of the male testicular interstitium. Testicular Leydig cell tumours can occur at any age but they are common in prepubertal boys and in men aged 30 to 60 years. Leydig cell tumours are always benign in children, whereas in adults they are malignant in 10% of cases. The etiology of LCTs is not completely understood and appears to be multifactorial. In this case, the risk factor which can be attributed to LCT is cryptorchidism. Case details: A 60 year old male came with complaints of recurrent lower abdominal pain. On evaluation, he was diagnosed as acute appendicitis with mucocele formation and an incidental retroperitoneal mass. He underwent exploratory laparotomy and excision of the retroperitoneal mass along with appendectomy. Histopathology: The tumour had a nodular smooth surface with lobules of pale brown areas on cut section. Microscopically a circumscribed neoplasm arranged in solid pattern and cells with abundant granular cytoplasm, round nuclei was seen. There was also characteristic Reinke crystals, which was suggestive of a Leydig cell tumor. Conclusion: Undescended testes not operated early in life are seriously damaged and is a major risk factor for the development of LCT. Hence proper workup with hormonal assays, cross-sectional imaging and testicular biopsies are recommended. Surgery is the gold standard treatment option for LCT along with adjuvant therapies in high risk cases.

Keywords: Leydig cell tumor, Cryptorchidism, Retroperitoneal mass, Sex cord - stromal tumors

1. Background

Testicular neoplasms are classified into 2 major groups: Germ cell tumours and sex cord - stromal tumours. Sex - cord stromal tumours are derived from 2 types of somatic cells: the Leydig cells and the Sertoli cells. Leydig cells are interstitial cells located between the seminiferous tubules and they produce testosterone when stimulated by luteinizing hormone. They are thus involved in the development of secondary male characteristics and maintenance of spermatogenesis. (1)

Leydig cell tumour is a rare tumour of the male testicular interstitium. The etiology of LCTs is not completely understood and appears to be multifactorial. Testicular Leydig cell tumours can occur at any age but they are common in prepubertal boys and in men aged 30 to 60 years. Leydig cell tumours are always benign in children, whereas in adults they are malignant in 10% of cases.

Leydig cell tumours are hormonally active and considered as one of the steroid secreting tumors. They produce mainly testosterone, but can also produce oestrogen by either direct production of oestradiol or by peripheral aromatization of the testosterone moiety. (3) In androgen secreting tumours, boys usually present with symptoms of precocious puberty, whereas in adults, most patients are asymptomatic as the excess androgen rarely causes notable effects. (4) In oestrogen secreting tumours, boys usually present with gynecomastia and breast tenderness associated with feminine hair distribution and gonadogenital underdevelopment, whereas adults generally present with gynecomastia associated with loss of libido, erectile dysfunction, impotence and infertility. Physical examination of testes usually reveals an intratesticular mass on palpation. (5) If the tumour is

impalpable, ultrasonography is the investigative procedure of choice. (6)

Here we are presenting a case of an elderly male with history of cryptorchidism who presented to us with complaints of recurrent abdominal pain. After adequate evaluation he underwent retroperitoneal mass excision which on histopathology was found to be Leydig cell tumour.

2. Case Report

A 60 - year - old unmarried gentleman, came to the General Surgery OPD with the complaints of recurrent right sided lower abdominal pain for 5months duration. He had history of bilateral undescended testis and hypospadias. Corrective surgery for hypospadias was done 20 years back. Clinical examination was normal except for Right lower quadrant tenderness. USG Abdomen showed a tubular aperistaltic hypoechoic lesion in the right iliac fossa suggestive of Acute Appendicitis. He was further evaluated with CECT Abdomen which again suggested acute appendicitis with mucocele formation and extensive fat stranding around it. There was an incidental retroperitoneal mass on CECT.

Surgery

After proper optimisation, he underwent exploratory laparotomy. Intra - operatively a retroperitoneal globular cystic swelling was seen measuring about 1.5cm in diameter at the level of L5. The swelling was excised in - toto. Appendix was released from all the adhesions and appendectomy was also done. There was no ascites or any significant lymph nodes. There were no swellings/ intraperitoneal testes on the left side.

Histopathology Gross

Volume 13 Issue 10, October 2024

Fully Refereed | Open Access | Double Blind Peer Reviewed Journal

www.ijsr.net

We received two specimens:

- 1) A nodular mass measuring 2x1.5x1 cm (Figure 1 & 2) - Outer surface of the nodular tissue appears smooth, glistening and on cut section shows lobules of pale brown areas.
- 2) An appendicectomy specimen measuring 3cm in length and 0.5cm in diameter. (Figure 3) Appendicectomy specimen appears normal on cut section.

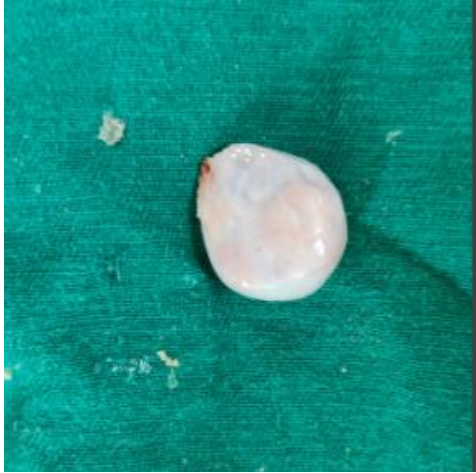

Figure 1

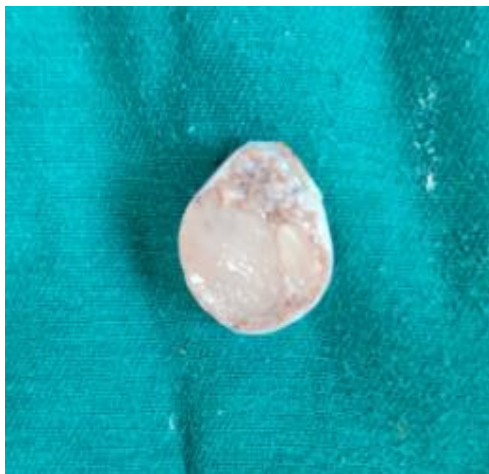

Figure 2

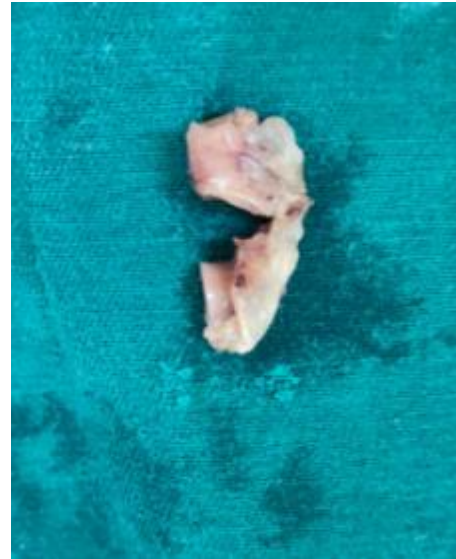


Figure 3

Microscopy

Sections from the nodular mass showed a well circumscribed neoplasm arranged in solid pattern and vague lobules separated by thin fibrous bands (Figure 4 & 5).

Individual cells had abundant granular eosinophilic cytoplasm and round to oval nuclei with fine chromatin. Some showed prominent nucleoli. Reinke crystals were noted. Few cells had clear cytoplasm. (Figure 6)

Periphery of the neoplasm showed hyalinized seminiferous tubules and rete testes. (Figure 7)

There was no evidence of infiltrative borders, marked cytological atypia, increased mitosis, vascular invasion, necrosis. All sections from the appendix were normal.

The histological features of the nodular retroperitoneal mass was consistent with Sex cord stromal tumour - Benign Leydig cell tumor. TNM Classification (AJCC 8th edition): pT1aN not assigned - Stage 1

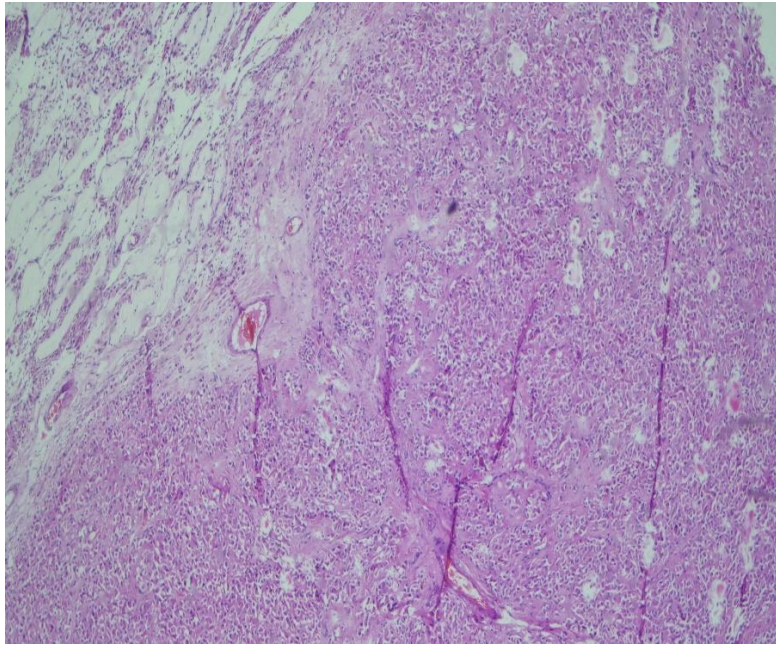


Figure 4: (100x magnification)

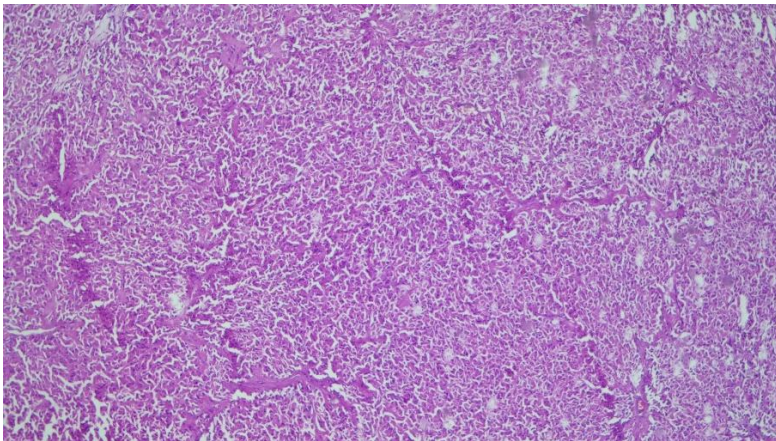


Figure 5: (100x magnification)

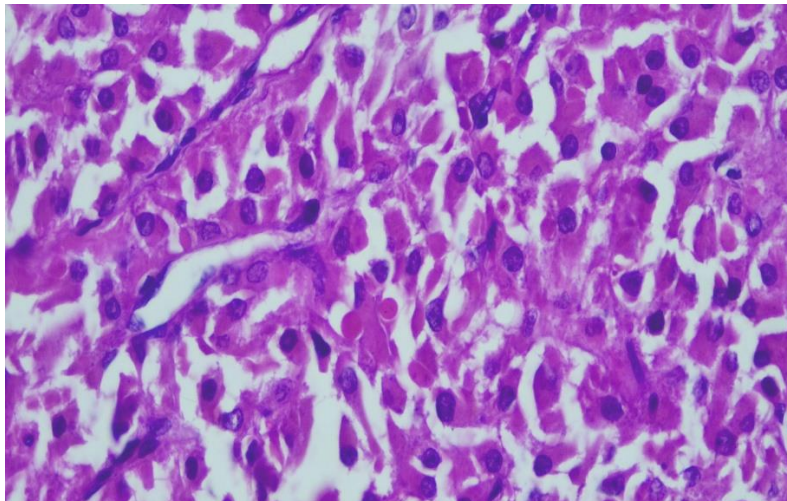


Figure 6: (400x magnification)

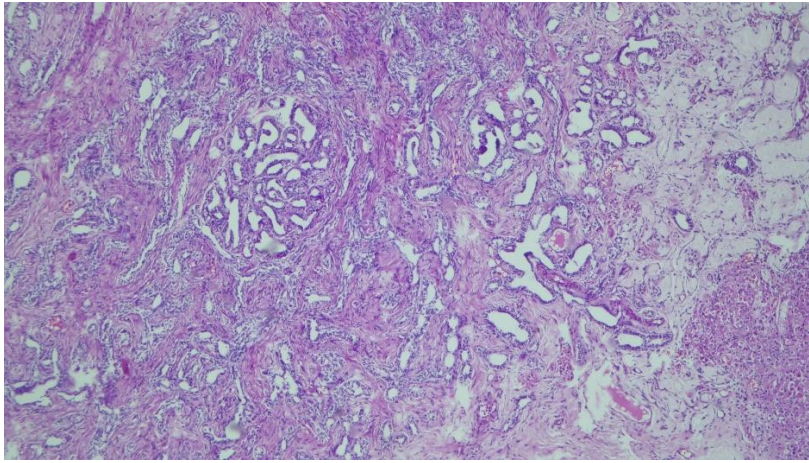


Figure 7: (100x magnification)

Follow Up

Post operative course was uneventful and he was discharged and was advised follow up. He is doing well on followup. On OPD visit three months post operatively, his serum testosterone was 104ng/ml (normal 5 - 100ng/ml). He did not take any adjuvant treatment and was advised to continue surveillance as he had stage 1 disease without any high risk features.

3. Discussion

Here we presented a case of a 60 year old man with history of bilateral cryptorchidism who presented in later life with Leydig cell tumour. So cryptorchidism is a major risk factor which can lead to the development of LCT.

Primary testicular neoplasms constitute the most common solid organ malignancy seen in young males aged 15 and 35. Certain risk factors are associated with the development of testicular neoplasms, and these include cryptorchidism, hypospadias, family history, infertility, klinefelters syndrome, contralateral testicular malignancy and even trauma. (7)

Testicular neoplasms are classified into germ cell tumors and sex cord stromal tumors. LCT comes under sex cord stromal tumors. There are multiple factors associated with the development of LCT. Cryptorchidism is the most common sexual developmental anomaly of childhood and has been reported in the literature to be associated with LCT. It is a major causative risk factor in male adult infertility as it exposes the testes to a higher temperature than normal, leading to impaired spermatogenesis. Unilateral cryptorchidism is more common than bilateral cryptorchidism at a ratio of 4: 1. Cases of LCT with a history of bilateral congenital cryptorchidism have rarely been reported. Untreated bilateral cryptorchidism is associated with impairment in spermatogenesis, with 100% oligospermia and 75% azoospermia. Cryptorchid testes of adults are much smaller than normal. The tubules are atrophic, the germinal epithelium is generally largely absent and the Leydig cells are vacuolated. (8)

These tumors are usually associated with the deranged hormonal profile, attributing to the endocrine abnormalities. Most cases follow a benign clinical course, adjuvant therapy is not usually warranted, except for the 2.5 - 15% of LCT that

behave aggressively. These include tumor size greater than 5cm, moderate or severe nuclear atypia, vascular or lymphatic invasion, more than 5mitosis per high power field, necrosis and infiltrative margins. (9)

Primary orchidectomies are usually refused by the patients. Orchidopexy can be considered as a treatment option in children. However long - term issues related to infertility and testicular cancers cannot be prevented. (10)

Surgical resection remains the gold standard treatment for both benign and malignant forms of LCT. Radical orchidectomy with or without Retroperitoneal Lymph node dissection (RPLND) is currently recommended as the standard surgical procedure for all benign testicular neoplasms. The role of testis sparing surgery (TSS) has also been evaluated as a reasonable treatment option for benign LCT. (11)

Adjuvant chemotherapy was associated with improved survival for patients with advanced stage sex cord stromal tumors. No clear benefit was found for those with early stage disease. (12)

4. Conclusion

Undescended testes not operated early in life are seriously damaged. Considering the relatively high frequency of malignant germ cell tumors in adults with cryptorchidism, testicular biopsies should be performed frequently. Radical surgical resection with RPLND remains the only definite treatment along with adjuvant treatment for high risk cases.

References

- [1] Osama M. Al - Agha, MD; Constantine A. Axiotis, MD *Arch Pathol Lab Med* (2007) 131 (2): 311–317.
- [2] Gheorghisan - Galateanu, A. A. Leydig cell tumors of the testis: a case report. *BMC Res Notes* 7, 656 (2014). <https://doi.org/10.1186/1756-0500-7-656>
- [3] Lantzsch, T., Stoerer, S., Lawrenz, K. *et al.* Sertoli - Leydig cell tumor. *Arch Gynecol Obstet* 264, 206–208 (2001). <https://doi.org/10.1007/s004040000114>.
- [4] Maqdasy, S., Bogenmann, L., Batisse - Lignier, M. *et al.* Leydig cell tumor in a patient with 49, XXXXY karyotype: a review of literature. *Reprod Biol*

- Endocrinol* **13**, 72 (2015). <https://doi.org/10.1186/s12958-015-0071-7>
- [5] Kyle M. Devins, Robert H. Young, Esther Oliva, Sex Cord - Stromal Tumors of the Ovary: An Update and Review. Part II — Pure Sex Cord and Sex Cord - Stromal Tumors, *Advances in Anatomic Pathology*, 10.1097/PAP.0000000000000436, **31**, 4, (231 - 250), (2024).
- [6] Dimitrios Nasioudis, Spyridon A. Mastroyannis, Ashley F. Haggerty, Emily M. Ko, Nawar A. Latif, Ovarian Sertoli - Leydig and granulosa cell tumor: comparison of epidemiology and survival outcomes, *Archives of Gynecology and Obstetrics*, 10.1007/s00404-020-05633-z, **302**, 2, (481 - 486), (2020).
- [7] Carvajal - Carmona, L. G., Alam, N. A., Pollard, P. J., Jones, A. M., Barclay, E., Wortham, N., Pignatelli, M., Freeman, A., Pomplun, S., Ellis, I., Poulosom, R., El - Bahrawy, M. A., Berney, D. M., & Tomlinson, I. P. (2006). Adult Leydig cell tumors of the testis caused by germline fumarate hydratase mutations. *The Journal of Clinical Endocrinology and Metabolism*, *91* (8), 3071–3075.
- [8] Cheville, J. C., Sebo, T. J., Lager, D. J., Bostwick, D. G., & Farrow, G. M. (1998). Leydig cell tumor of the testis: A clinicopathologic, DNA content, and MIB - 1 comparison of nonmetastasizing and metastasizing tumors. *American Journal of Surgical Pathology*, *22* (11), 1361–1367.
- [9] Farkas, L. M., Székely, J. G., Pusztai, C., & Baki, M. (2000). High frequency of metastatic Leydig cell testicular tumours. *Oncology*, *59* (2), 118–121.
- [10] Featherstone, J. M., Fernando, H. S., Theaker, J. M., Simmonds, P. D., Hayes, M. C., & Mead, G. M. (2009). Sex cord stromal testicular tumors: A clinical series uniformly stage I disease. *Journal of Urology*, *181* (5), 2090–2096.
- [11] Liu, G., Duranteau, L., Carel, J. C., Monroe, J., Doyle, D. A., & Shenker, A. (1999). Leydig cell tumors caused by an activating mutation of the gene encoding the luteinizing hormone receptor. *New England Journal of Medicine*, *341* (23), 1731–1736.
- [12] Thambi R, Pothen L, Emmanuel KM, et al. Leydig cell tumor of testis with indeterminate features. *Indian J Cancer* 2015; 52: 529–30.