

Observational Prospective Study of Different Reconstructive Surgery in Oral Cavity Carcinoma

Dr. Dhavalkumar S Chaudhari¹, Dr. Sushil Akruwala²

¹Senior Resident Doctor, Department of General Surgery, GCS MC Hospital and Research Centre, Ahmedabad, Gujarat, India

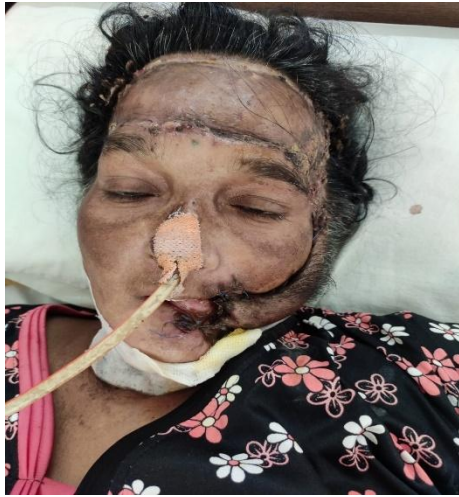²Professor, Department of General Surgery, Department of General Surgery, GCS MC Hospital and Research Centre, Ahmedabad, Gujarat, India

Abstract: ***Objectives & Aims:** 1) To evaluate the outcome of different Reconstructive surgery in oral cavity carcinoma 2) To determine the factors which increase the complication in post op reconstructive surgery (like – diabetes, hypertension, smoking etc. 3) The effect of flap transfer on complication or on post op rehabilitation of patients in oral cavity carcinoma. **Methodology:** This is a prospective study conducted at gcs hospital, Ahmedabad between Oct. 2021 to June 2022. Sample size is 40 patients with case of oral cavity carcinoma, out of which some cases underwent for PMMC Flap, Radial forearm free flap, ALT free flap, fibula flap, forehead rotational flap, deltopectoral flap and local flap. **Conclusion:** 1) Risks have not increased complications in PMMC or Free flap group in our study. Various other studies have similar results however a larger patient pool may be needed to assess them. 2) The PMMC flap is more favorable for patients with possibly lethal pre-op morbidities, when a long operation is not advisable and a small defect is expected as compared to the longer operation duration of ALT free flap & Radial free flap. Though the flap related complications & donor site related complications are more with forehead rotational flap as compared to PMMC. ALT & Radial forearm free flap, statistically there is no significant difference. Also in the functional post-op outcomes there is minimally statistically significant difference with PMMC flap, ALT free flap or Radial free flap, local flaps and other reconstructive surgery.*

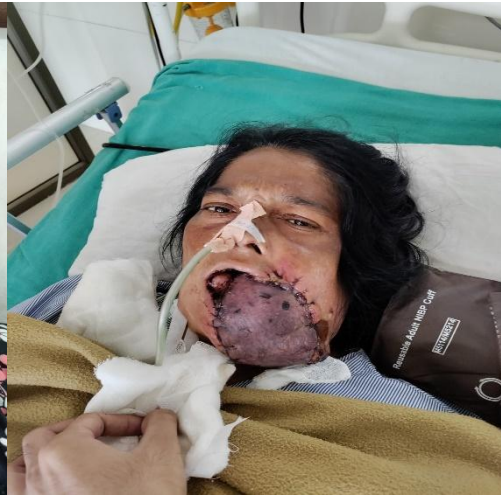Keywords: PMMC – pectoralis major myocutaneous, ALT – anterio lateral thigh

1. Introduction

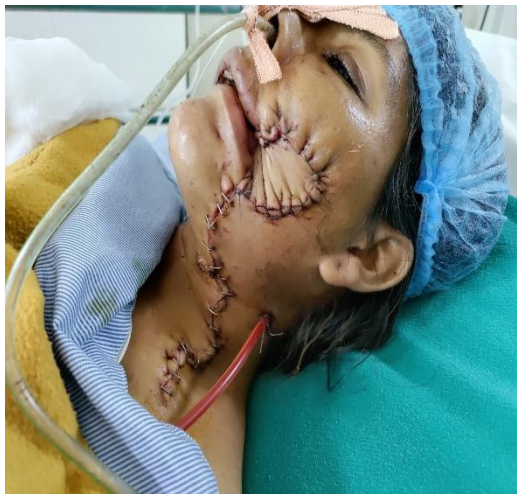- 1) Reconstruction of the oral cavity is challenging due to the variety of tissues whose structural deficiencies must be corrected. This is because the defect includes a variety of structures: skin, mucosa, soft tissue and bone. In particular the anatomy of the oral cavity is complicated and each structure plays a specific role in different functions like speech, swallowing and facial expression. In addition defects in one specific functional unit can affect adjacent structures. Before reconstruction a comprehensive assessment of the defect is required. Disease status and tumour staging may also affect postoperative treatment and outcomes.
- 2) The goals of reconstructive surgery for defects created by oncologic oral cavity surgery, in order of priority are 1) separation of upper aerodigestive tract contamination from other critical compartments, such as intradural, mediastinal and deep neck contents; 2) maximization of function including breathing, speech, swallowing, vision and hearing; 3) optimization of form of cosmesis.
- 3) Primary closure is an option for reconstruction of cutaneous defects and select oral cavity and pharyngeal defects. Incisions that parallel to the relaxed skin tension lines respects facial esthetic units and can be closed with the less tension to decrease scarring. Z-plasty can be used to reorient an unfavorable line of closure into a relaxed skin tension line.
- 4) Non vascularized grafts including split-thickness and full thickness skin grafts, cartilage grafts and bone grafts can be used in selected situations, prior radiation therapy to the recipient area limits the use of some non vascularized grafts particularly bony and cartilaginous grafts.
- 5) Adjacent tissue transfer and local flaps commonly used designs include advancement, rotation, transposition, rhomboid and bilobed flaps, most local flaps depend on the subdermal plexus of capillaries.
- 6) Regional flaps are based on axial blood flow and are located at a significant distance from the donor site. Harvest of flaps requires maintenance of the axial blood supply and reaching the defect frequently requires creation of subcutaneous tunnel. Most used pectoralis major myocutaneous regional flap also used as a muscle only flap based on the pectoral branch of thoracoacromial artery.
- 7) Free tissue transfer entails removal of composite tissue from a distance along with its blood supply and revascularization through microvascular anastomosis of one or more arteries and veins within or near the reconstructive field. Most used are the radial forearm, lateral arm, anteriolateral thigh when soft tissue and epithelial lining is needed. Fibula and scapula flaps are used when soft tissue, epithelial lining and bone are needed. Rectus and latissimus can be useful for large defects requiring muscle only or muscle with skin.



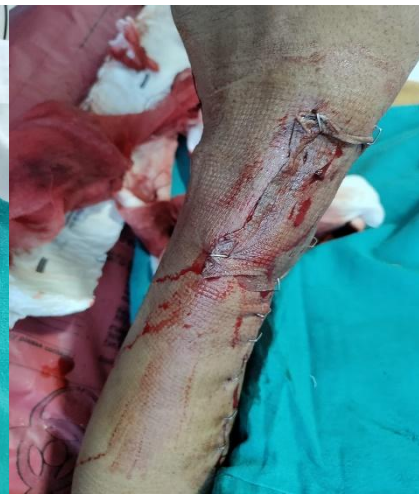FOREHEAD FLAP



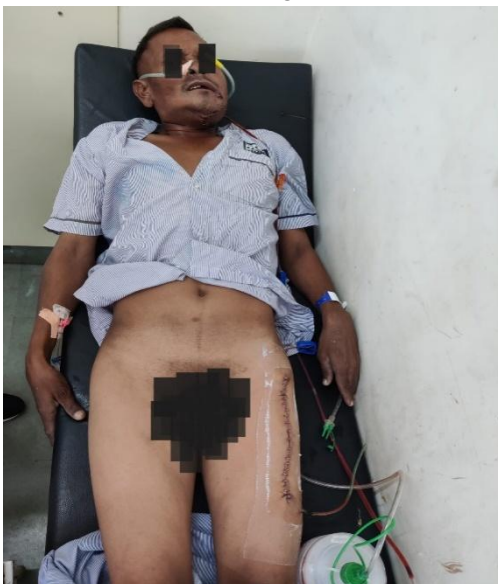ALT FLAP



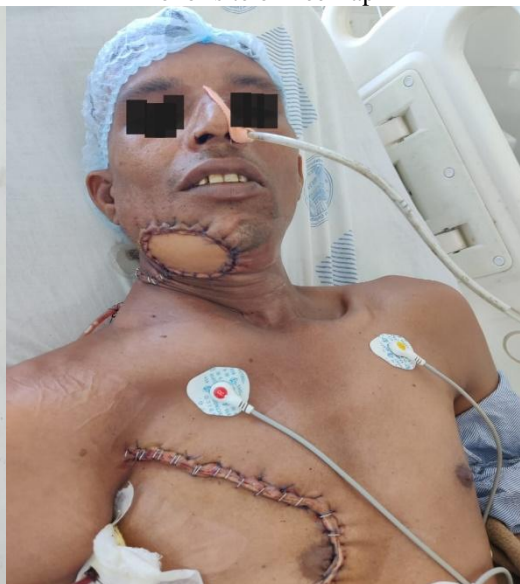RADIAL FOREARM FREEFLAP



Donor site of free flap



donor site of ALT flap



PMMC Flap

2. Aims & Objectives

- To evaluate the outcome of different reconstructive surgery in oral cavity carcinoma
- To determine the factors which increase the complication in post op reconstructive surgery (n like- diabetes , hypertension , smoking etc.)

- The effect of flap transfer on complication or on post op rehabilitaion of patients in oral cavity cancer.

3. Materials and Methods

Data consists of primary data collected by the principal investigator directly from the patients who were admitted

Volume 13 Issue 1, January 2024

Fully Refereed | Open Access | Double Blind Peer Reviewed Journal

www.ijsr.net

from OPD in the GCS Medical College and hospital. It was a Observational Study, for a period of one year January 2021 to December 2021 and the sample size was 40 cases.

Inclusion Criteria:

- Biopsy proven carcinoma of oral cavity
- Age between 30 years to 70 years
- Clinically fit Patient for undergo surgery
- Patient who give the consent for study

Exclusion Criteria:

- Locally advanced malignancy
- Recurrence of oral cavity carcinoma
- Patient who declined surgery
- Patient who taken radiotherapy in pre-op status
- Unfit patient for undergo surgery
- Patients who do not give consent for study

THIS prospective study was carried on 40 patients from octomber 2021 to June 2022 with case of oral cavity carcinoma who underwent for surgery for carcinoma of oral cavity with reconstructive surgery.

Relevant data collected using the records and following parameters observed:

- 1) Age
- 2) BMI
- 3) Comorbidity -diabetes
 - Hypertension
 - Cardiac disease
- 4) Addiction history (tobacco, smoking etc.)
- 5) Operation duration (in minutes)
- 6) Complications –related to reconstructive surgery (like necrosis, dehiscence, congestion, orocutaneous fistula etc.)
- 7) Post op ICU and Hospital stay
- 8) Decannulation (ryel’s tube out time)
- 9) Oral realimentation (taking oral diet)

All the procedurefor oral cavity carcinoma surgery and post op care of patient performed by experienced surgeon and their well trained staff with the gentle tissue handling and care.

4. Observation & Results

- Number of patients: 40
- PMMC Flap - 15 cases
- Radial forearm flap -08 cases
- ALT free flap -06 cases
- Fibula flap -02 cases
- Forehead rotational flap -04 cases

- Deltopectoral flap - 01 case
- Local flap -04 cases

Table 1: Patient characteristic

Characteristic	Value
Mean age	56 years
H/O Tobacco	35
H/O Smoking	22
H/O Alcohol	10
Diabetes	16
Hypertension	20

Table 2: Average operation duration (in minutes) for reconstruction (flap) surgery

Type of flap	Duration (AVG.)
PMMC flap	90
Radial forearm flap	120
ALT flap	130
Fibula flap	150
Forehead flap	90
Deltopectoral Flap	120
Local flap	60

Table 3: Flap related complication rate associated with risk factors

	Complication	Non-complication
Smoking	6 (27%)	16 (73%)
Non smoking	1 (5%)	17 (95%)
Hypertension	2 (1%)	18 (99%)
Non hypertension	2 (1%)	18 (99%)
Diabetes	4 (25%)	12 (75%)
Non diabetes	2 (8%)	22 (92 %)

In our study, complication rates for patients with hypertension and diabetes were 1% and 25% respectively in the smoking patient group, complication occurred in 27 %.

For above mention data on flap related complication rate after fisher’s exact test p value is >0.05 associated with smoking, hypertension, diabetes.

So, there is no statistically association of either smoking, hypertension, diabetes with flap related complications.

Table 4.1: Flap related complication rate associated with the type of flap transfer

Flap Type	Complication	Non Complication
PMMC flap	4	11
Radial forearm flap	3	5
ALT flap	3	3
Fibula flap	1	1
Forehead flap	3	1
Deltopectoral Flap	0	1
Local flap	3	1

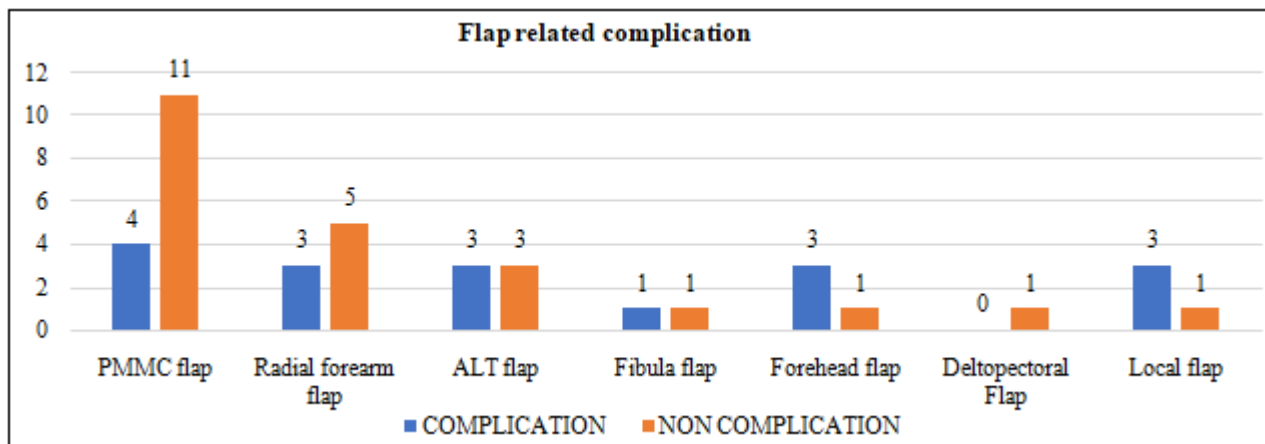


Table 4.2: Flap complication

Flap Type	Flap Failure	Salivary Leak	Infection	Suture Dehiscence
PMMC flap	0	2	1	1
Radial forearm flap	1	0	1	1
ALT flap	1	1	1	0
Fibula flap	0	0	1	0
Forehead flap	1	0	1	1
Deltopectoral Flap	0	0	0	0
Local flap	0	0	2	1




Table 5: Mean post op hospitalization stay (in days)

TYPE OF FLAP	MEAN DURATION (range)
PMMC flap	8 (7-10)
Radial forearm flap	7 (5-20)
ALT flap	6 (5-15)
Fibula flap	8 (6-10)
Forehead flap	10 (8- 18)
Deltopectoral Flap	8
Local flap	10 (8-20)

The mean length of post operative hospitalization was 12 days for the total study. It was slightly longer in the forehead flap and local flap as compared to other reconstructive flap surgery but this difference was not statistically significant.

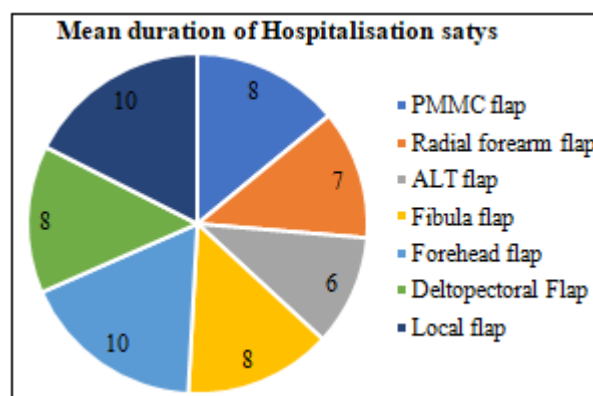


Table 6: Decannulation (RT out) time

Type of Flap	Decannulation (range)
PMMC flap	27 (11-80)
Radial forearm flap	19 (10-60)
ALT flap	18 (8-72)
Fibula flap	28 (24-32)
Forehead flap	30 (25- 74)
Deltopectoral Flap	14
Local flap	16 (12-28)

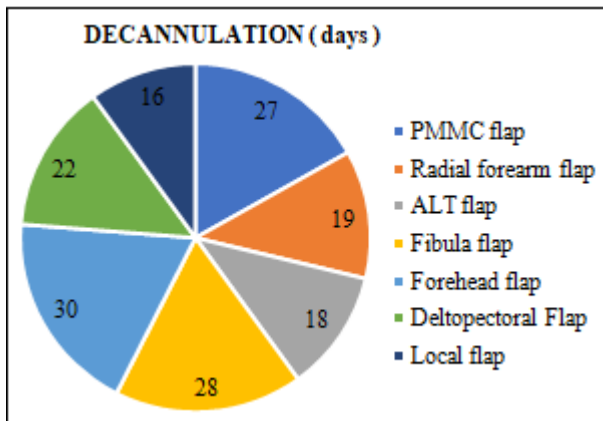
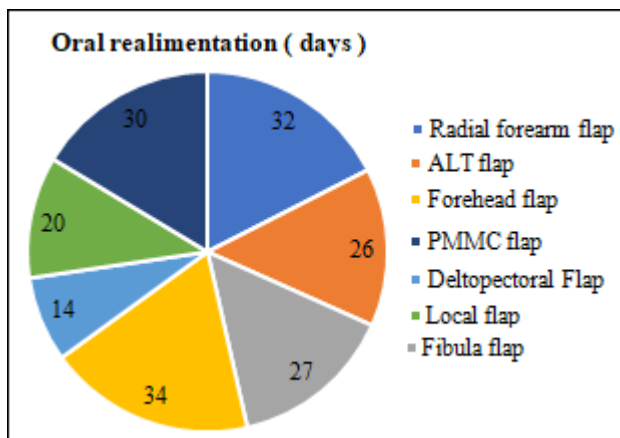


Table 7: Oral realimentation

TYPE OF FLAP	Oral realimentation (range)
PMMC flap	30 (15-105)
Radial forearm flap	32 (10-80)
ALT flap	26 (10-84)
Fibula flap	27 (19-48)
Forehead flap	34 (26-80)
Deltopectoral Flap	14
Local flap	20 (14-30)



for the functional post op outcome two parameters were compared : oral realimentatiin and decannulation. The mean decannulation time was earliest in deltopectoral flap (14 days) and longest in forehead flap (30 days). Oral realimentation was achieved early in deltopectoral flap(14 days) and late in forehead flap (34 days) .

5. Discussion

- In this prospective comparative study of different reconstructive (flap) surgery in oral cavity carcinoma , we stratified patients and procedures to objectively assess functional outcomes and investigate possible correlations between preoperative risk factors and postoperative morbidities.
- PMMC flap is considered “work-horse” pedicle flap for head and neck reconstruction. It has vascular supply from Thoracoacromial artery, with skin padicle surface area of 26 x 16 cm. this include bulky flap, postoperative stenosis, unaesthetic supraclavicular bulge and chest wall deformity, fistula problems, etc.

- Anterolateral Thigh (ALT) free flap is supplied by descending branch of lateral femoral circumflex artery. It has reliable vascularity and significant bulk. It can be easily combined with other tissues if necessary. It is available in emergency settings and can be used for wider surface areas. It has goof cosmetic outcome. It has less reliable healing at leading end when compared to free tissue transfers and it has more complication compared to PMMC flaps. It may not be reliable in obese.
- Radial free flap is taken from volar surface of forearm. It is thin and pliable with dimensions of 13 x 12 cm and vascular supply by radial artery, cephalic vein or venae commitantes. Disadvantages for this flap are tendon exposure, sacrifice of blood supply, unsightly scar, hand stiffness, pain and anesthesia or paresthesia.
- Fibula free flap is taken from the fibla bone which used to reform the mandible. Disadvantages for this flap are sacrifice of blood supply, unsightly scar, pain, prosthetic implant infection, leakage of saliva.
- Paramedian forehead flap used for a variety of defects of the oral cavity. Disadvantages for this flap are wound infection more likely due to hair growth, leakage of saliva, suture dehiscence, flap failure.
- Local flap used for the small defect in oral cavity carcinoma surgery. It can be easily combined with other tissues if necessary. It is available in emergency settings, It has goof cosmetic outcome. It has less reliable healing at leading end when compared to free tissue transfers.
- **High incidences of overall wound complications** and dehiscence at recipient sites were found in the free flap group. However, it should be taken into consideration that free flaps were usually selected to **cosmetic better outcome** as well as the post-op hospital stay due to a **poor general condition** caused by severe preoperative comorbidities.
- Given the level of experience of the single reconstructive team at our medical institution, our results should be **more reliable** than those of studies evaluating **multiple reconstructive** surgical outcomes by minimizing the effect of the learning curve and measurement bias, as shown in other studies.
- In our study, an analysis using Fisher’s exact test revealed that the **risk factors of patients did not increase the incidence of complications**. Similar to our report, multiple centers have previously reported that risk factors of microvascular surgery did not increase the rate of complications. **Bozikov and Arnez** [8] reported that only **diabetic** patients had a **higher** incidence of **free flap complication**, although this fact did not achieve significance in the statistical analysis.
- The functional evaluation did not show meaningful differences between the ALT free flap group and PMMC flap group. **Chepeha et al.** [9] recently reported that an **free Flap group had better functional outcomes** than a PMMC flap group. Although many studies have reported that free flaps are superior, we found no evidence for this hypothesis in our study.

6. Conclusion

- Risks have not increased complications in PMMC or Free flap group in our study. Various other studies have similar results however a larger patient pool may be needed to assess them.
- The **PMMC flap is more favorable** for patients with **possibly lethal pre-op morbidities**, when a long operation is not advisable and a small defect is expected as compared to the longer operation duration of ALT free flap & Radial free flap.
- Though the flap related complications & donor site related complications are more with forehead rotational flap as compared to PMMC. ALT & Radial forearm free flap, statistically there is no significant difference. Also in the functional post-op outcomes there is minimally statistically significant difference with PMMC flap, ALT free flap or Radial free flap, local flaps and other reconstructive surgery.

References

- [1] Courtney M. Townsend, B. Mark Evers, R. Daniel Beachamp, Kenneth L. Mattox, SABISTON textbook of surgery The Biological Basis of modern surgical practice 21st edition ;1919-1922
- [2] O.H.Shaheen, Problems in Head and Neck Surgery(1984); 72-86
- [3] Sriram Bhat M, Manual of surgery 6th edition 2021; 320-323
- [4] Cheng MH, Huang JJ. Oral cavity, tongue, and mandibular reconstructions. In: Neligan PC, editor. Plastic surgery. 3rd ed. London: Elsevier Saunder; 2013. p.307-35.
- [5] Lenert JJ, Evans GR. Oral cavity reconstruction In: Mathes SJ, Hentz VR, editors. Plastic surgery: Vol. III head and neck. 2nd ed. Philadelphia, PA: Saunders Elsevier Cop.; p.917-56.
- [6] Hurvitz KA, Kobayashi M, Evans GR. Current options in head and neck reconstruction. *Plast Reconstr Surg* 2006; 118:122e-33e.
- [7] Hsing CY, Wong YK, Wang CP, et al. Comparison between free flap and pectoralis major pedicled flap for reconstruction in oral cavity cancer patients: a quality of life analysis. *Oral Oncol* 2011;47:522-7.
- [8] Chen CH, Lin GT, Fu YC, et al. Comparison of deltopectoralis flap and free radial forearm flap in reconstruction after oral cancer ablation. *Oral Oncol* 2005;41:602-6.
- [9] Ariyan S. The pectoralis major myocutaneous flap: a versatile flap for reconstruction in the head and neck. *Plast Reconstr Surg* 1979;63:73-81.
- [10] Yang GF, Chen PJ, Gao YZ, et al. Forearm free skin flap transplantation: a report of 56 cases. 1981. *Br J Plast Surg* 1997; 50:162-5.
- [11] Bozиков K, Arnez ZM. Factors predicting free flap complications in head and neck reconstruction. *J Plast Reconstr Aesthet Surg* 2006; 59:737-42.