

Utilizing Anterior Segment Optical Coherence Tomography for Comprehensive Analysis of Corneal Disorders

Dr. Manglesh Mohan Gupta¹, Dr. Bhalchandra S. Joshi², Dr. Vijay H. Karambelkar³

¹Resident, Department of Ophthalmology, Krishna Institute of Medical Sciences, Karad, Krishna Vishwa Vidyapeeth "Deemed to Be University", Karad, Maharashtra, India - 415539

Corresponding Author Email ID: [manglesh122\[at\]gmail.com](mailto:manglesh122[at]gmail.com)

Mobile No. +91 - 9503586623

²Associate Professor, Department of Ophthalmology, Krishna Institute of Medical Sciences, Karad, Krishna Vishwa Vidyapeeth "Deemed to Be University", Karad, Maharashtra, India - 415539

³Head of Department, Department of Ophthalmology, Krishna Institute of Medical Sciences, Karad, Krishna Vishwa Vidyapeeth "Deemed to Be University", Karad, Maharashtra, India - 415539

Abstract: Anterior segment optical coherence tomography (AS - OCT) is a form of OCT technology that has been adapted for clinical care and scientific research of ocular surface and anterior segment diseases present study aimed to assess the anterior segment optical coherence tomography in corneal disorders. **Aim:** Study of anterior segment optical coherence tomography in corneal disorders. **Material & method:** This single centre hospital based prospective study, conducted in patients who attended ophthalmology outpatient department and undergoing treatment in our institute over a period of 18 months from November 2020 to May 2022. Patients with corneal disorder willing to be part of study were included and patients not compliant were excluded from the study. Non - invasive, non - contact diagnostic method that uses infrared light to analyse the cornea. The collected data were analysed using SPSS v21 operating on windows 10 with appropriate analytical testing with significance of $p < 0.05$ was considered. **Results:** In present study total of 90 patients fulfilling inclusion criteria were included after obtaining the informed consent. The mean age of patients was 52.09 ± 13.70 yrs of age. Among the study participants, 64.4% were male patients and 35.6% were female patients, with male preponderance. Among the study participants, 52.2% were with right eye involvement, 36.7% with left eye involvement and 11.1% with bilateral involvement. Among the study participants, 26.66% had corneal opacity, 30.00% had corneal infection which showed the maximum distribution among the diseases taken in account. Quantitative analysis of central corneal thickness, oedema thickness and infiltrate thickness were assessed in different corneal pathologies. Corneal hyper - reflectivity is an increase in whiteness, whereas the definition of corneal hypo - reflectivity is an increase in darkness. In case of scars, oedema, fibrosis, or material deposits on the cornea, there may be variable increase in reflectivity. Hyper - reflective band under the corneal epithelium is visible on corneal AS - OCT imaging in patients who have a clinical history of inflammation and corneal thinning. **Conclusion:** Study found a significant findings and utility of quantitative and qualitative analysis of corneal pathology by AS OCT in evaluation and treatment of corneal disorder.

Keywords: Anterior Segment Optical Coherence Tomography, Corneal Disorders, quantitative analysis, qualitative analysis, clinical study

1. Introduction

A non - invasive, non - contact imaging technique called optical coherence tomography (OCT) creates in vivo images of anatomical structures all over the body. Many eye structures, including the cornea, lens, iris, retina, and optic nerve, have been imaged with micro - meter - resolution using OCT imaging. Biological tissues can be imaged using OCT in three dimensions or in cross - section. Signal attenuation frequently limits the depth of penetration, which is achievable with an image resolution of 1 to 15 μm at a depth of 2 to 7 mm. While confocal microscopy has a lower resolution but greater depth penetration than OCT, the latter has a higher resolution but less depth penetration than ultrasound. In order to treat patients and conduct scientific research on diseases of the ocular surface and anterior segment, optical coherence tomography (OCT) of the anterior segment has been developed. AS - OCT has developed into a crucial tool for assessing anterior segment and the cornea. When other methods, such as the slit - lamp bi microscope, cannot provide sufficient details, this technology aids the clinician in seeing corneal pathology

more clearly. For a better understanding of deep corneal pathology, AS - OCT is found to be helpful. AS - OCT is increasingly used as a standard tool. Additionally, this technique is crucial in a number of surgical procedures (refractive surgery, cataract surgery and keratoplasty). The current reported uses of AS - OCT in corneal disorders include:

(1) assessing corneal thickness and corneal flaps; (2) determining the depth of corneal lesions, including dystrophies; (3) determining the specifics of corneal inflammation; (4) evaluating deposits in the cornea; (5) evaluating dry eyes; and (7) diagnosing early - stage surface neoplasia. The way ophthalmologists visualise the anterior segment of the eye has changed since the development of optical coherence tomography (OCT) imaging. It is simple to use because of its capacity to quickly and painlessly obtain dynamic, high - and ultra - high resolution cross - sectional images of the cornea. The use of anterior segment OCT, which offers "optical biopsy" or in vivo imaging of various corneal 2 pathologies, is the main focus of this study, with ability of the clinician to diagnose ailments that

Volume 12 Issue 7, July 2023

www.ijsr.net

Licensed Under Creative Commons Attribution CC BY

are otherwise invisible to traditional methods. Based on the low - coherence interferometry theory, optical coherence tomography (OCT) relies on light backscattering as it travels through various tissue structures. Infrared light is emitted by a light source and is reflected by the material or tissue it passes through. Back - reflected light is found by a sensor, which contrasts it with light from a reference beam. Time - domain OCT, fourier - domain OCT (which is further divided into spectral - domain OCT and swept source OCT), and swept source OCT have all been used in practise for anterior segment imaging. Its capacity to capture cross - sectional, dynamic, high - and ultra - high - resolution images of the cornea enables simple use and early diagnosis in a quick and non - invasive way. The non - contact OCT devices are safe to use. Most operators with varying levels of experience can use the OCT machines, and the images they produce can be easily interpreted by both inexperienced and experienced clinicians. The OCT machines are also cost effective, which makes making a diagnosis and choosing a treatment plan easier.

Inclusion criteria: All patient with corneal disorder attending at OPD of ophthalmology department of Krishna hospital included in the study.

Exclusion criteria: Non - compliant patient.

2. Material and Methods

A hospital based prospective study.

Source of Data:

Patients who visited the outpatient ophthalmology department of a tertiary care facility were the subjects of this study. It ran from November 2022 until May 2022. The institutional ethics committee gave its approval for this work.

Sample size: 90 patients.

3. Result and Discussion

Quantitative analysis:

In present study total of 90 patients fulfilling inclusion criteria were included after obtaining the informed consent. The mean age of patients was 52.09±13.70 yrs of age.

Mean age of the patients

	N	Minimum	Maximum	Mean	SD
Age in yrs	90	16	82	52.09	13.70

Laterality of the involvement

Laterality	Frequency		Percent (%)	
	Right eye	Left eye	Bilateral	Total
	47	33	10	90
	52.2	36.7	11.1	100.0

Among the study participants, 52.2% were with right eye involvement, 36.7% with left eye involvement and 11.1% with bilateral involvement.

Showing distribution of corneal disorder

Disease	Frequency	Percent (%)
Corneal opacity	24	26.66
Keratoconus	3	3.33
Corneal infection	27	30.00
Corneal dystrophies	5	5.55
Corneal degeneration	6	6.66
OSSN	3	3.33
Bullous keratopathy	5	5.00
Corneal surgeries and complication	14	15.55
Trauma	3	3.33
Total	90	100

OCT measurements at presentation of corneal infection

	Corneal thickness (µm)		Infiltrate thickness (µm)	
	Mean	SD	Mean	SD
Bacterial	820.22	185.29	252.8	88.37
Viral	693.25	195.66	219	80.63
Fungal	645.5	274.68	232.8	84.11

Corneal thickness at the time of presentation of bacterial keratitis ranged from 532µm to 1202µm with mean of 820µm. Infiltrate thickness ranged 132µm to 416µm with mean 252.8 µm.

Corneal thickness at the time of presentation of viral keratitis ranged from 395µm to 1003µm with mean of 693.25µm. and infiltrate thickness ranged 120µm to 335µm with mean 219µm.

Over all corneal thickness at the time of presentation of fungal keratitis ranged from 371µm to 1208µm with mean of 645.5µm. and infiltrate thickness ranged 164µm to 380 µm with mean 232.8µm.

OCT measurements on presentation of corneal opacity

Corneal opacity	Mean opacity thickness (µm)	SD
Nebular	96.87	31.5
Macular	244.55	50.83
Leucomatous	522.66	82.92

Opacity thickness at the time of presentation of nebular opacity ranged from 46µm to 138 µm with mean of 96.87µm.

Opacity thickness at the time of presentation of macular opacity ranged from 168µm to 310 µm with mean of 244.55µm.

Opacity thickness at the time of presentation of leucomatous opacity ranged from 400µm to 660 µm with mean of 522.66µm.

OCT measurement at presentation of Pseudophakic Bullous Keratopathy

Mean corneal thickness (µm)	SD	Mean epithelial thickness (µm)	SD	Mean stromal Thickness (µm)	SD
800.2	39.12	72	4.60	701.8	54.47

Overall corneal thickness at the time of presentation of pseudophakic bullous keratopathy ranged from 755µm to 870 µm with mean of 800.2 µm.

Epithelial thickness ranging from 66µm to 80µm with mean thickness of 72µm.

Stromal oedema thickness at the time of presentation ranged 616 µm to 715µm with mean of 701.8µm.

Qualitative analysis Corneal infections:

In this investigation, corneal invasion showed signs of being highly reflecting. Signals that are black indicate hyporeflectivity. Scarring and stromal infiltration both seem to reflect light more strongly. In the stroma, stromal cystic spaces resemble hypo reflective cavities. With an epithelium deficiency, infiltration is ill - defined. Stromal scarring exhibits strongly delineated borders and an intact epithelium. Areas of reduced reflectivity emerge diffusely in stromal oedema. An unusual finding on the AS - OCT in viral keratitis was microcystic oedema. The epithelium and/or anterior stroma were its only known locations. An inflammatory plaque connected to the corneal endothelium, clinically recognised as keratitic precipitates, seen as hyperreflective aggregation of inflammatory cells in AS - OCT imaging.

Corneal opacity:

Hyperreflective scarring was seen in different layers of cornea in corneal opacity

Within 160 microns of the stroma, there was hyperreflectivity with intact epithelium, as well as stromal thinning in Nebular opacity. In macular opacity, hyperreflectivity was seen in the anterior 2/3 of the stroma up to 330 microns with intact epithelium and stromal thinning.

Hyperreflectivity was seen in the entire stroma in leucomatous opacity, with intact epithelium and stromal thinning. Hyperreflective stroma with absent declinations and endothelium were seen in adherent leucoma along with absent anterior chamber depth and there is in contact with the cornea were seen posteriorly.

In corneal dystrophies and corneal degeneration

Multiple cystic formations were visible on AS - OCT pictures showing gelatinous drop - like corneal dystrophy in bowman's layer and the superficial corneal stroma.

A lattice - like structure in the anterior stroma and epithelium, as well as superficial thick hyperreflective deposits, were visible on the OCT picture of granular corneal dystrophy.

AS - OCT in macular corneal degeneration caused scattered, hyperreflective tiny patches to appear across the corneal stroma and enhanced hyperreflectivity between the stroma.

Ocular surface squamous neoplasia

In this investigation, AS - OCT imaging of the OSSN revealed hyperreflective, thickened epithelium that was irregularly shaped. The epithelium showed a defect. The transition of the cornea's uneven design to its typical contour was visible posterior to epithelium, rest of corneal layer could not be seen.

Keratoconus

AS - OCT of keratoconus shows increased epithelium thickness and hyperreflective epithelium. Annular thinning of stroma is seen with overall decreased corneal thickness.

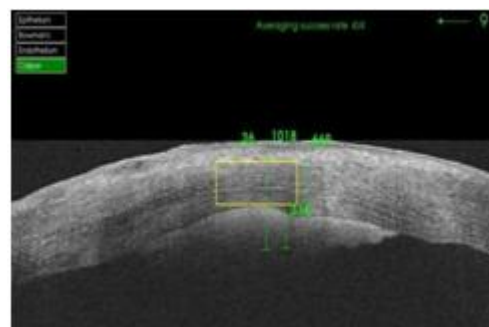Corneal surgeries and complications:

A post - keratoplasty picture revealed a hyporeflective stromal layer that suggested stromal oedema and a hyper reflective demarcation line of graft tissue. The suture site had a hyper reflective appearance.

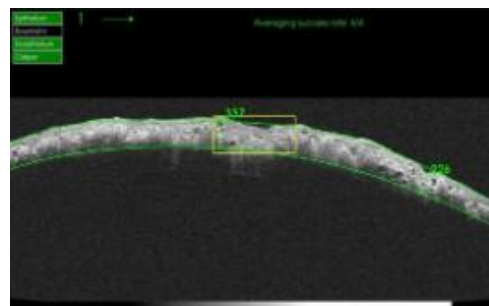
AS - OCT of post RK hydrops had shown increased corneal thickness, hyperreflective scarred stroma, large intrastromal cystic space and descmet's membrane detachment.

Trauma:

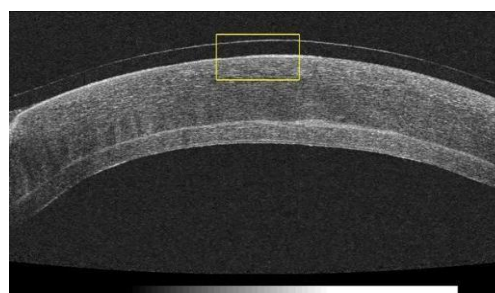
AS - OCT image of corneal trauma showed hyperreflective epithelium with epithelial defect. Impacted foreign body was seen as hyperreflective structure. Hyporeflective areas were seen posterior to the impacted foreign body. Increased stromal thickening and stromal hyporeflectivity was seen. AS - OCT of post trauma image had shown hyperreflective scared epithelium continuing till endothelium, depicting a healed tear.



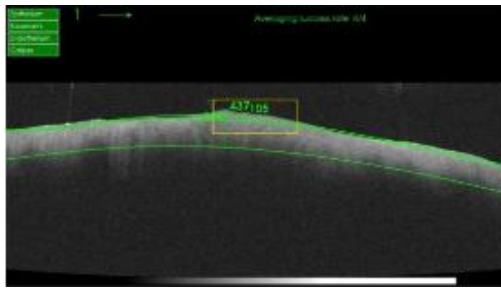
ASOCT image showing Central Corneal Thickness, epithelial thickness, stromal thickness and qualitative changes of microbial keratitis.



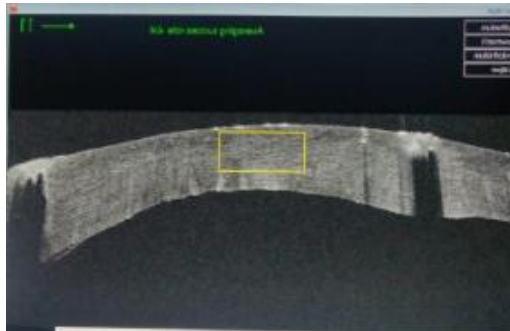
Spheroidal degeneration / Gelatinous drop like dystrophy show cystic structures in Bowman's



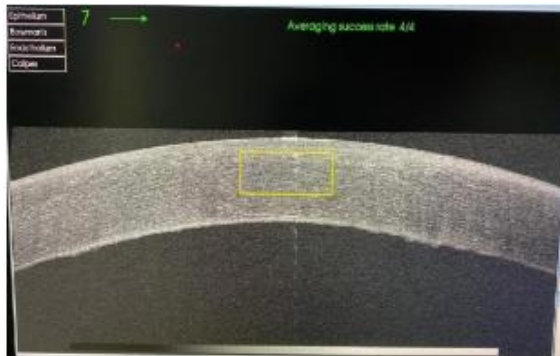
Deep Anterior Lamellar Keratoplasty



OSSN



ASOCT image of Blast Injury



ASOCT image of PBK

References

- [1] SridharMA, MartinR. Anterior segment optical coherence tomography for evaluation of cornea and ocular surface. *Indianjophthalmol*.2018; 66 (3): 1–5.
- [2] Konstantopoulos A, Kuo J, Anderson D, Hossain P. Assessment of the use of anterior segment optical coherence tomography in microbial keratitis. *Am j ophthalmol*.2008; 146 (4): 534 - 542. e2.
- [3] Lim SH. Clinical applications of anterior segment optical coherence tomography. *Jophthalmol*.2015; 2015: 605729.
- [4] Radhakrishnan S, Patel AS, Aref AA, Moore DB, Akkara JD, DelmonteDW. Anterior segment optical coherence tomography. *Amacadophthalmol*.2022; 1–7.
- [5] Venkateswaranel. *EyeandVision* (2018) 5: 13https://doi.org/10.1186/s40662-018-0107-0
- [6] AbdelghanyAA, D’oriaF, AlioDelBarrioJ, AlioJL. The value of anterior segment optical coherence tomography in different types of corneal infections: an update. *Jclin med*.2021; 10 (13): 2841–5.
- [7] GuptaN, VarshneyA, Ramappa M, Basu S, Romano V, Acharya M, Gaur A, Kapur N, Singh A, Shah G, Chaudhary I, Patel N, Tiwari A, Kate A, Sangwan V, Mathur U. Role of AS - OCT in Managing Corneal Disorders. *Diagnostics*.2022; 12 (4): 918. Doi.org/10.3390/diagnostics12040918
- [8] Agarwal A, Narang P, Kumar DA, Agarwal A. Young donor - graft assisted endothelial keratoplasty (PDEK/DMEK) with epithelial debridement for chronic pseudophakic bullous keratopathy. *Canadian Journal of Ophthalmology*.2017; 52: 519 - 526. DOI: 10.1016/j.jcjo.2017.03.004.

4. Conclusion

Study found significant findings and utility of the anterior segment optical coherence tomography in corneal disorders. This study involved both quantitative and qualitative analysis of corneal disorder which gives information about architectural changes of cornea in different pathologies and certain histological patterns seen can be used as an adjunctive method for making diagnosis. Changes in the corneal architecture can be used to take an early decision in deciding the treatment. Serial scans can help in evaluating response to treatment. It is a non - contact instrument, improves patient compliance for follow - up. Allows real assets in practice of evidence - based medicine and can be of a valuable proof in medico - legal cases. It has image data which can be helpful for academics and research purpose.

Ethical approval: The Institutional and/or National Ethics Committee's ethical standards were met in all human participant procedures.

Source of funding: Krishna Vishwa Vidyapeeth, Karad.

Conflict of interest: No.