

Comparative Study of Unilateral Pedicle Screw Fixation versus Bilateral Pedicle Screw Fixation for Degenerative Disease in Lumbar Spine

Dr. Omprakash Kumar¹, Dr. Sunny Kumar², Dr. Abhimanyu Kumar³, Dr. Rohit Raj⁴

Abstract: Background: To compare unilateral pedicle screw fixation is better than bilateral pedicle screw fixation. Objectives: To compare Unilateral pedicle screw fixation is better than bilateral pedicle screw fixation in case of degenerative lumbar spine diseases. Methods: The clinical and radiographic outcomes were compared between the UPSF and BPSF group. The postoperative improvements were evaluated in either group. Intraoperative data such as duration of operation and estimated blood loss were compared. Results: A total of 20 cases were included in this study. The current best evidence detected shows no significant differences between unilateral and bilateral PSF for short segment lumbar fusion in the functional scores, length of hospital stay, fusion rate, and complication rate. . In all studied patients, 18 months after surgery, completed posterior spinal fusion was detected and recorded on a control CT, which was rated by Glassman. The average follow - up period was 15.2 ± 3.7 months, and the average age of patients was 57.2 ± 17.1 years. Both groups were comparable in age, gender (male to female ratio 17: 23 [1st group] and 19: 21 [2nd group]) ($p > 0.05$), and the operated segments L4 - L5: 34 patients (Group 1) and 35 patients (Group 2); and L5 - S1: However, unilateral PSF involved a remarkable decrease in operative time and blood loss. Conclusions: According to this systematic review, unilateral PSF is an effective method of fixation for short - segment lumbar fusion, has the advantages of reduced operative time and blood loss over bilateral PSF.

Keywords: Degenerative spine disease, unilateral pedicle screw fixation vs bilateral pedicle screw fixation, lumbar spine surgical treatment, spondylitis with surgical treatment, surgical pedicular screw fixation vs/with surgical fusion of spine with pedicular screw fixation

1. Introduction

Lumbar spinal fusion is recognized as an effective surgical procedure for degenerative lumbar diseases [1]. Lumbar fusion can achieve solid arthrodesis, immobilizing the unstable segment and degenerated inter vertebral disc area [2]. Bilateral pedicle screw fixation after inter - body fusion is regarded as a standard surgical method for degenerative lumbar diseases. However, rigid fixation also has corresponding short - comings. Rigid internal fixation may accelerate the degeneration of adjacent lumbar segments and cause device - related osteoporosis. Moreover, bilateral pedicle screw fixation was associated with greater blood loss, longer operative time, and involving greater costs [3]. However unilateral pedicle screw fixation escapes rigid fixation allowing partial movement on other side in involved segment. Thus rapid degeneration is less as compared to bilateral fixation

In 1991, Goel et al. [4] revealed that unilateral pedicle screw fixation could reduce the effects of stress shielding on the fixed vertebrae and avoid adjacent inter vertebral disc degeneration. Moreover, some scholars reported that unilateral pedicle screw fixation is sufficient to maintain the stability of the spine. A previous biomechanical study revealed that the initial stability of unilateral pedicle screw fixation may be inadequate to obtain improved surgical outcomes.

Lumbar fusion is an effective procedure commonly performed for treating lumbar degenerative disc diseases [1]. usually, bilateral pedicle screw fixation (PSF) is a standard for lumbar fusion. However, the pronounced stiffness of bilateral PSF appears to cause undesired adverse effects such as reduced fusion rate, adjacent segment degeneration, and

loss of bone mineral content [2, 3]. In response to those concerns, unilateral PSF, which involves less rigidity, has been developed for lumbar fusion.

Biomechanical studies have demonstrated that unilateral PSF is able to maintain the initial stability after lumbar fusion, and decrease the influence of stress - shielding imposed on the fixed level and levels adjacent to the fusion [4, 5]. In addition, numerous clinical studies have suggested that unilateral PSF is as effective as bilateral PSF for lumbar fusion but has the advantages of reduced operation time, blood loss, and implant cost [6–14]. A 5 - year follow - up study by Toyone et al. [15] also found a lower occurrence of adjacent segment degeneration in patients undergoing unilateral PSF than that in patients who underwent bilateral PSF.

Reversely, there exist studies indicating that unilateral PSF provided less stability than bilateral PSF for lumbar fusion [16–20]. Due to its inherent asymmetry and reduced strength, unilateral PSF was reported to cause postoperative back pain, implant failure, more cage migration, and a relatively lower fusion rate when compared with bilateral PSF [8, 21–23].

Recently, multiple meta- analyses have carried out a comparison of unilateral and bilateral PSF in lumbar fusion. However, those overlapping meta- analyses showed discordant results as well.

Several studies suggested that unilateral and bilateral PSF were equally safe and effective for lumbar fusion [24–28]. However, the results of other studies indicated that unilateral PSF lead to more cage migration or a relatively lower fusion rate than bilateral PSF [29–33]. As a result, the above

conflicting findings may bring uncertainty about which method of fixation is better for lumbar fusion.

The objectives of this study were to carry out a systematic review on the basis of overlapping meta - analyses regarding unilateral versus bilateral PSF in lumbar fusion to provide recommendations of treatment on this topic according to the current best evidence, and to identify potential limitations within current literature that require future research.

2. Materials and methods

This study was conducted on the patients admitted through orthopaedics OPD between august 2021 to march 2023.

Inclusion criteria

- 1) Age below 70yrs
- 2) Single level instability
- 3) Active person with radiculopathy
- 4) No bowel and bladder involvement

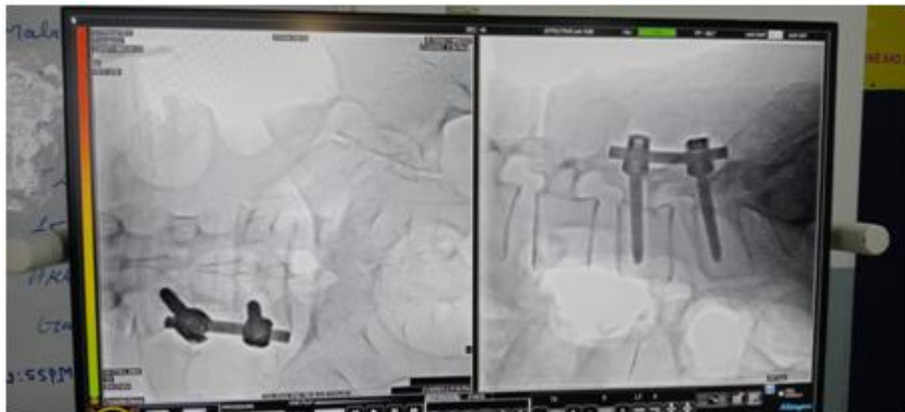Exclusion criteria

- 1) No any spine deformity
- 2) No severe comorbidity

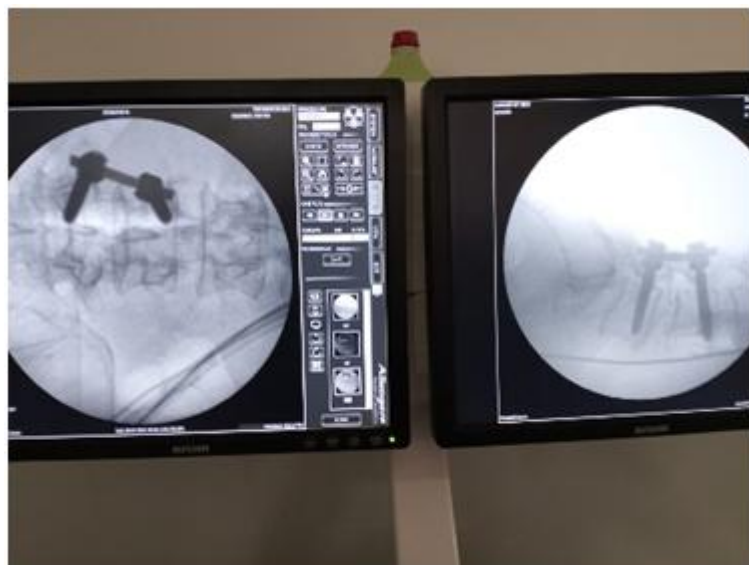- 3) Below age 55years
- 4) Multilevel instability
- 5) Paraparesis with bowel and bladder involvement
- 6) Paraparesis

The patient were admitted in the ward after thorough investigations

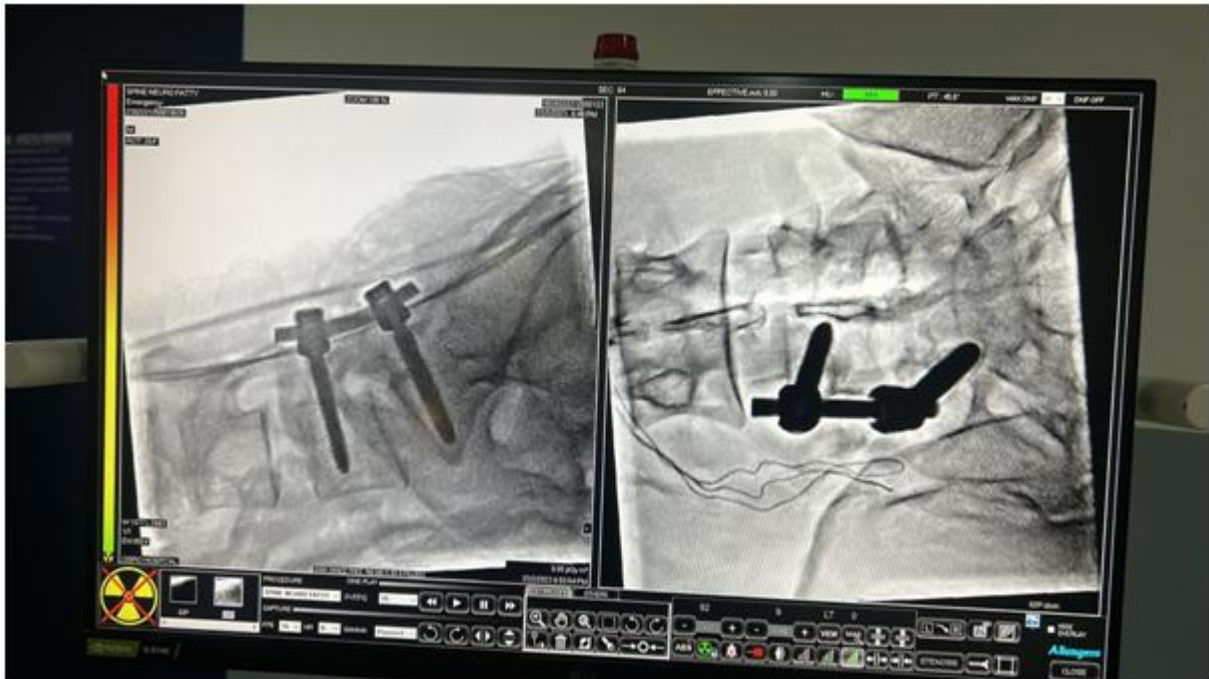MRI, routine blood investigations, xray chest pa view, LFT, KFT, CT, BT, PT - INR. They were posted for the routine OT. All patients were taken under general Anaesthesia. patients were positioned prone. After proper scrubbing patient were properly prepped and draped. Midline skin incision given after marking the location under c arm guidance of around 8 cm. soft tissues erased subperiosteally in one side in unilateral pedicle screw fixation whereas both sides in bilateral pedicles screw fixation. Right or left sides were decided on the basis of more instability and compression as well. Hemostasis was secured with the help of cautery. Pedicle screw was applied with the help of c arm guidance and fixation was done along with decompression by laminectomy. Proper washing was done with normal saline wound closed in layers.



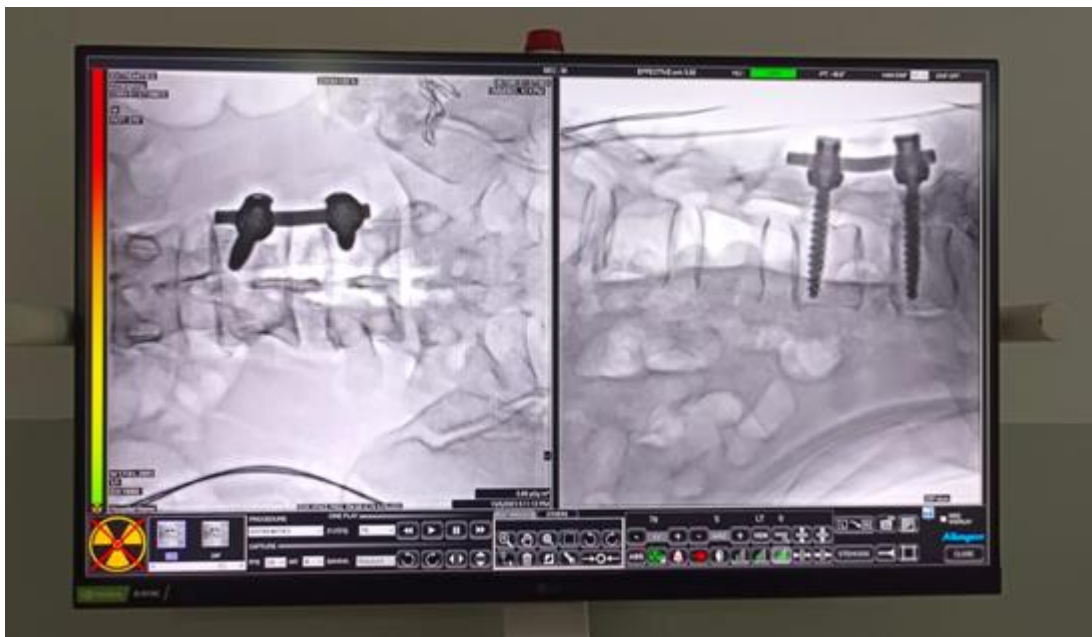Case 1: Mala Devi 65 years female



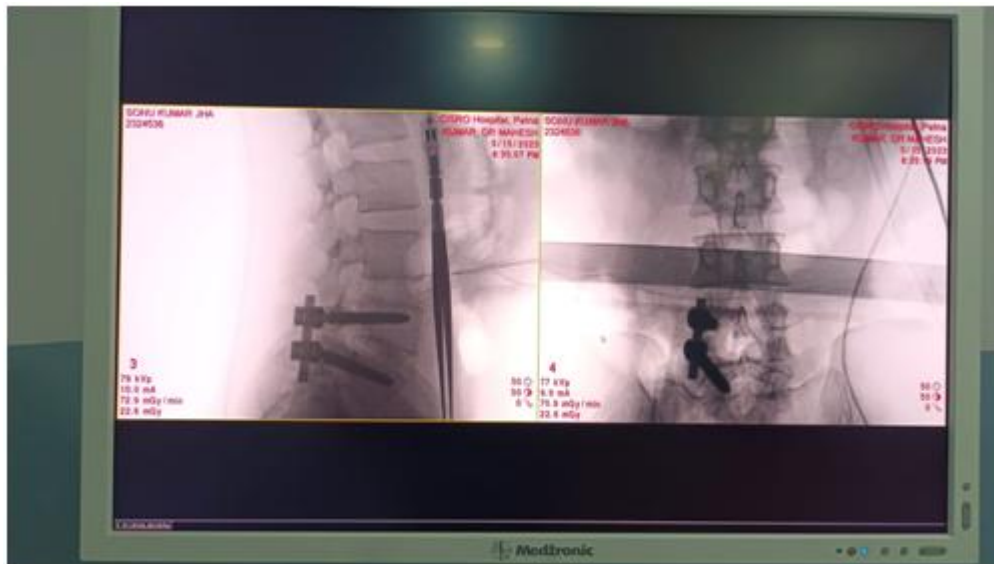Case 2: Urmila devi



Case 3: Dilip Kumar 64 years male



Case 4: Geeta devi



Case 5: Mala Devi

3. Results

Based on the results of the pre - operative examinations, all patients were diagnosed with single level instability in the spinal motion segment of the lumbosacral spine. In all studied patients, 18 months after surgery, completed posterior spinal fusion was detected and recorded on a control CT, which was rated by Glassman. The average follow - up period was 15.2 ± 3.7 months, and the average age of patients was 57.2 ± 17.1 years. Both groups were comparable in age, gender (male to female ratio 17: 23 [1st group] and 19: 21 [2nd group]) ($p > 0.05$), and the operated

segments L4 - L5: 34 patients (Group 1) and 35 patients (Group 2); and L5 - S1:

Table A: Intraoperative Time

UPSF	BPSF
Geeta Devi - 45 min	Ram Lakhan Mahto – 110 min
Urmila Devi - 40 min	yogeshwar Yadav – 125 min
Dilip Kumar – 50 min	Md. Yusuf – 130 min
Mala Devi – 50 min	Rohit Nathany – 115 min
Rajesh Kumar – 45 min	Md. Shareeb – 105 min

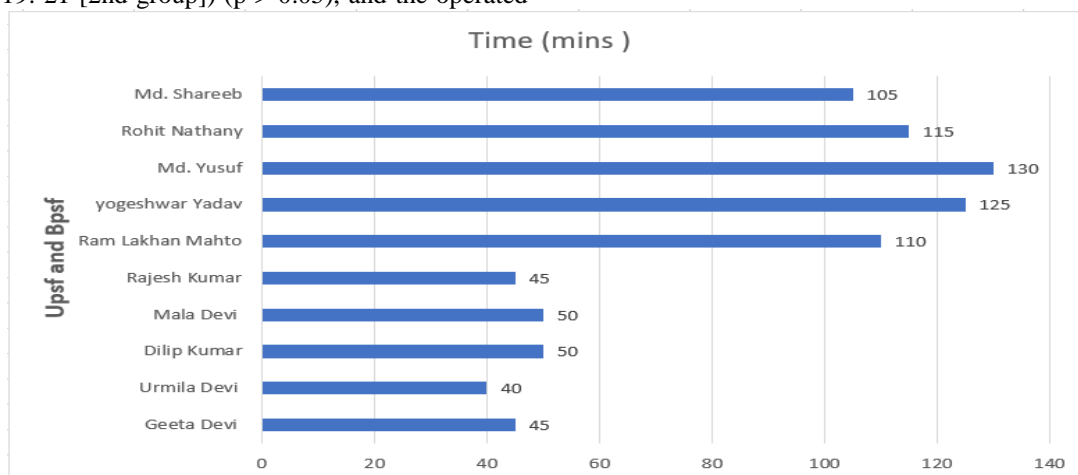


Table B: Blood loss

UPSF	BPSF
Geeta Devi – 40 ml	Ram Lakhan Mahto – 120 ml
Urmila Devi – 45 ml	yogeshwar Yadav – 130 ml
Dilip Kumar – 40 ml	Md. Yusuf – 140 ml
Mala Devi – 50 ml	Rohit Nathany – 150 ml
Rajesh Kumar – 55 ml	Md. Shareeb – 160 ml

segment; however, it should be noted that there were no differences in the rate of fusion formation, the risk of revision intervention or post - operative complications in comparison with bilateral pedicle screw fixation [23]. Moreover, most of the available works describe the use of unilateral transpedicular fixation exclusively in the surgical treatment of one - or two - level degenerative diseases of the lumbar spine [5], [24]. Some studies have shown that unilateral pedicle screw fixation significantly reduces surgery time and blood loss compared to bilateral pedicle screw fixation during decompression and stabilization operations on the lumbar spine, and less trauma associated with surgical access performed on one side was noted [25], [26], [27]. Our study and the results obtained allowed us to show the absence of significant differences in the clinical and functional results of both types of surgical treatment, as well as to confirm the available data on the low volume of intraoperative blood loss and the shorter duration of the operation. It is useful to extend the follow - up period and continue further trials on the use of unilateral pedicle screw fixation in the treatment of lumbar spine instability.

5. Conclusions

Unilateral and bilateral pedicle screw fixation showed similar clinical and functional results. However, the timing of surgical treatment, the number of implants used and intraoperative blood loss are lower in the unilateral fixation group, which indicates that the use of unilateral fixation can be the choice of performing posterior stabilization in case of a single - level instability of the spine without using an interbody implant.

Loss, but it increases the risk of interbody cage migration. Based on the above findings, the researchers concluded that unilateral fixation is recommended as the optimal fixation method in the formation of lumbar fusion. Nevertheless, according to some studies, unilateral fixation causes adverse effects due to the asymmetry of the spine and reduced stability of the operated segment; however, it should be noted that there were no differences in the rate of fusion formation, the risk of revision intervention or post - operative complications in comparison with bilateral pedicle screw fixation [23]. Moreover, most of the available works describe the use of unilateral transpedicular fixation exclusively in the surgical treatment of one - or two - level degenerative diseases of the lumbar spine [5], [24]. Some studies have shown that unilateral pedicle screw fixation significantly reduces surgery time and blood loss compared to bilateral pedicle screw fixation during decompression and stabilization operations on the lumbar spine, and less trauma associated with surgical access performed on one side was noted [25], [26], [27]. Our study and the results obtained allowed us to show the absence of significant differences in the clinical and functional results of both types of surgical treatment, as well as to confirm the available data on the low volume of intraoperative blood loss and the shorter duration of the operation. It is useful to extend the follow - up period and continue further trials on the use of unilateral pedicle screw fixation in the treatment of lumbar spine instability.

Unilateral and bilateral pedicle screw fixation showed similar clinical and functional results. However, the timing

of surgical treatment, the number of implants used, as well as intraoperative blood loss are lower in the unilateral fixation group, which indicates that the use of unilateral fixation can be the choice of performing posterior stabilization in case of a single - level instability of the spine without using an interbody implant.

References

- [1] Deyo RA, Nachemson A, Mirza SK. Spinal - fusion surgery—the case for restraint. *N Engl J Med.*2004; 350 (7): 722–6. pmid: 14960750 View ArticlePubMed/NCBIGoogle Scholar
- [2] McAfee PC, Farey ID, Sutterlin CE, Gurr KR, Warden KE, Cunningham BW.1989 Volvo Award in basic science. Device - related osteoporosis with spinal instrumentation. *Spine (Phila Pa 1976).*1989; 14 (9): 919–26. View ArticleGoogle Scholar
- [3] Lee CS, Hwang CJ, Lee SW, Ahn YJ, Kim YT, Lee DH, et al. Risk factors for adjacent segment disease after lumbar fusion. *Eur Spine J.*2009; 18 (11): 1637–43. pmid: 19533182 View ArticlePubMed/NCBIGoogle Scholar
- [4] Goel VK, Lim TH, Gwon J, Chen JY, Winterbottom JM, Park JB, et al. Effects of rigidity of an internal fixation device. A comprehensive biomechanical investigation. *Spine (Phila Pa 1976).*1991; 16 (3 Suppl): S155–61. View ArticleGoogle Scholar
- [5] Chen HH, Cheung HH, Wang WK, Li A, Li KC. Biomechanical analysis of unilateral fixation with interbody cages. *Spine (Phila Pa 1976).*2005; 30 (4): E92–6. View ArticleGoogle Scholar
- [6] Lin B, Lin QY, He MC, Liu H, Guo ZM, Lin KS. Clinical study on unilateral pedicle screw fixation and interbody fusion for the treatment of lumbar degenerative diseases under Quadrant system. *Zhongguo Gu Shang.*2012; 25 (6): 468–73. pmid: 23016381View ArticlePubMed/NCBIGoogle Scholar
- [7] Xie Y, Ma H, Li H, Ding W, Zhao C, Zhang P, et al. Comparative study of unilateral and bilateral pedicle screw fixation in posterior lumbar interbody fusion. *Orthopedics.*2012; 35 (10): e1517–23. pmid: 23027490 View ArticlePubMed/NCBIGoogle Scholar
- [8] Xue H, Tu Y, Cai M. Comparison of unilateral versus bilateral instrumented transforaminal lumbar interbody fusion in degenerative lumbar diseases. *Spine J.*2012; 12 (3): 209–15. pmid: 22381573 View ArticlePubMed/NCBIGoogle Scholar
- [9] Dahdaleh NS, Nixon AT, Lawton CD, Wong AP, Smith ZA, Fessler RG. Outcome following unilateral versus bilateral instrumentation in patients undergoing minimally invasive transforaminal lumbar interbody fusion: a single - center randomized prospective study. *Neurosurg Focus.*2013; 35 (2): E13. pmid: 23905951 View ArticlePubMed/NCBIGoogle Scholar
- [10] Lin B, Xu Y, He Y, Zhang B, Lin Q, He M. Minimally invasive unilateral pedicle screw fixation and lumbar interbody fusion for the treatment of lumbar degenerative disease. *Orthopedics.*2013; 36 (8): e1071–6. pmid: 23937756 View ArticlePubMed/NCBIGoogle Scholar
- [11] Zhang K, Sun W, Zhao CQ, Li H, Ding W, Xie YZ, et al. Unilateral versus bilateral instrumented

- transforaminal lumbar interbody fusion in two - level degenerative lumbar disorders: a prospective randomised study. *Int Orthop*.2014; 38 (1): 111–6. pmid: 23917853 View ArticlePubMed/NCBIGoogle Scholar
- [12] Shen X, Zhang H, Gu X, Gu G, Zhou X, He S. Unilateral versus bilateral pedicle screw instrumentation for single - level minimally invasive transforaminal lumbar interbody fusion. *J Clin Neurosci*.2014; 21 (9): 1612–6. pmid: 24814852 View ArticlePubMed/NCBIGoogle Scholar
- [13] Dong J, Rong L, Feng F, Liu B, Xu Y, Wang Q, et al. Unilateral pedicle screw fixation through a tubular retractor via the Wiltse approach compared with conventional bilateral pedicle screw fixation for single - segment degenerative lumbar instability: a prospective randomized study. *J Neurosurg Spine*.2014; 20 (1): 53–9. pmid: 24236667 View ArticlePubMed/NCBIGoogle Scholar
- [14] Gu G, Zhang H, Fan G, He S, Meng X, Gu X, et al. Clinical and radiological outcomes of unilateral versus bilateral instrumentation in two - level degenerative lumbar diseases. *Eur Spine J*.2015; 24 (8): 1640–8. pmid: 26002354 View ArticlePubMed/NCBIGoogle Scholar
- [15] Toyone T, Ozawa T, Kamikawa K, Watanabe A, Matsuki K, Yamashita T, et al. Subsequent vertebral fractures following spinal fusion surgery for degenerative lumbar disease: a mean ten - year follow - up. *Spine (Phila Pa 1976)*.2010; 35 (21): 1915–8. View ArticleGoogle Scholar
- [16] Harris BM, Hilibrand AS, Savas PE, Pellegrino A, Vaccaro AR, Siegler S, et al. Transforaminal lumbar interbody fusion: the effect of various instrumentation techniques on the flexibility of the lumbar spine. *Spine (Phila Pa 1976)*.2004; 29 (4): E65–70. View ArticleGoogle Scholar
- [17] Slucky AV, Brodke DS, Bachus KN, Droge JA, Braun JT. Less invasive posterior fixation method following transforaminal lumbar interbody fusion: a biomechanical analysis. *Spine J*.2006; 6 (1): 78–85. pmid: 16413452 View ArticlePubMed/NCBIGoogle Scholar
- [18] Yucesoy K, Yuksel KZ, Baek S, Sonntag VK, Crawford NR. Biomechanics of unilateral compared with bilateral lumbar pedicle screw fixation for stabilization of unilateral vertebral disease. *J Neurosurg Spine*.2008; 8 (1): 44–51. pmid: 18173346 View ArticlePubMed/NCBIGoogle Scholar
- [19] Sethi A, Muzumdar AM, Ingalhalikar A, Vaidya R. Biomechanical analysis of a novel posterior construct in a transforaminal lumbar interbody fusion model an in vitro study. *Spine J*.2011; 11 (9): 863–9. pmid: 21802998 View ArticlePubMed/NCBIGoogle Scholar
- [20] Chen SH, Lin SC, Tsai WC, Wang CW, Chao SH. Biomechanical comparison of unilateral and bilateral pedicle screws fixation for transforaminal lumbar interbody fusion after decompressive surgery—a finite element analysis. *BMC MusculoskeletDisord*.2012; 13: 72. pmid: 22591664 View ArticlePubMed/NCBIGoogle Scholar
- [21] Aoki Y, Yamagata M, Ikeda Y, Nakajima F, Ohtori S, Nakagawa K, et al. A prospective randomized controlled study comparing transforaminal lumbar interbody fusion techniques for degenerative spondylolisthesis: unilateral pedicle screw and 1 cage versus bilateral pedicle screws and 2 cages. *J Neurosurg Spine*.2012; 17 (2): 153–9. pmid: 22702892 View ArticlePubMed/NCBIGoogle Scholar
- [22] Mao L, Chen GD, Xu XM, Guo Z, Yang HL. Comparison of lumbar interbody fusion performed with unilateral or bilateral pedicle screw. *Orthopedics*.2013; 36 (4): e489–93. pmid: 23590791 View ArticlePubMed/NCBIGoogle Scholar
- [23] Duncan JW, Bailey RA. An analysis of fusion cage migration in unilateral and bilateral fixation with transforaminal lumbar interbody fusion. *Eur Spine J*.2013; 22 (2): 439–45. pmid: 22878377 View ArticlePubMed/NCBIGoogle Scholar
- [24] Luo J, Gong M, Gao M, Huang S, Yu T, Zou X. Both unilateral and bilateral pedicle screw fixation are effective for lumbar spinal fusion - A meta - analysis - based systematic review. *Journal of OrthopaedicTranslationJ. Orthop. Transl*.2014; 2 (2): 66–74. View ArticleGoogle Scholar
- [25] Liu Z, Fei Q, Wang B, Lv P, Chi C, Yang Y, et al. A meta - analysis of unilateral versus bilateral pedicle screw fixation in minimally invasive lumbar interbody fusion. *PLoS One*.2014; 9 (11): e111979. pmid: 25375315 View ArticlePubMed/NCBIGoogle Scholar
- [26] Phan K, Leung V, Scherman DB, Tan AR, Rao PJ, Mobbs RJ. Bilateral versus unilateral instrumentation in spinal surgery: Systematic review and trial sequential analysis of prospective studies. *J Clin Neurosci*.2016; 30: 15–23. pmid: 27068653View ArticlePubMed/NCBIGoogle Scholar