

Role of Diagnostic Hysteroscopy in Evaluation of Female Infertility

Dr Anusha Nanduri¹, Dr Keshav G², Dr Himaja V³, Dr Vishali P⁴

¹Post Graduate, Department of OBG, PESIMSR, Kuppam Chittoor, Andhra Pradesh – 517425, India (Corresponding Author)

²Professor, Department of OBG, PESIMSR, Kuppam Chittoor, Andhra Pradesh - 517425, India

³Assistant Professor, Department of OBG, PESIMSR, Kuppam Chittoor, Andhra Pradesh - 517425, India

⁴Assistant Professor, Department of OBG, PESIMSR, Kuppam Chittoor, Andhra Pradesh - 517425, India

Abstract: ***Background:** Infertility is a major problem throughout the world. The causes can be multi - factorial, nowadays many couples are seeking medical help for infertility. Diagnostic hystero laparoscopy plays an important role as part of the female infertility workup. **Materials and Methods:** A retrospective study was done in the Department of Obstetrics and Gynecology of a rural tertiary care hospital, Kuppam, India. All patients who underwent Diagnostic hystero laparoscopy as part of infertility workup between June 2021 and December 2022 in the Department Obstetrics and Gynecology were included in the study. **Results:** A total of 80 patients were included in the study. Out of 80 DHL cases 40% were normal and the remaining 60% cases were abnormal. Tubal abnormalities were most common constituting 22.5% of total cases. Uterine abnormalities were about 12.5% **Conclusion:** DHL is a very useful diagnostic tool in evaluating female infertility occurring due to structural abnormalities of uterus and fallopian tubes, there by aiding in patients infertility management.*

Keywords: Hysteroscopy, Laparoscopy, Infertility

1. Introduction

In India approximately 15 - 20% of couples are affected by infertility¹.

Infertility is defined as the failure of a couple to conceive after 1 year of unprotected sexual intercourse in women <35 years of age, and after 6 months of unprotected sexual intercourse in women >35 years of age.

Primary infertility is the inability to conceive in a couple who had no prior pregnancies.

Secondary infertility is the inability to conceive in a couple who has had at least one prior conception, which may have ended in a live birth, still birth, miscarriage, induced abortion or ectopic pregnancy.

Male factor infertility constitutes 45 % and female factors constitute the rest 55% cases, out of which ovulation disorders (37 %) and tubal factors were (18 %) ². A combination of several factors is found in approximately 20 % of all couples.

For normal human fertility, morphology of the uterus has to be normal and patent fallopian tubes are needed. The gold standard for diagnosis of tubal and peritoneal diseases is laparoscopy. Compared to hysterosalpingography and ultrasonography, it has the advantage of direct visualization of the pelvic organs and the peri tubal state, which provides more information.^{3,4}

It is well recognized that hysteroscopy is particularly effective at identifying, uterine, and tubal causes of female infertility⁵.

In the same sitting issues of tubal morphology and patency, ovarian morphology, suspected pelvic disease, anomalies of the uterine cavity and also therapeutic procedures can be done.

Hence, hysteroscopy is efficient in examination and to simultaneously diagnose and treat pelvic pathologies leading to infertility⁶.

2. Materials and Methods

Study design: Retrospective study.

Study location: Department of Obstetrics and Gynecology, PES Institute of Medical sciences and research, Kuppam.

Study duration: June 2021 to December 2022.

Sample size: 80 patients.

Inclusion criteria: Patients with Infertility as the chief complaint.

Exclusion criteria: Active pelvic inflammatory disease. Medical disorders which are contraindicated for Anaesthesia.

Procedure:

The present study was retrospective study conducted from June 2021 to December 2022 with infertility being the chief complaint.

Male factors for infertility were ruled out.

Ultrasound and basic investigations were done.

All the patients were kept nil orally after 10 pm the day before surgery.

After taking written and informed consent, Laparoscopy was performed during the post - menstrual phase on 7th, 8th and 9th day of cycle under regional/ general anesthesia.

Patient positioning: The patient is placed in lithotomy position with head end of the patient. Slightly lowered (Trendelenburg 15 - 30°).

The hysteroscope was introduced into the cervical canal under vision. The uterine cavity was distended with 0.9% normal saline and examined.

Creation of pneumoperitoneum: Veeres needle is introduced through supra umbilical port and abdominal cavity is distended with gas (CO₂ is commonly used).

Trocar and cannula were inserted via the supra umbilical port.

Introduction of laparoscope: Laparoscope connected to the light source, and camera unit is introduced via the port; the findings are noted and visualized on the monitor.

Creation of accessory port: Accessory port was created for operative procedures. Pelvic organs were examined and then whole peritoneal cavity was examined. After the procedure, patient was transferred to postoperative ward and was discharged next day.

Statistical analysis:

The data was entered into MS excel 2007 version and analyzed using SPSS version 21.

3. Results

Table 1: Age Distribution among the Study Population

Age (in years)	Primary Infertility		Secondary Infertility	
	Number	Percentage (%)	Number	Percentage (%)
<20	2	2.5	—	—
21 - 25	25	31.25	—	—
26 - 30	20	25	8	10
31 - 35	12	15	4	5
>36	6	7.5	3	3.75

The study included 80 patients. 65 cases were of primary infertility and the remaining 15 cases were of secondary infertility. Majority of primary infertile cases were in the age group of 21 - 25 years (31.25%) and that of secondary infertile cases were in the age group of 26 - 30 years (10%).

Table 2: Types of Infertility in the Study Population

Types	Number	Percentage
Primary	65	81.25
Secondary	15	18.75
Total	80	100

Among the study population, majority cases were of primary infertility (81.25%) and the remaining cases were of secondary infertility (18.75%).

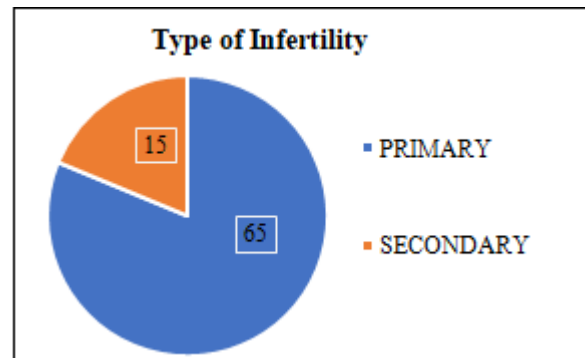


Figure 1: Types of Infertility in the Study Population

Table 3: Causes of Infertility among the study participants

Causes of Infertility	Number	Percentage
Ovarian Factor	12	15
Tubal Factor	18	22.5
Uterine Factor	10	12.5
Pelvic Pathology	8	10

Among the study participants 32 (40%) had normal Hystero - laparoscopic findings. Among the causes leading to infertility, majority cases had Tubal pathology (22.5%), followed by ovarian (15%) and uterine causes (12.5%) and least being pelvic pathology (10%).

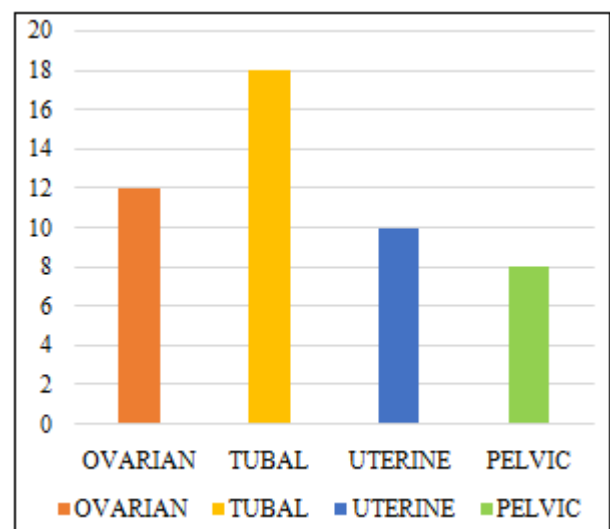


Figure 2: Causes of Infertility among the Study Participants

Table 4: Hystero Laparoscopic Findings

Findings	Primary Infertility		Secondary Infertility		Total	
	(n= 65)	%	(n=15)	%	(n=80)	%
Normal	24	30	8	10	32	40
Poly Cystic Ovaries	6	7.5	2	2.5	8	10
Simple Ovarian Cyst	4	5	-	-	4	5
Uterine Anomaly	5	6.25	1	1.25	6	7.5
Fibroid Uterus	4	5	-	-	4	5
Tubal Pathology	16	20	2	2.5	18	22.5
Endometriosis	6	7.5	2	2.5	8	10
Total	65	81.25	15	18.75	80	100

Among the study participants, majority had normal laparoscopy findings (40%). The majority causes of infertility were the Tubal causes (22.5%), with majority leading to primary infertility.

Table 5: Uterine Causes

Type	Number
Fibroid	4
Septate Uterus	3
Bicornuate Uterus	1
Arcuate Uterus	2

Among the study participants 4 cases had fibroid uterus, 3 cases had septate uterus, 2 cases had arcuate uterus and 1 case had bicornuate uterus.

Table 6: Tubal Patency (Chromopertubation Test)

Findings	Primary (n = 40)		Secondary (n = 10)		Total (n = 50)	
		%		%		%
Bilateral Spillage	47	58.75	10	12.5	57	71.25
Unilateral Spillage	11	13.75	4	5	15	18.75
Delayed Spillage	2	2.5	1	1.25	3	3.75
No Spillage	5	6.25	-	-	5	6.25
Total	65	81.25	15	18.75	80	100

Among the study participants bilateral spillage was seen in 57 cases, unilateral spillage in 15 cases, delayed spillage in 3 cases and no spillage in 5 cases.

Table 7: Therapeutic Procedures for Enhancing Fertility

Procedure	Number
Ovarian Cystectomy	4
PCO Drilling	6
Hysteroscopic Polypectomy	1
Septal Resection	3

Among the study participants 6 cases had Polycystic ovarian drilling, 4 cases had cystectomy, 3 cases had septal resection, and 1 case had polypectomy.

Table 8: Complications

Complications	No. of Patients	Percentage
Bleeding From Cervix	6	7.5
Gaseous Distension of Abdomen	1	2
Wound Gaping	1	2

Among the study participants the complications observed were post procedure bleeding in 6 cases and gaseous distention of abdomen and wound gaping in 1 case each.

4. Discussion

This is a Retrospective Study conducted on 80 cases of infertile women who attended OPD and were admitted in Department of OBG, PESIMSR, Kuppam for evaluation of infertility during the period of 18 Months from June 2021 to December 2022. The data was tabulated and analyzed in detail and the same was compared with statistics of various other studies.

With the wide spread use of minimally invasive techniques, Laparoscopy has become gold standard in evaluation of female infertility⁷.

In our study of 80 cases who underwent laparoscopy 65 cases (81.25%) had primary infertility and 15 cases (18.75%) had secondary infertility, which was similar to Qurat - ul - Ain W et al⁸ study which was conducted on 100 infertile women in Delhi, in which 82% cases were of

primary infertility and the remaining 18% cases were of secondary infertility.

The commonest age group of presentation among primary infertile cases was 21 - 25 years with 25 cases (31.25%) and among secondary infertile cases was 26 - 30 years with 8 cases (10%), which was comparable to a retrospective study conducted at Bangalore on 50 infertile patients by Chaitra Krishna et al⁹, where the age at presentation was 21 - 25 years in primary infertility and 26 - 30 years in secondary infertility.

Normal laparoscopic findings were seen in 32 (40%) cases out of total 80 cases which is comparable with a retrospective study conducted on 546 patients who underwent hystero - laparoscopy in Indore, MP by Bhandari S et al¹⁰ where 95 (47.9%) patients of 198 patients had normal findings.

In the study population Tubo - Ovarian causes were major contributing factors for infertility which was comparable to studies conducted by Kiridi EK et al¹¹ and Omidiji OA et al¹².

In the study population, the frequency of abnormal tubal spill on chromopertubation with secondary infertility were seen in 5 cases (7.25%) in comparison with primary infertility were seen in 18 cases (22.5%) and were found similar to that in a prospective study by Chaitra Krishna et al⁹ where 33.3% patients in secondary and 28.5% patients in primary infertility had abnormal tubal spill. Hystero - laparoscopy with chromopertubation is definitely superior in diagnosis of various kinds of tubal pathologies.

In the present study, uterine abnormalities constituted 12.5% of all the women presenting with infertility. According to a study by MI Khan et al¹³, uterine anomalies constitute 10% in infertile women. The most common uterine anomaly in our study is a septate uterus which is similar to Huma Nishat et al¹⁴ study.

A total of 14 therapeutic procedures were performed in the study participants, the most commonly performed procedure was, PCO drilling in 7.5% cases, ovarian cystectomy in 5% cases, septal resection and polypectomy comparable with a prospective study conducted in Ludhiana by Puri Set al¹⁵, with ovarian cystectomy in 4% cases.

5. Conclusion

Diagnostic hysterolaparoscopy is a gold standard procedure in evaluation and management of pelvic pathologies leading to infertility. In the same session, there is also a chance to treat the identified pathology in the uterus, tubes, ovaries, or peritoneum, reducing the need for a second procedure and allowing for better planning of follow - up care.

References

- [1] Zegers - Hochschild F, Adamson GD, Dyer S, Racowsky C, De Mouzon J, Sokol R, Rienzi L, Sunde A, Schmidt L, Cooke ID, Simpson JL. The international glossary on infertility and fertility care,

2017. Human reproduction.2017 Sep 1; 32 (9): 1786 - 801.
- [2] Schankath AC, Fasching N, Urech - Ruh C, Hohl MK, Kubik - Huch RA. DHL in the workup of female infertility: indications, technique and diagnostic findings. Insights into imaging.2012 Oct; 3: 475 - 83.
- [3] Yu SL, Yap C. Investigating the infertile couple. Ann Acad Med Singapore.2003 Sep 1; 32 (5): 611 - 14.
- [4] Ranjan P, Ranjan R. Role of Imaging in Female Infertility. World Journal of Surgical Research.2016 Dec 23; 5 (6).
- [5] Danfulani M, Ahmed S, Haruna Y. Laparoscopic Hysteroscopic findings in women with infertility in Sokoto North Western Nigeria. African Journal of Medical and Health Sciences.2014 Jan 1; 13 (1): 19 - .
- [6] Dyer SJ. International estimates on infertility prevalence and treatment seeking: potential need and demand for medical care. Hum Reprod 2009; 24 (9): 2379–2380. DOI: 10.1093/humrep/dep219.
- [7] Kotdawala P, Kotdawala S. Role of laparoscopy before Intrauterine insemination. In: Mukherjee GG, Chakravarty BN, editors. Intrauterine Insemination. New Delhi: Jaypee Brothers Medical Publication Pvt Ltd; 2012. p.45.
- [8] Qurat - ul - Ain W, Ara R, Dangroo SA, Beig M. Diagnostic Laparoscopy in the Evaluation of Female Factors in Infertility in Kashmir Valley. Int J Women's Health Reprod.2014; 2 (2): 48 - 57.
- [9] Chaitra K, Prathima S, Chandraiah S, GS Anitha. Laparoscopy as a diagnostic tool in evaluation of female factors in infertility. Int J Reprod Contracept Obstet Gynecol.2017 Mar; 6 (3): 864 - 7.
- [10] Bhandari S, Singh A, Agrawal P, Ganguli I. Findings in diagnostic laparoscopy in patients with unexplained infertility. Fertl Sci Res.2015; 2 (1): 29 - 33.
- [11] Kiridi EK, Ibrahim IA, Lawani L. DHL: still relevant in the evaluation of infertility in the Niger Delta. International Journal of Medicine and Biomedical Research.2015; 4 (1): 50 - 4.
- [12] Omidiji OA, Toyobo OO, Adegbola O, Fatade A, Olowoyeye OA. DHL findings in infertility–what has changed over the years?. African health sciences.2019 Aug 19; 19 (2): 1866 - 74.
- [13] Khan MI, Jesmin S, Jerin J, Shermin S, Chowdhury TA. DHL in Infertility. Delta Medical College Journal.2014 Jan 29; 2 (1): 9 - 12.
- [14] Nishat H, Singh K, Tiwary B, Kumari S, Shashi K, Kumari M. A retrospective study on role of DHL in evaluation of female infertility. Journal of Indira Gandhi Institute Of Medical Sciences.2021 Jul 1; 7 (2): 111.
- [15] Puri S, Jain D, Puri S, Kaushal S, Deol SK. Laparohysteroscopy in female infertility - A diagnostic cum therapeutic tool in Indian setting. Int J App Basic Med Res.2015; 5 (1): 46 - 8.