

# Seal and Heal: A Case Report

Sravanthi R<sup>1</sup>, Smitha R<sup>2</sup>, Shekar K<sup>3</sup>

<sup>1</sup>Senior lecturer, Department of Conservative & Endodontics, Mallareddy institute of dental sciences, Telangana, India

<sup>2</sup>Professor, Department of Conservative & Endodontics, Sri Sai College of dental Surgery, Vikarabad, Telangana, India

<sup>3</sup>Professor, Department of Conservative & Endodontics, Sri Sai College of dental Surgery, Vikarabad, Telangana, India

**Abstract:** Trauma to the teeth can lead to a wide range of injuries, varying in severity from enamel fractures to avulsions. Root fracture in permanent teeth is quite uncommon with frequency between 0.5% and 7% among all cases of dental trauma. This case report describes healing of horizontal midroot fracture of central incisor with 2 yr follow up evaluated with cone beam computed tomography (cbct). A 28 year old male patient was received trauma causing Horizontal mid root fracture at right maxillary central incisors. The Clinical and radiographic examinations were done and proper management was carried out. The patient was asymptomatic at 2 years follow-up, and the cbct showed good signs of healing.

**Keywords:** Horizontal midroot fracture, Biodentin, CBCT

## 1. Introduction

Trauma to the teeth can lead to a wide range of injuries, varying in severity from enamel fractures to avulsions. Upper central incisors are vulnerable to this type of injury, being affected in 80% of dental trauma, followed by upper lateral incisors and lower incisors.<sup>1,2</sup> Considering the types of trauma, root fractures are less frequent, with prevalence of 0.5% to 7% in permanent dentition and 2 to 4% in deciduous teeth.<sup>3-5</sup>

Horizontal root fractures occur most commonly in middle third followed by apical third and least in coronal third with or without displacement of the coronal fragment.<sup>6,7</sup> Immediate treatment requires repositioning of the coronal fragment and splinting.<sup>8,9</sup> Teeth with horizontal root fractures often present with mobility, extrusion, and displacement of the coronal fragment in varying degrees depending on the location of the fracture and the severity of trauma.<sup>10</sup>

Recently, CBCT has been recommended as the imaging modality of choice for diagnosis and management of dentoalveolar trauma, including root fractures.<sup>11,12</sup>

Biodentine is a new tricalcium silicate (Ca<sub>3</sub>SiO<sub>5</sub>) based inorganic cement which has better physical and biological properties compared to other tricalcium silicate cements. This novel calcium based cement has bioactive properties and shows mineralization similar to dentin. It is indicated for pulpotomy, furcation repair, root perforations,<sup>13</sup> internal and external root resorption repair, root end repair<sup>14</sup> material and as a root canal sealer.<sup>15</sup>

The purpose of this case report is to present the use of biodentin as a sealer to enhance the healing of the horizontally fractured maxillary central incisor evaluated through CBCT.

## 2. Case Report

A 28-year-old male patient reported to the department of Conservative Dentistry and Endodontics Sri Sai Dental College & Hospital with a chief complaint of fractured maxillary central incisors and pain related to same teeth. He has a history of trauma to the anterior region one month back.

Clinical examination revealed Ellis class IV fracture with grade I mobility corresponding to 11. Ellis class III fracture was present corresponding to 21. There was no sensitivity to palpation, but sensitive to percussion. Both 11 and 21 did not respond to cold and heat test.

Radiographic examination revealed horizontal mid root fracture #11 while #21 had crown fracture fig.1. The immediate treatment consisted of semi-rigid splinting with orthodontic wire and photopolymerizable composite resin for 1 months.

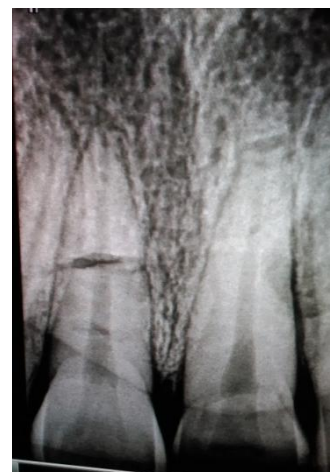

Figure 1: Preoperative radiograph

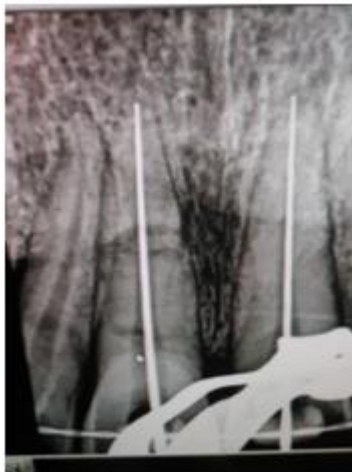
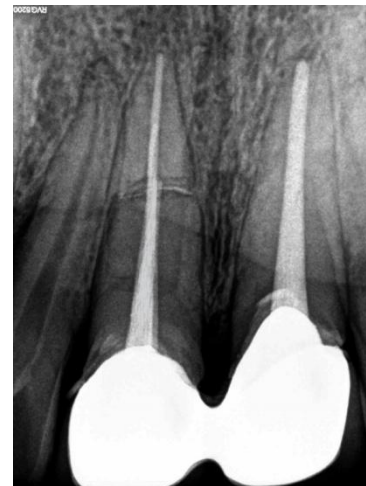
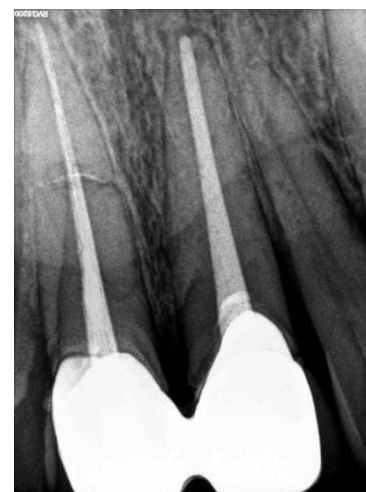Figure 2: Working Length Determination

Endodontic treatment was planned for the patient. An informed consent was obtained from the patient after explaining the treatment procedure. Access cavity preparation was done followed by working length determination after local anesthesia under rubber dam fig.2. Instrumentation was performed using K- files(Mani, Japan). Along with instrumentation, irrigation was performed by 3%NaOCl (parcan, septodent healthcare PVT LTD., India) and 17% EDTA(Dent Wash, Prime Dental PVT LTD., India)alternatively separated by saline. An inter appointment calcium hydroxide dressing was given and patient recalled after 2 weeks.

In the second visit, teeth were asymptomatic and pain had subsided. Root canals were obturated with gutta-percha and biodentin sealer (Bio root RCS, Septodent). The access cavities were then restored with composite resin and finally restored with PFM crowns. Post operative follow up is done for one month, six months, one year, two years. Clinically the patient was asymptomatic and there is no mobility. Radiographically (fig.3) there is healing of the fractured line by the formation of the calcific tissue at peripheries of the fractured line and there is a decrease in radiolucency around the fracture fragments. At the end of two years lamina dura is intact and there is no periapical pathology on digital radiographs fig.3d. Cone Beam Computed Tomography (CBCT) was carried out to evaluate the healing fig.4.



c) 1 year



d) 2 years follow-ups

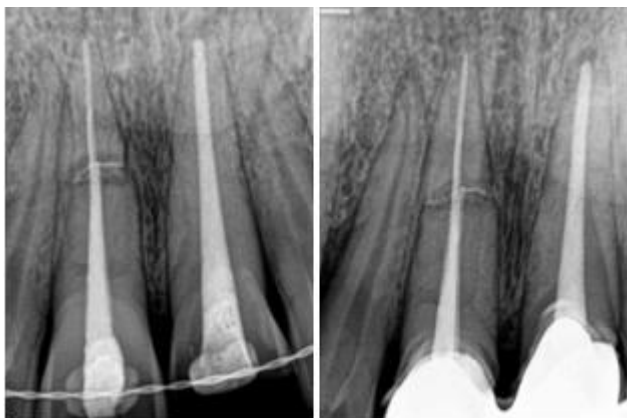
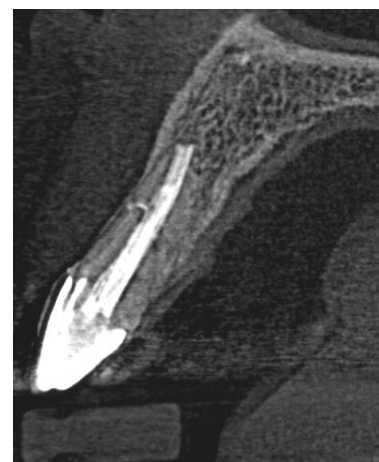
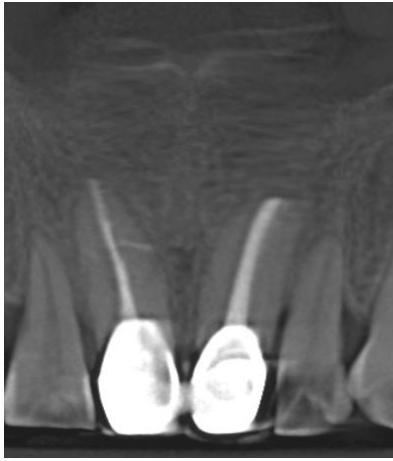
Figure 3: IOPA a)1-month b) 6 months



**Figure 4:** Cone beam computed tomography images showing the healing of fracture root; (a) sagittal view, (b) coronal view

### 3. Discussion

Root fractures may be successfully treated when appropriate procedures are carried out. Treatment consists of reducing the fracture line and splint stabilization.<sup>16</sup>

Clinical or radiographic findings revealing the development of pulp necrosis are found in 20 to 40% of root fracture cases,<sup>17,18</sup> in which chemo mechanical preparation significantly reduces the amount of bacteria. According to Iraler et al. these cases require intervention in both coronal and apical root portions, so as to avoid necrotic debris especially in the second fragment that certainly hinders tooth prognosis.<sup>19,20</sup> The use of antimicrobial intracanal dressing, such as calcium hydroxide, has been suggested with a view to reverse intra osseous necrosis at fracture line. According to Diangelis and Bakland this type of medication prevents infection, contributes to total reduction of microbes ensuring treatment success.<sup>21</sup>

MTA-based materials extrusion outside the root canal is associated with the severe pain felt by the patient.<sup>22</sup> When bioceramic-based sealers BioAggregate or iRoot SP are extruded, the pain is relatively small or totally absent. Such lack of pain may be explained by the characteristics of these new materials. During hardening they “produce” hydroxyapatite and after the end of hardening process they exhibit the same features as non-resorbable hydroxyapatite based bioceramics used for bone replacement in oral surgery.

Recently different types of bioactive materials are introduced which have the property of mineralization in the presence of water and formation of hydroxyapatite crystals. Biodentin being the most popular material have the ability of deposition of hydroxyapatite in contact with the fracture line and surrounding fluid.<sup>23</sup>

The amount of calcium ions released as well as the depth of incorporation into human root canal dentine in case of biodentin was significantly higher than those found for MTA.<sup>24</sup>

Recently, CBCT was introduced in dentistry which is proved to be a vital tool in diagnosis, management, and monitoring of dentoalveolar trauma that provide three-dimensional image.<sup>25</sup> In this case, the traumatized area was evaluated with CBCT at the follow-up visit which displays signs of healing.

### 4. Conclusion

With the advent of bioceramic sealers, a permanent tooth with horizontal mid root fracture can be treated with a good prognosis, thus preserving aesthetics and psychological integrity of the patient. Further studies with histological evaluation are necessary to validate the role of biodentin in mid root fracture healing.

### References

- [1] Andrade, E. S., de Campos Sobrinho, A. L., Andrade, M. G., & Matos, J. L. (2008). Root healing after horizontal fracture: a case report with a 13-year follow up. *Dental traumatology : official publication of International Association for Dental Traumatology*, 24(4).
- [2] Hovland E. J. (1992). Horizontal root fractures. Treatment and repair. *Dental clinics of North America*, 36(2), 509–525.
- [3] Andreasen FM, Andreasen JO. Root fractures. In: Andreasen JO, Andreasen FM, (1994). Textbook and color atlas of traumatic injuries to the teeth, Copenhagen: Munksgaard, 3<sup>rd</sup> edn, 279–311.
- [4] Karhade, I., & Gulve, M. N. (2016). Management of Horizontal Root Fracture in the Middle Third via Intraradicular Splinting Using a Fiber Post. *Case reports in dentistry*, 2016, 9684035.
- [5] Celenk, S., Ayna, B. E., Ayna, E., Bolgul, B. S., & Atakul, F. (2006). Multiple root fracture: a case report. *General dentistry*, 54(2), 121–122.
- [6] Caliřkan M. K. (2004). Prognosis of large cyst-like periapical lesions following nonsurgical root canal treatment: a clinical review. *International endodontic journal*, 37(6), 408–416.
- [7] Bramante C. M, Menezes R, Moraes I. G, Bernardinelli N, Garcia R. B, and Letra A, (2006). “Use of MTA and intracanal post reinforcement in a horizontally fractured tooth: a case report.” *Dental Traumatology*, 22(5):275–278.
- [8] Zachrisson, B. U., & Jacobsen, I. (1975). Long-term prognosis of 66 permanent anterior teeth with root fracture. *Scandinavian journal of dental research*, 83(6), 345–354.
- [9] Bender, I. B., & Freedland, J. B. (1983). Clinical considerations in the diagnosis and treatment of intra-alveolar root fractures. *Journal of the American Dental Association (1939)*, 107(4), 595–600.
- [10] Andreasen J. O, Andreasen F. M, Mejare I, and Cvek M, (2004). “Healing of 400 intra-alveolar root fractures. Effect of preinjury and injury factors such as sex, age, stage of root development, fracture type, location of fracture and severity of dislocation.” *Dental Traumatology*, 20(4):192–202.
- [11] Orhan K, Aksoy U, and Kalender A. (2010). “Cone-beam computed tomographic evaluation of

- spontaneously healed root fracture,” *Journal of Endodontics*, 36( 9):1584–1587.
- [12] May, J. J., Cohenca, N., & Peters, O. A. (2013). Contemporary management of horizontal root fractures to the permanent dentition: diagnosis--radiologic assessment to include cone-beam computed tomography. *Pediatric dentistry*, 35(2), 120–124.
- [13] Nowicka, A., Lipski, M., Parafiniuk, M., Sporniak-Tutak, K., Lichota, D., Kosierkiewicz, A., Kaczmarek, W., & Buczkowska-Radlińska, J. (2013). Response of human dental pulp capped with biodentine and mineral trioxide aggregate. *Journal of endodontics*, 39(6), 743–747.
- [14] BioDentine: A dentin substitute for the repair of root perforations, apexification and retrograde root filling. Dr Francois Bronnec DDS, MSc.
- [15] Bachoo, I. K., Seymour, D., & Brunton, P. (2013). A biocompatible and bioactive replacement for dentine: is this a reality? The properties and uses of a novel calcium-based cement. *British dental journal*, 214(2), E5.
- [16] Ferrari, P. H., Zaragoza, R. A., Ferreira, L. E., & Bombana, A. C. (2006). Horizontal root fractures: a case report. *Dental traumatology : official publication of International Association for Dental Traumatology*, 22(4), 215–217.
- [17] Cvek, M., Mejàre, I., & Andreasen, J. O. (2004). Conservative endodontic treatment of teeth fractured in the middle or apical part of the root. *Dental traumatology : official publication of International Association for Dental Traumatology*, 20(5), 261–269.
- [18] Díaz S C, Ferreyra S, Gutmann J L. (2013). Healing of a horizontal root fracture with lateral luxation of the coronal fragment: A 3-year follow-up. *Endodontology (Lond Engl)*, 7(4):291–297.
- [19] Irala LED, Salles AA, Müller MAS, Pinto TAS. (2011). Oblique root fracture in permanent maxillary central incisor: case report. *Stomatos*, 17(32):72-82.
- [20] Brunini SHS, Silva Junior EG, Trida IM. (2014). Horizontal root fracture: A case report. *Dental Press Endodontics*, 4(1):63-6.
- [21] Diangelis, A. J., & Bakland, L. K. (1998). Traumatic dental injuries: current treatment concepts. *Journal of the American Dental Association (1939)*, 129(10), 1401–1414.
- [22] Kossev D, Stefanov V. (2009). Ceramics-based sealers as new alternative to currently used endodontic sealers. *Research ceramics-based sealers*, 1:42-48.
- [23] Camilleri, J., Sorrentino, F., & Damidot, D. (2013). Investigation of the hydration and bioactivity of radiopacified tricalcium silicate cement, Biodentine and MTA Angelus. *Dental materials: official publication of the Academy of Dental Materials*, 29(5), 580–593.
- [24] Han, L., & Okiji, T. (2011). Uptake of calcium and silicon released from calcium silicate-based endodontic materials into root canal dentine. *International endodontic journal*, 44(12), 1081–1087.
- [25] Alenezi MA, Al-Hawwas AY, Al-Qathami H. (2017). Healing of transverse root fracture evaluated by using cone beam computed tomography: Case report with 2 years follow-up. *Saudi Endodontic Journal*, 7:119-22.