

Homeopathic Treatment of Oral Papillomatosis in Dogs (*Canis familiaris*) - Case Report

Ana Catarina Viana Valle

Abstract: Canine oral papillomatosis is a disease caused by the papillomavirus that affects young dogs or immunocompromised animals. Papillomatosis results in verrucous lesions in the oral mucosa, causing discomfort, difficulty in chewing and/or swallowing, and, in some cases, predisposing to the development of oral carcinomas in this species. In general, this disease is self-limiting and has spontaneous regression within five months. However, some animals do not evolve well, and more invasive treatments are needed. In this context, integrative therapies, especially homeopathy, are increasing in interest in the medical and veterinary clinical routine. *Thuya occidentalis*, for example, is often indicated to treat papillomatosis in humans and animals and has proven efficacy. This plant has antiviral, antibacterial, and antifungal properties and is widely used for treating condylomatous and verrucous skin lesions. In addition, *Viscum album L.* contains several biologically active substances, most of which play a substantial role in cancer treatment due to their apoptotic, immunomodulatory, and cytotoxic effects. Therefore, this article aimed to report the oral papillomatosis treatment in two young dogs of different breeds using homeopathic therapy. It combined injectable and oral administration of *T. occidentalis* with injectable *V. album*, showing excellent results in disease resolution.

Keywords: Papillomavirus, Homeopathy, *Thuya occidentalis*, *Viscum album*

1. Introduction

Papillomatosis is a disease that occurs in mammals and generally comprises a self-limited proliferative disorder of the epithelium (Miller et al., 2013). The first occurrence of papillomatosis in dogs was recorded in 1898 (Nicholls and Stanley, 1999). This disease is thought to cause oral and cutaneous cell proliferation in dogs, but it is rarely associated with developing cutaneous and oral squamous cell carcinomas in this species. In cats, papillomatosis is thought to cause oral epithelial proliferation, Bowenoid *in situ* carcinomas, and sarcoids (Munday et al., 2017).

The etiology of papillomatosis was identified in 1959 (Nicholls and Stanley, 1999) and is linked to the infection caused by the papillomavirus, an unenveloped double-stranded DNA virus with tropism for mucous membrane and skin (Hnilicia and Patterson, 2017). Twenty types of papillomaviruses have already been identified in the canine species (Van Doorslaer et al., 2017). Papillomavirus type 1, the more frequently found in this species, is involved in the development of oral papillomatosis. It is the most identified type in young dogs (Lange and Favrot, 2011), mainly in animals under 4 - years old. There is no racial or sexual predisposition (Biricik et al., 2008).

Papillomatosis is characterized by high morbidity, low mortality with a favorable prognosis, and no disease recurrence since the patient acquires immunity to the virus (Favrot, 2012). Elderly and/or immunocompromised animals become more susceptible to papillomavirus infection. In dogs, the course of the disease persists for about four weeks until its spontaneous regression, which is not observed in immunocompromised animals. These types of papillomas can usually occur on the face, ears, and feet in young dogs and, occasionally, in older dogs (Yuan et al., 2007).

The diagnosis is clinical. In most cases, the association of aspects of the lesions and their signs combined with anamnesis is necessary for the diagnostic conclusion. However, histopathological evaluation may be necessary to

complete it. Treatment is controversial and can be performed in different ways. Surgery is the most used therapy among conventional veterinarians. However, some professionals choose not to treat when the diagnosis is made at the onset of the disease, as spontaneous regression may occur within four weeks. Other treatment options for persistent cases include cryotherapy, chemotherapy with vincristine or cyclophosphamide, and autogenous vaccines (Sherding, 2008), auto-hemotherapy, laser therapy, antibiotic therapy, topical applications with fluorouracil or *T. occidentalis* (Agnihotri et al., 2015), and homeopathic combination therapy (Raj et al., 2020). There are also reports of single oral therapy with *T. occidentalis* conferring total regression after 21 days of treatment (Benites and Melville, 2003).

In this context, homeopathy is a therapeutic technique enunciated in 1796 by the German physician Samuel Hahnemann. It proposes the cure of diseases by administering highly diluted and agitated medicines with animal, mineral, or vegetable origin. These medicines can subtly change the organism's homeostasis and aid the vital energy towards its re-establishment, called a state of physical and mental health. Based on the satisfactory clinical effects of homeopathic medicines observed in animals, veterinarians are growing interest in homeopathic treatments, whether due to their low cost, ease of administration, or absence of side effects (Valle and Carvalho, 2021).

This study aimed to report two cases of oral papillomatosis in young female dogs of the English Bulldog and Pug breeds, treated by homeopathy using injectable and oral *T. occidentalis* combined with injectable *V. album*.

2. Material and Methods

The animals were seen at the NaturalPet Veterinary Clinic, Brasilia, Brazil, Case 1 in 2017 and Case 2 in 2019.

Case 1– Female dog, Pug breed, 3 - year - old, appetent, fed with commercial dog food, weighing 7.8 kg, and always treated by conventional medicine. The patient was referred

with a diagnosis of papillomatosis for five months. She had already undergone conventional treatment and was subjected to a surgical procedure to remove the lesions. The lesions had relapsed after three months from the first surgical intervention, with no treatment since then. On physical examination, the patient had normal colored mucosa, TPC 2", active and alert behavior, cardiac and respiratory auscultation within the expected normal for age and species, slight overweight, hydration conditions within the expected normal range. Visual inspection of the oral cavity revealed characteristic cauliflower - like growth/lesions similar to those caused by the papillomavirus in the medial portion of the left lower lip (Figure 1A) and multiple proliferative

lesions in the right upper labial commissure (Figure 1B). At this moment, the following treatment protocol using homeopathy was prescribed: three drops of *T. occidentalis* 6CH TID for 30 days, associated with one ampoule of *T. occidentalis* D9 (Injectcenter®) and one ampoule of *V. album* D3 (Injectcenter®) given subcutaneously twice a week for 30 days. The surgical removal of the lesions was also performed three days after the first veterinary appointment. A sample of the lesions was submitted for histopathological analysis.

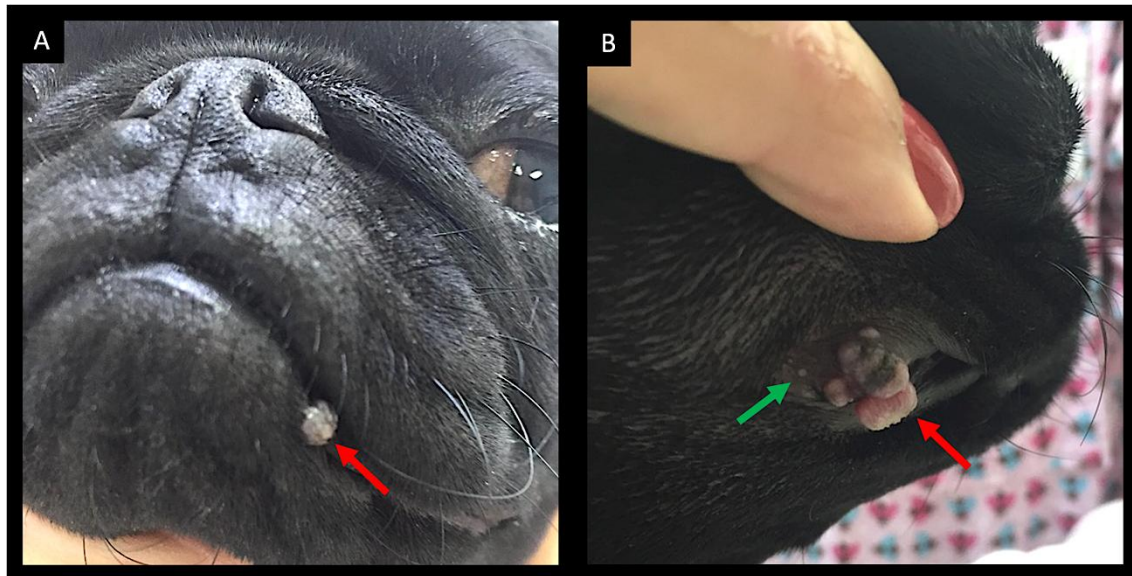


Figure 1: A) Lesion in the lower lip, medial portion, cauliflower - like growth, whitish, approximately 8mm in diameter indicated by the red arrow. B) Multiple papillomatosis - like lesions near the right upper labial commissure

Case 2 – Female dog, English bulldog breed, 3 - years and 5 - months old, appetent, fed with natural food, weighing 15kg, and always treated by integrative medicine. The tutor noticed a whitish and rounded lesion in the left medial cranial region of the dog's tongue for approximately one week and took it to the veterinarian for evaluation. The tutor also commented that the patient had contact with dogs in the park one month before the veterinary appointment. The tutor noticed that two of the dogs had similar lesions two weeks after they last met. On physical examination, the patient had normal colored mucosa, TPC 2", active and alert behavior, cardiac and respiratory auscultation within the expected normal for age and species, hydration conditions within the expected normal range. Visual inspection of the oral cavity showed a single cauliflower - like growth/lesion in the medial portion of the left lower lip, which is characteristic of lesions caused by the papillomavirus (Figure 2). At this moment, the following homeopathic treatment protocol was instituted: three drops of *T. occidentalis* 6CH TID for 30 days combined with one ampoule of *V. album* D3 (Injectcenter®) given subcutaneously three times a week for 30 days. The clinical treatment was chosen as the only treatment.

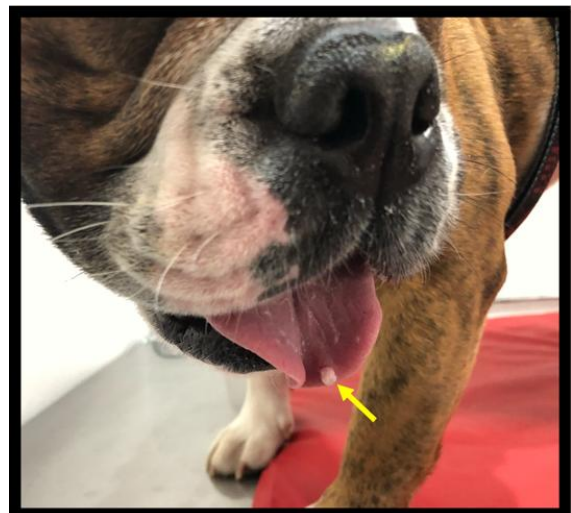

Figure 2: Lesion with a cauliflower - like appearance in the medial cranial portion of the tongue indicated by the yellow arrow

3. Results

The results of both cases were favorable. The patient described in Case 1 presented suture dehiscence in the right labial commissure, healing by second intention. Even after surgical removal, a lesion at an initial stage was observed

(Figure 3). However, it did not evolve after the first week of treatment. In addition, no recurrences were recorded. The biopsy result confirmed the clinical diagnosis of a lesion caused by the papillomavirus. In its turn, the patient described in Case 2 had an excellent evolution with the treatment prescribed, with no recurrences recorded. Disease regression occurred in just 15 days and with great results (Figure 4).

4. Discussion

Papillomavirus generally affects young and immunocompromised animals, causing lesions in the skin and oral cavity. Most lesions are benign neoforations of epithelial cells. Disease transmission occurs by direct or indirect contact with secretions or blood from papillomas present in infected animals. Spontaneous regression can be observed in some cases, which usually makes it difficult to assess the effectiveness of therapeutic protocols (Vieira and Poggiani, 2012). However, relapses may occur in certain immunocompromised patients when not adequately treated.

T. occidentalis is a tree native to Europe and has been widely used for centuries by homeopathy to treat papillomas by human and veterinary medicines. Its therapeutic activity

is indicated as an immunostimulant, antiviral, and it also promotes the proliferation of T lymphocytes and the production of IL - 2. In addition, there are reports of its association with other immunomodulatory plants, such as *Echinacea purpurea*, *E. pallida*, and *Baptisia tinctoria* (Naser et al., 2005). This study chose the association with the *V. album* D3 medicine due to its proven immunostimulating activity, resulting in the satisfactory results described above.

Many studies have been published on the description, mode of action, and clinical use of herbal substances, particularly about the different essential oil contents of *T. occidentalis* related to the extraction procedures used. The antiviral action of *T. occidentalis* and its immunopharmacological potential, such as stimulatory effects on the production of cytokines and activation of macrophages and other immunocompetent cells, were evaluated in numerous *in vitro* and *in vivo* investigations. Although no controlled trials have been performed with *T. occidentalis* alone, many clinical studies have been conducted with it and other immunostimulant medicines, demonstrating their therapeutic efficacy and safety (Naser et al., 2005).

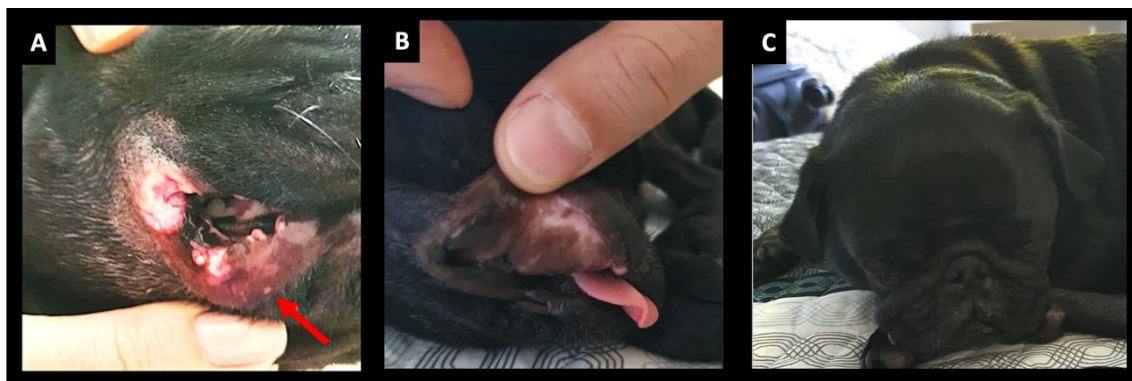


Figure 3: A) Lip appearance after the surgical removal of lesions. Red arrow indicated lesion at an initial stage after surgery. B) Lip appearance after 2 meses do procedimento cirurgico e sem surgimento de novas lesões. C) Imagem do animal 1 ano depois



Figure 4: Aspect of the tongue after lesion resolution of the lesion diagnosed as papillomatosis.

Monteiro (2007) performed an *in vivo* experiment with 40 female dairy bovine, crossbred Dutch, in a semi - intensive regime, with different degrees of cutaneous papillomas. They were treated with *T. occidentalis* mother tincture and *T.*

occidentalis manipulated according to the homeopathic pharmacopeia. The study aimed to verify if *T. occidentalis* effectively treated bovine papillomatosis and compare the efficacy between the two pharmaceutical forms. The author described no partial and total regression in the groups that received the *T. occidentalis* 30% mother tincture (TM) and *T. occidentalis* 30% TM with propolis. However, total lesion regression was observed in 20% of the animals and partial regression in 80% in other members in the group daily treated with *T. occidentalis* CH6 (1×10^{-12}) for 63 days. These results were confirmed by histopathological examination. These findings confirm, once again, the effectiveness of using *T. occidentalis* CH6 to treat bovine cutaneous papillomatosis. Monteiro (2007) also evaluated the biochemical blood dosages of the treated animals, proving that the *T. occidentalis* administration was safe for continuous use within the experiment period, not producing liver and kidney alterations during that period. Our study corroborates Monteiro (2007) since two dogs diagnosed with papillomatosis were treated with *T. occidentalis*, and

satisfactory results were obtained with clinical improvement in less than 30 days.

Raj et al. (2020) carried out an experiment with 16 dogs diagnosed with oral papillomatosis and treated by homeopathic therapy using *Sulfur* 30CH, *Thuia* 30CH, *Graphites* 30CH, and *Psorinum* 30CH. The animals were randomly divided into two groups (n = 16), homeopathic treatment group (n = 8), and placebo/control group (distilled water) (n = 8). The medicines were orally given twice a day for 15 days. The patients were evaluated over 12 months. The homeopathic treatment group had an excellent recovery, showing a significant reduction in oral lesions assessed by clinical score (p<0.001) compared to the placebo - treated group. Oral lesions decreased in the homeopathic group between 7 and 15 days, while in the control group, it occurred between 90 and 150 days. The homeopathic - treated group was observed for 12 months post - treatment, and no disease recurrence was recorded. According to the authors, the homeopathic treatment aided in the regression of clinical signs of canine oral papilloma, accelerated the healing process, and proved to be safe and cost - effective.

Similar to Raj et al. (2020), Lopes et al. (2019), and Benites and Melville (2003), this article successfully used *T. occidentalis* in the treatment of papillomatosis in dogs. In Case 2, we highlight the effectiveness of the homeopathic treatment for canine papillomatosis by the association of oral and daily *T. occidentalis* with subcutaneous *Viscum album* D3 given twice a week. Remission of the single lesion occurred in 15 days, demonstrating the fast resolution of the disease. The patient was followed up for two years until the time of publication of this article, with no recurrences. Case 1 patient had the disease in progress for more than five months, a history of previous surgical removal, and, even so, there was a recurrence. This situation proves that surgical removal is not efficient in some cases and that the disease must be treated systemically, efficiently stimulating the immune system. After the second surgical removal, the patient was treated by homeopathy with injectable (subcutaneous) and oral *T. occidentalis* combined with injectable (subcutaneous) *V. album* D3 to stimulate the immune system. The animal had therapeutic success and no longer presented the lesions, being followed up within five years.

5. Conclusion

The combination of the homeopathic medicines *T. occidentalis* and *V. album* showed excellent effects in treating canine oral papillomatosis. They were effective in their purpose, cause no side effects, and demonstrated to be a low - cost therapy. Therefore, we recommend further studies combining both medicines to confirm this activity in other patients.

6. Conflict of Interest

The authors declare that they have no conflict of interest.

References

- [1] Agnihotri D, Kushwah M, Kumar T, Kumar P, Kumar A, Srikant N, Sindhu N. Successful therapeutic management of a case of canine papillomatosis. *Haryana Vet.*2015; 54 (1): 79–80.
- [2] Benites NR, Melville PA. Homeopathic treatment of canine papillomatosis. *Clínica Vet.*2003; 8 (44): 19 - 20.
- [3] Biricik H, Cabalar M, Gulbahar M. Oral papillomatosis in a dog and its therapy with taurolidine. *Acta Vet Brno.*2008; 77 (3): 373–375.
- [4] Favrot C. Papillomavirus. In: Greene C (ed). *Infectious Disease of the Dog and Cat.*4th ed. Missouri: Elsevier Saunders; 2012. pp.169–174.
- [5] Hnilicia K, Patterson P. Viral, rickettsial and protozoal skin diseases (papillomas). In: Hnilicia K, Patterson P (eds). *Small Animal Dermatology A Color Atlas and Therapeutic Guide.*4th ed. Missouri: Elsevier; 2017. pp.175–177.
- [6] Lange CE, Favrot C. Canine papillomaviruses. *Vet Clin North Am Small Anim Pract.*2011; 41 (6): 1183 - 95.
- [7] Lopes DF, Valle ACV, Sibata MN, Sibata AS, Carvalho AC. Treatment of Canine Papillomatosis with Injectable *Thuja occidentalis* D9 – Case Report. *Anais of II Internacional Conference of Integrative Veterinary Medicine and IV Brazilian Symposium of Integrative Veterinary Medicine, Sao Paulo, 2019.*
- [8] Miller WH, Griffin CE, Campbell KL. Neoplastic and non - neoplastic tumors. In: Miller, WH, Griffin, CE, Campbell, KL (eds.) *Muller & Kirk's Small Animal Dermatology.*7th ed. St. Louis: Elsevier; 2013. pp.774–843.
- [9] Monteiro VLC. Use of *Thuja occidentalis* in the treatment of bovine papillomatosis: clinical, histopathological, and molecular aspects. Doctorate dissertation. Federal Rural University of Pernambuco, Recife, Brazil, 2007.
- [10] Munday JS, Thomson NA, Luff JA. Papillomaviruses in dogs and cats. *Vet J.*2017; 225: 23 - 31.
- [11] Naser B, Bodinet C, Tegmeier M, Lindequist U. *Thuja occidentalis* (Arbor vitae): A Review of its Pharmaceutical, Pharmacological and Clinical Properties. *Evid Based Complement Alternat Med.*2005; 2 (1): 69 - 78.
- [12] Nicholls PK, Stanley MA. Canine papillomavirus - A centenary review. *J Comp Pathol.*1999; 120 (3): 219 - 33.
- [13] Raj PAA, Pavulraj S, Kumar MA, Sangeetha S, Shanmugapriya R, Sabithabanu S. Therapeutic evaluation of homeopathic treatment for canine oral papillomatosis. *Vet World.*2020; 13 (1): 206 - 213.
- [14] Sherding RG. Viral diseases. In: Birchard SJ, Sherding RG (eds.). *Small animal clinic.* São Paulo: Roca; 2008. p.178 - 179.
- [15] Valle ACV, Carvalho AC. *Viscum Album* Therapy for Treating Lymphoma in an FIV and FeLV Positive Cat (*Felis catus*) - Case Report. *Integr J Vet Biosc.*2021; 5 (2): 1 - 5.
- [16] Van Doorslaer K, Li Z, Xirasagar S, Maes P, Kaminsky D, Liou D, Sun Q, Kaur R, Huyen Y,

McBride AA. The Papillomavirus Episteme: a major update to the papillomavirus sequence database. *NucleicAcids Res.*2017; 45D1: D499–D506.

- [17] Vieira LC, Poggiani SSC. Canine papillomatosis. *PUBVET.*2012; 6 (16): 1357 - 1362.
- [18] Yuan H, Ghim S, Newsome J, Apolinario T, Olcese V, Martin M, Delius H, Felsburg P, Jenson B, Schlegel R. An epidermotropic canine papillomavirus with malignant potential contains an E5 gene and establishes a unique genus. *Virology.*2007; 359: 28–36.