

Treatment of Grade 3 Furcation Involvement using Bioresorbable Collagen Membrane and Equine Xenograft: A Clinical Study

Dr. Dinesh Kumar A.T M.D.S.¹, Dr. Radhika B M.D.S.², Dr. Syed Owais Ahmed M.D.S.³, Dr. Vijila K⁴,
Dr. Anand Induchoodan M.D.S.⁵, Dr. Babu Salam C M.D.S.⁶

¹Senior Lecturer, Department of Conservative Dentistry and Endodontics, Rajas Dental College and Hospital, Tirunelveli 627105, India

²Periodontist and Implantologist, Private Practitioner, India

³Senior Lecturer, Department of Periodontics and Implantology, Sri Siddhartha Dental College and Hospital, Tumkur, Karnataka, India

⁴Postgraduate Student, Department of Periodontics and Implantology, Rajas Dental College and Hospitals, Tirunelveli 627105, India

⁵Periodontist and Implantologist, Private Practitioner (Aster Medical Center, Doha), India

⁶Periodontist and Implantologist, Private Practitioner, India
Corresponding Author e-Mail Id: [babumitzvah\[at\]gmail.com](mailto:babumitzvah[at]gmail.com)

Abstract: ***Aim:** Successful management of periodontitis is considered to be dependent on early diagnosis, targeted antimicrobial therapy and modifying the tissue architecture that is conducive to long-term maintenance. Osseous defects present a challenge in periodontal practice and successful treatment depends primarily on selection of the correct technique and materials. **Methods:** This clinical study presents the cases treated with different techniques and with same materials. The periodontal osseous defect was filled up with a bovine based bone graft substitute and covered with a restorable collagen GTR membrane. The results in all the cases discussed here are satisfactory and have shown long-term stability emphasizing the importance of selection of technique and material. **Conclusion:** Use of equine based xenograft with bioresorbable collagen membrane showed significant improved outcomes in regeneration of osseous defects while treating periodontitis patient.*

Keywords: Periodontal Osseous Defects, Guided Tissue Regeneration (GTR), Equine Xenografts, Healiguide Membrane

1. Introduction

Periodontitis is an infectious disease of the gingival tissue, changes that occur in the bone are crucial because the destruction of the bone is responsible for tooth loss.(1) The purpose of periodontal therapy is to eliminate the inflammation of the periodontal tissues, to arrest the destruction of soft tissue and bone caused by periodontal disease, and regenerate the lost tissue, if possible.(2) Bone grafting is the most common form of regenerative therapy and has been used for almost 100 years in attempts to stimulate healing of bony defects.(3) The predictable complete periodontal regeneration remains a major goal in the planned therapy. Anton Sculean, in 2017 put forth clinical protocols, that have shown to enhance periodontal regeneration and clinical outcomes in periodontal intrabony and class II furcation defects, which includes: (a) Use of Enamel Matrix Proteins (b) Guided Tissue Regeneration (c) Use of bone grafts enriched with growth factors (Or) Combination therapy. Despite several procedures such as usage of guided tissue regeneration (GTR), grafting materials, growth factors and/or host modulating agents have been attempted, the outcomes are not always predictable. (4-10) However, to our knowledge, there are no available studies comparing the efficacy of using a bioresorbable Type 1 collagen barrier (Healiguide) alone or combined with equine xeno graft (Bio-Gen - Bioteck®, Italy) Osseograft DMBM), in treating grade 3 furcation defects of chronic periodontitis.

2. Materials & Methods

Forty patients (with sixty defects) diagnosed with generalized chronic periodontitis having two or more vertical defects, were selected for this study from the OPD of private dental clinics, Trichy, Tamilnadu (India). Inclusion criteria are Patients diagnosed as with a probing depth of ≥ 5 mm with a horizontal furcation component probing of more than 3mm and radiographic evidence of furcation bone loss, age group of 35-55 years.

Study design: After initial Phase I therapy baseline measurements included Plaque Index, Gingival index, Probing pocket depth, and Clinical attachment level (using a UNC-15 probe with an occlusal stent). All the sites were examined to record the clinical and radiographic parameters.

Radiographic parameters: An Intraoral periapical radiograph of each defect site was exposed using the long cone-parallel technique. Digitized images were displayed on the monitor at 5X magnification using Adobe Photoshop 7.0 computer software. CBCT evaluation was done at immediate post surgery and 6 months postoperative period.

Surgical protocol: At the experimental sites, the defect was filled up with an bovine based bone graft substitute and healiguide membrane and suturing was done. The control sites were left unfilled after surgical debridement, thorough root planing, and irrigation of surgical wound was done with

Volume 10 Issue 3, March 2021

www.ijsr.net

Licensed Under Creative Commons Attribution CC BY

normal saline. The mucoperiosteal flaps were repositioned and secured in place using black, braided (4-0), interrupted silk sutures to obtain primary closure of the interdental space, and protected with a noneugenol dressing. All patients were prescribed an analgesic Diclofenac sodium 50 mg, twice a day, and Amoxicillin 500 mg thrice a day for five days.

Post-surgical protocol: After one week following surgery, the dressing and sutures were removed and the surgical site was irrigated thoroughly with saline. Clinical parameters and radiographic measurements were repeated for both control and experimental sites.

3. Results

Plaque index: No statistically significant differences were found in the mean values for the plaque index between the test and control groups at baseline (P = 0.173), one month (P = 0.956), three months (P = 0.729), and six months. (P = 0.181)

Gingival index: No statistically significant differences were found in the mean values for the gingival index between the test and control groups at baseline (P = 0.069), at one month (P = 0.050), three months (P = 0.060), and six months. (P = 0.172)

Probing pocket depth: No statistically significant differences were found between the test and control groups at baseline (P = 0.646) and three months (P = 0.109).

However, the mean values at six months (P = 0.014) were highly significant. The decrease in probing depth in the experimental site from baseline to six months postoperation was 64.26% as compared to the control group which showed a decrease of 54.52%.

Clinical attachment level: The difference between the mean values for the levels of clinical attachment at baseline (P = 0.65) in the test and control groups was not significant. However, the differences in the mean values of clinical attachment levels at three (P = 0.036) and six months (P < 0.001) were statistically significant. This gain in clinical attachment from the baseline to six months postoperatively was 84.82% for the experimental group and 68.83% for the control group.

Amount of bone fill in the defects: For control sites, the statistically significant mean difference in defect fill from the baseline was 4.2000 ± 0.9783 mm (P = 0.212) at three months and 3.8000 ± 0.8619 mm (P = 0.014) at six months. For experimental sites, the statistically significant mean difference in defect fill from baseline was 3.6667 ± 1.0293 mm (P = 0.013) at three months and 2.6333 ± 0.8958 mm (P < 0.001) at six months. The differences in the mean values of the amount of defect fill at baseline (P = 0.925) and at three months (P = 0.157) were not significant but the difference was statistically significant at six months (P < 0.001) between the experimental and control groups.

Table 1: Mean

changes in plaque index and gingival index score at different intervals

		Mean±SD	Mean Reduction from Baseline	% Reduction	t- value P-value
Plaque Index	Baseline	1.58±0.35	-	-	-
	6 Weeks	1.26±0.22	0.32±0.29	20.3	3.46
	3 Months	1.11±0.22	0.47±0.24	29.7	6.18
	6 Months	1.02±0.17	0.56±0.27	35.4	6.62
	9 Months	0.95±0.16	0.63±0.26	40.0	7.71
Gingival Index	Baseline	1.56±0.28	-	-	-
	6 Weeks	1.28±0.27	0.28±0.13	17.9	6.73
	3 Months	1.14±0.28	0.42±0.14	26.9	9.50
	6 Months	0.98±0.21	0.58±0.11	37.2	16.16
	9 Months	0.92±0.19	0.64±0.14	41.0	14.15

Table 2: Mean changes in probing depths and clinical attachment levels score at different intervals at control and experimental site

Assessment	Time	Experimental Site -A				Experimental Site -B				A Vs B		
		Mean±SD	Difference from Baseline	%	Significance p-value	Mean±SD	Difference from Baseline	%	Significance p-value	Mean difference	t- Value	Significance p- value
Probing pocket depth	Baseline	6.80±1.40	-	-	-	6.10±1.37	-	-	-	0.70	1.13	0.27
	6 Months	4.80±0.92	2.00±0.33	29.4	4.74 P<0.09	4.20±1.55	1.90±0.88	31.1	6.86	0.10	0.20	0.85
	9 Months	4.20±0.79	2.60±1.43	38.2	5.75 P<0.001	3.80±1.55	2.30±1.25	37.7	5.81	0.30	0.50	0.62
Clinical attachment level	Baseline	6.60±1.07	-	-	-	6.10±1.37	-	-	-	-	-	-
	6 Months	4.00±0.82	2.60±1.35	-	6.09 P<0.001	4.30±1.49	1.80±0.65	-	9.00	0.80	1.70	0.11
	9 Months	2.80±0.63	3.80±1.48	-	8.19 P<0.001	3.30±1.42	2.80±1.03	-	8.57	1.00	1.76	0.10

4. Discussion

A prominent clinical finding in advanced periodontal disease cases is infrabony defects. Numerous regenerative techniques have been developed to treat such defects with varying clinical results. GTR in combination with bone graft stands as a successful treatment modality in periodontal regenerative surgeries. The bone graft occupies the infrabony defect as a filler material. It helps in supporting the GTR membrane by preventing the collapse. It acts as a substitute for the lost bone and facilitates native bone formation. This process of formation of native bone is done by osteoconductive/ osteoinductive activity. It enhances the process of healing following surgery. It serves as a framework to the bone-forming cells and blood vessels, thereby encouraging formation of healthy new bone and also helping in the repair of the osseous defect. Collagen membrane is a bio-absorbable membrane. It undergoes resorption by getting incorporated into the connective tissues or by undergoing degradation by macrophages. This process takes about 6–8 weeks to complete. Even though they undergo resorption, their function in acting as a barrier is as effective as a nonresorbable membrane. The collagen membrane acts as a scaffold upon which the fibroblasts migrate and undergo proliferation to form the periodontal ligament fiber cells. The Type I collagen contained in membrane also has hemostatic property. This property enables the membrane to accelerate the wound healing in the surgical site, thereby yielding faster results. (11) Shaila V Kothiwale et al. 2009 (12) evaluated the efficacy of demineralized freeze dried bone allograft (DFDBA) and bovine derived xenogenic bone graft (BDX) [Bio-Oss] with amniotic membrane (AM) as guided tissue regeneration (GTR) in the treatment of human periodontal Grade II buccal furcation defects and can be concluded that at 9 months after surgery both therapies resulted in significant probing depth reductions and clinical attachment level gains and significant improvement was seen in bone fill and percentage gain with both the material, however, there was no significant difference between both. Nivedha Venkatesan et al. 2021(13) evaluated the efficacy of Amniotic membrane and Biphasic Calcium phosphate as compared to Collagen membrane and Biphasic Calcium phosphate for the management of periodontal intrabony defects concluded that Amniotic membrane can be used as a barrier membrane, in conjunction with Biphasic calcium phosphate, and provides comparable results to Collagen membrane with Biphasic calcium phosphate when used in the management of periodontal intrabony defects. Randomised controlled trial by Shaila et al 2009 (14), Kiany et al 2015 (15), Sali et al 2016 (16) compared AM/Biogide in combination with allograft and xenograft material for the management of grade II furcation defects and intrabony defects. After a post-operative period of 6 and 9 months, both the groups showed significant reduction in PPD, CAL, and percentage of bone fill, without any significant differences between the two groups. An equine bone substitute has been used in this study and clinical parameters and radiographs were compared. Comparative analysis of plaque index had non significant difference between the two sites. This improvement in gingival status could be due to the surgery and frequent supportive therapy provided. Experimental site

had a higher percentage of defect fill than did the control site, the difference being statistically highly significant.

5. Conclusions

Within the limitations of the current study, it can be concluded that Healiguide membrane in conjunction with DBBM, appears to provide better patient related outcomes and comparable clinical and radiological outcomes as with Collagen membrane alone, in the management of grade 3 furcation defects. Although equine based bone graft substitute has shown promising results on clinical and radiographic evaluation, additional long-term studies should be undertaken to obtain more clinical evidence for regular use of this material.

References

- [1] Carranza FA, Newman MG. Reconstructive osseous surgery. 8th ed. Philadelphia, USA: WB Saunders Company; 1999. Clinical Periodontology; pp. 622–39.
- [2] Reynolds MA, Aichelmann-Reidy ME, Branch Mays GI, Gunsolley JC. The efficacy of bone replacement grafts in the treatment of periodontal osseous defects. *Ann Periodontol.* 2003;8:227–65. (PubMed)
- [3] Nasr HF, Aichelmann Reidy, Yukna RA. Bone and bone substitutes. *Periodontology 2000.* 1999;19:74–86. (PubMed)
- [4] Stahl SS, Froum S. Human intrabony lesion responses to debridement, porous hydroxyapatite implants and teflon barrier membranes. *J Clin Periodontol.* 1991;18:605–10. (PubMed)
- [5] Kohad RM, Shetty S, Yeltiwar RK, Vaidya SN. A new synthetic hydroxyapatite – the right answer to bone regeneration. *J Ind Soc Periodontol.* 2001;4:6–11.
- [6] Jarcho M. Biomaterial aspects of calcium phosphates. Properties and applications. 1986;30:25–47. (PubMed)
- [7] Yukna RA, Krauser JT, Callan DP, Evans GH, Cruz R, Martin M. Thirty six month follow up of 25 patients treated with combination of anorganic bovine derived hydroxyapatite matrix (ABM) / cell binding peptide (P15) bone replacement grafts in human intrabony defects. I clinical findings. *J of Periodontol.* 2002;73:123–8. (PubMed)
- [8] Kreji CB, Bissuda NF, Farah C, Geenwell H. Clinical evaluation of porous and non –porous hydroxyapatite in the treatment of human periodontal bony defects. *J Periodontol.* 1987;58:521–8. (PubMed)
- [9] Nery EB, Lee KK, Czajkowski S, Dooner JJ, Duggan M, Ellinger RF, et al. A veterans administration cooperative study of biphasic calcium phosphate ceramic in periodontal osseous defects. *J Periodontol.* 1990; 61:737–44. (PubMed)
- [10] Galgut PN, Waite JM, Brook Shaw JP, Kingston CP. A 4- year controlled clinical study into the use of a ceramic hydroxyapatite implant material for the treatment of periodontal bone defects. *J Clin Periodontol.* 1992;19:570–7. (PubMed)
- [11] Chandradas ND, Ravindra S, Rangaraju VM, Jain S, Dasappa S. Efficacy of platelet rich fibrin in the treatment of human intrabony defects with or without

bone graft: A randomized controlled trial. J Int Soc Prev Community Dent 2016;6:S153-9.

- [12] Kothiwale SV, Anuroopa P, Gajiwala AL. A clinical and radiological evaluation of DFDBA with amniotic membrane versus bovine derived xenograft with amniotic membrane in human periodontal grade II furcation defects. Cell and tissue banking. 2009 Nov 1;10(4):317.
- [13] Venkatesan N, Lavu V, Balaji SK. Comparative Evaluation of Clinical and Radiological Parameters Following the Use of Biphasic Alloplastic Material With Amniotic Membrane/Collagen Membrane for the Management of Periodontal Intra-bony Defects—a Prospective Double Blinded Randomised Controlled Clinical Trial.
- [14] Shaila V. Kothiwale P. AnuroopaA. L. Gajiwala A clinical and radiological evaluation of DFDBA with amniotic membrane versus bovine derived xenograft with amniotic membrane in human periodontal grade II furcation defects. Cell and Tissue Banking 2009;10(4):317-26.
- [15] Kiany F, Moloudi F . Amnion Membrane as a Novel Barrier in the Treatment of Intrabony Defects: A Controlled Clinical Trial. Int J Oral Max Imp 2015;30:639–47.
- [16] Sali D, George.J. Demineralized Freeze Dried Bone Allograft With Amniotic Membrane in the Treatment of Periodontal Intrabony Defects - 12 Month Randomized Controlled Clinical Trial. J Periodontol 2016; 11:1-18.

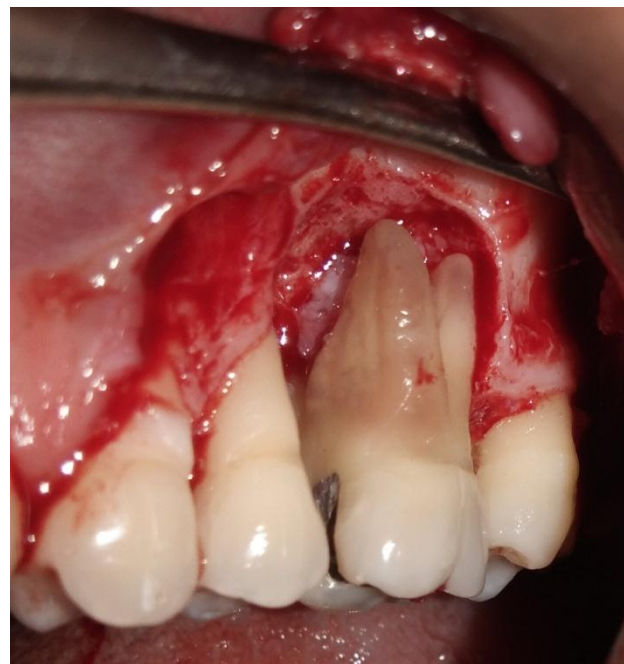

Figure 3: Clinical view of the defect in 26

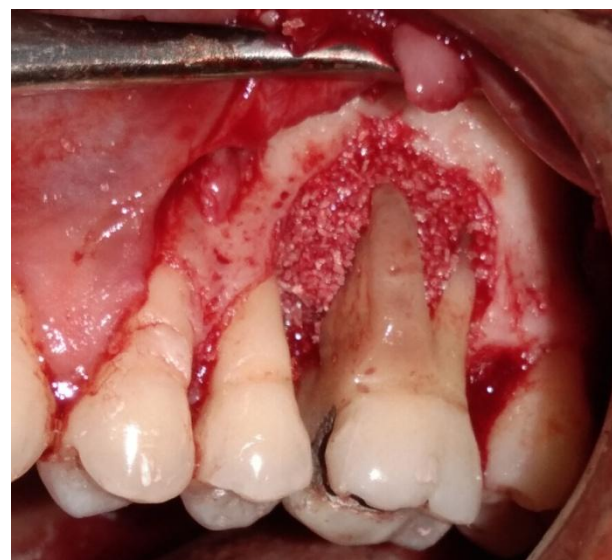


Figure 4: Bone Graft Placement

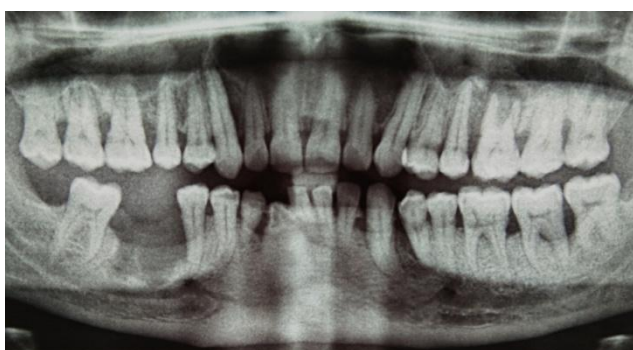

Figure 1: Preoperative radiographic view

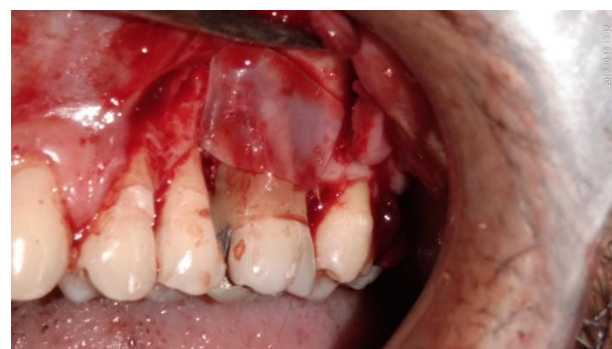

Figure 5: Healiguide Membrane placement

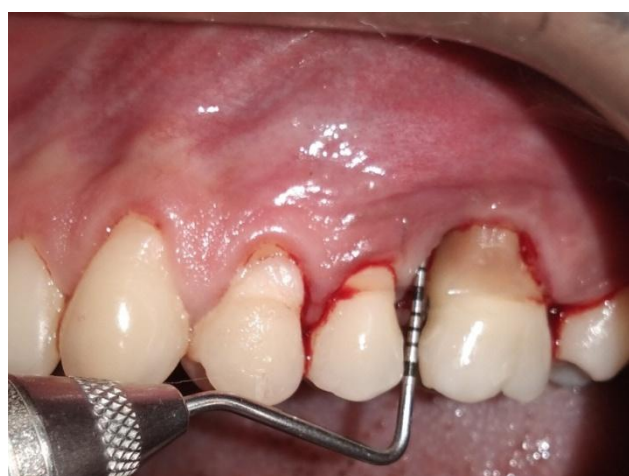

Figure 2: Clinical view - Baseline PPD evaluation

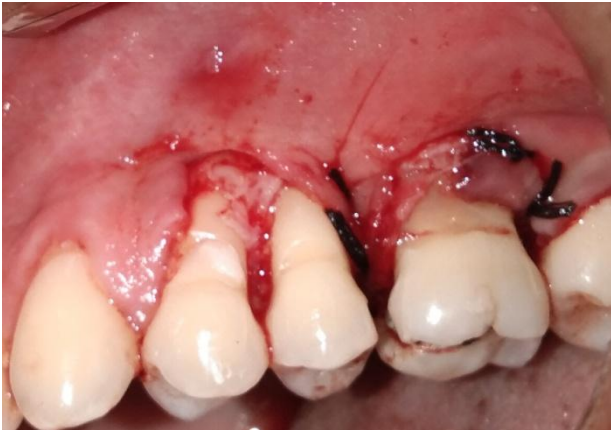

Figure 6: Suturing using 3-0 silk.

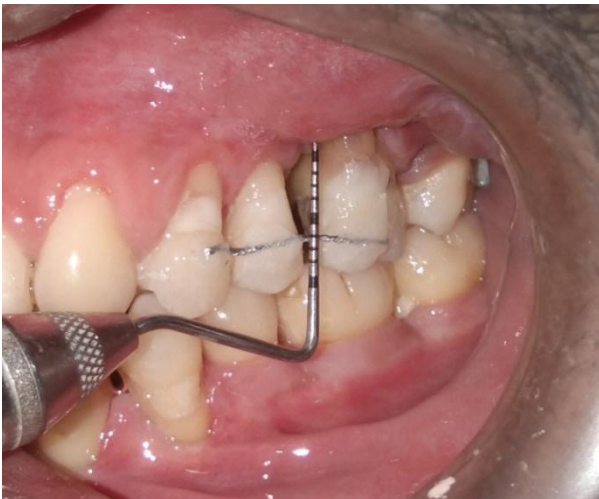


Figure 7: Reevaluation after 6 months showing reduction in PPD and gain in CAL

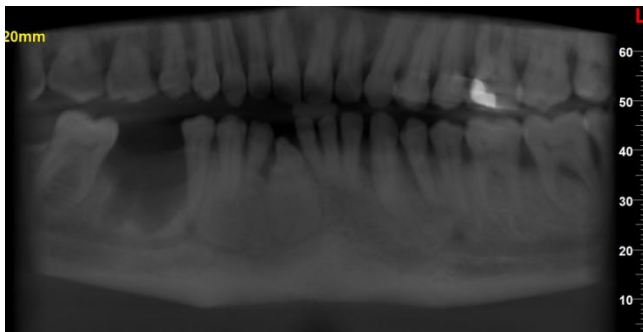


Figure 8: Postoperative six months radiographic evaluation showing bone fill in 26