

Functional Outcome of JESS External Fixator System for Distal End Radius Fractures

Dr. Janak Rathod¹, Dr. Parth Kinkhabwala²

¹Professor & Head of Department, Department of Orthopaedics, SMIMER, Surat, India

²Resident Doctor, Department of Orthopaedics, SMIMER, Surat, India (Corresponding Author)

Abstract: Background: Distal end radius fractures are the most common upper extremity fracture. The aim of the study was to assess the functional outcomes of distal end radius fractures managed with JESS external fixator in different age group. Material and Methods: A total of 30 patients with intra-articular distal end radius fracture were treated with Joshi's External Stabilization System from 2019 to 2020. The patients were followed up at 2 weeks, 8 weeks, 6 months and 1 year after the surgery. The assessment of pain, range of motion, grip strength and activity were assessed at 6th month and 1 year follow up and scored according to Green and O'Brien scoring system. Results: The good and/or excellent results were found in 80% of cases. We observed that patients with age less than 45 years had greater prognosis as compared to patient with more than 45 years of age. Final outcome was also found better in males as compared to females at 6 month and 1 year post operatively. Conclusion: JESS is a cost-effective technique and a good option for displaced distal end radial fractures.

Keywords: Distal end Radius Fractures, JESS External Fixator, Joshi's External Stabilizing System

1. Introduction

Distal end radius fractures are the commonest fractures [1-3]. Increasing incidence of these injuries may be attributed to an ageing population (osteoporotic fractures) and the growing participation in outdoor pursuits (higher energy fractures) [4, 5]. Whereas a large number of these fractures are managed nonoperatively, the number of patients who undergo surgical management is considerable. Displaced fractures are treated surgically by various methods like percutaneous pin or screw fixation, open reduction, and internal fixation with plate and screw, locking plate and screw fixation, and intramedullary nailing and external fixation.

Illizarov in 1960[6] proposed the biologic law of tissue histogenesis of bone, muscle, nerve, and skin occurring when the tissues are put to stretch gradually. But the fixators he used were constrained, bulky, using tensioned wires, needing enough strength in the bones to hold them and technically demanding. On the same principle Joshi et al. devised a simple external fixator (Joshi's external stabilization system [JESS]), in the early 1990s which is cost effective, easily applicable, light weight, and needs minimum number of instruments for application [7-9]. Since then it has been used for treatment of post-burn contractures of the hand and wrist [10], interphalangeal joint contractures in leprosy[11], intra-articular distal radial fractures[12], idiopathic clubfoot [13], hand trauma and its sequelae [14], calcaneal fractures[15], and Congenital Talipes Equinovarus [16,17].

The present study was conducted to study the functional outcome of patients treated with JESS for displaced distal end radius fractures.

2. Material and Methods

This study was performed between 2019 and 2020 on patients with displaced distal end radius fractures visited at Department of Orthopaedics, SMIMER, Surat. Patients with any other associated injury/fracture, bilateral distal radius fractures, open fractures of distal radius and associated head injury were excluded from the study. Written informed consent was taken from all the patients.

Joshi's External Stabilization System: JESS Distractor is a system based on ligamentotaxis of distal end radius fractures management. JESS consists of application of total of 4 pins in radius and 2nd metacarpal connected by serrated connecting rod with provision for distraction. 1st two 3.5 mm Schanz pins were applied in radius 2-3 cm proximal to fracture. Then two 2.5mm Schanz pins are applied in 2nd metacarpal through JESS distractor holes. All the pins were checked under image intensifier. Distraction and acceptable reduction was achieved and confirmed in image intensifier.

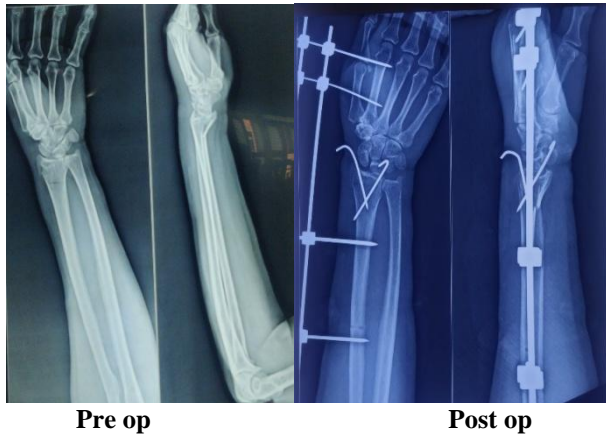
Guidelines for acceptable closed reduction taken were [18]:

- 1) Radial inclination: greater than or equal to 15 degrees
- 2) Radial length: less than or equal to 5 mm shortening
- 3) Radial tilt: less than 15 degrees dorsal or 20 degrees volar tilt
- 4) Articular incongruity: less than 2 mm of step-off

All the screws and clamps were tightened and stability checked. Post op Xray was taken. Patient was given IV Antibiotics for 1 day and oral for 5 days. Active finger mobilization was started 1st post op day. Patient was discharged on 3rd day and pin tract care was explained to patient. Patient was followed up at 2 weeks to check for pin tract discharge or loosening. At 8 weeks postop X-ray was taken and then distractor removal was done. Then follow up was done at 6 months and 1 year to check for progress and

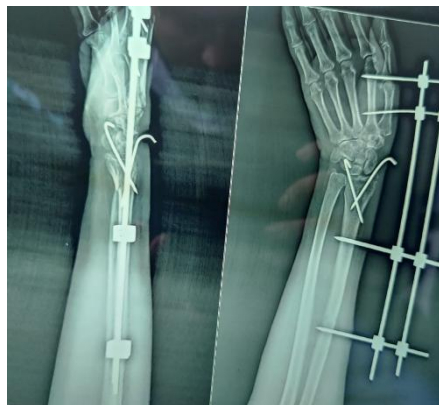
final outcome. Outcome of patient was assessed using Green and O'Brien Scoring system at 6th month and 1 year post op. **The final score of 80-89 was considered as good results and 90-100 were considered as excellent results.**

Statistical analysis: All the data were analyzed using SPSS(Statistical Package for the Social Sciences) 20. The scores at 6th month and 1 year were compared using two-sided paired sample t test. Score in different age groups and gender were compared using student t test. P value less than 0.05 were considered as significant.

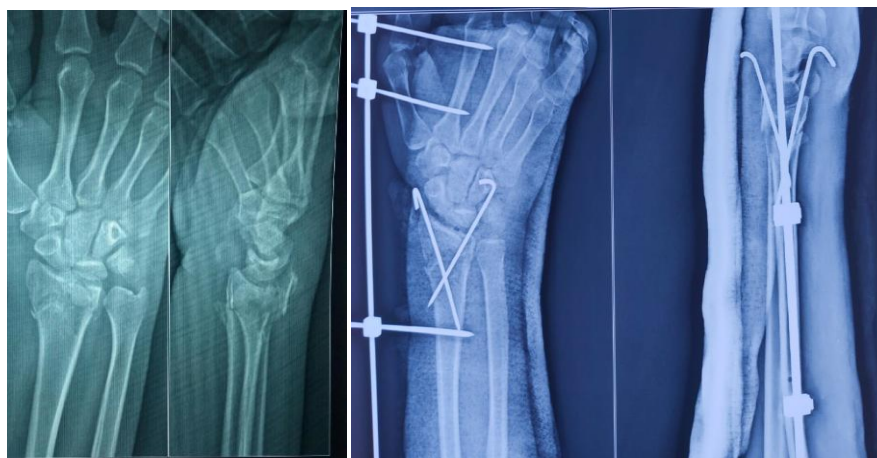

Pre op

Post op



1 month follow up



Pre op

Post op

The mean post-operative final Green and O'Brien Score as assessed at 6 month was 65.5 ± 21.9 in females and 83.44 ± 12.79 in males (P value < 0.0001). Both females and males showed significant improvement in function over the

3. Results

A total of 30 patients of displaced distal end radius fracture were treated with JESS during the study period. Out of 30 patients 16(55.6%) were female and 14(44.4%) were male. The mean age of patients was 40.07 ± 13.37 years. Mean interval between injury and surgery was 2.5 days. The average operative time was 32 minutes (range: 25–46 minutes). Mean duration of JESS application was 8 weeks. Mean time of radiological union was 8 weeks. Two patients developed Pin tract infection which was managed successfully by antibiotic treatment. Swelling, inflammation and occasional pain was observed in 4 patients.

The good and/or excellent results were found in 80% of cases. There was significant decrease in pain and increase in range of motion (ROM), grip strength and activity at 1 year when compared to 6 months.

We compared the scores between two different age groups (Group 1 with less than 45 year and group 2 with more than 45 years). We observed that the only 54.2% of patient in group 2 had good or excellent result as compared to 86.6% in group 1. We observed there was significant difference in Pain, ROM, Grip Strength, activity and final score in these two groups.

1-year follow-up (P < 0.0001). At 1 year, the mean score was 79.5 ± 14.92 in females as against 93.28 ± 7.68 in males.

	At 6 months	At 1 year	P value	95% Confidence Interval of the Difference	
				Lower	Upper
Pain	19.17±5.56	21.67±3.56	0	-3.506	-1.494
ROM	16.53±6.85	21.46±5.13	0	-6.185	-3.676
Grip Strength	16.67±5.93	19.72±5.81	0	-4.033	-2.078
Activity	21.11±5.05	22.78±2.89	0	-2.549	-0.785
Final Score	73.47±20.42	85.36±13.99	0	-14.855	-9.45

4. Discussion

Different types of fractures may occur due to the anatomy of the distal radius and the effects of forces in different directions. It is not feasible to have a successful outcome using the same approach and materials for different types of fractures [19].

Many external fixation devices are described to achieve reduction and fixation of the fragments without loss of position and acceptable functional results [20]. The ligamentotaxis is the basic principle used by external fixation [21]. Prolonged rigid immobilization of the wrist in an external fixator leads to decreased blood supply to bone and soft tissues and causes periarticular fibrosis. This leads to osteoporosis, poor motion, and compromised functional outcome. Often, intense physiotherapy is required to rehabilitate these patients [22].

The early mobilization of the wrist leads to normalization of blood supply, hastened functional recovery, earlier resolution of wrist swelling, and decreased joint stiffness [23]. The dynamic external fixators have been developed to provide mobilization of the wrist while reduction and fixation are maintained [22]. JESS fixator application in our study allowed sound fracture union with functional mobility in our study. Our study reflects a typical experience from the semi urban parts of India where different patient factors have to be considered when choosing the best available treatment. Treatment advised should be based on the best evidence, however patient preferences and cost effectiveness should be considered in choosing the final treatment. Our results shows good and/or excellent results were found in 86.6% of cases with age less than 45 years. In conclusion JESS is a good option in patients with displaced distal end radial fractures.

References

- [1] Jupiter JB: Fractures of the distal end of the radius. *J Bone Joint Surg Am* 1991, 73:461-9.
- [2] Lichtman DM, Bindra RR, Boyer MI, Putnam MD, Ring D. Distal radius work group: The treatment of distal radius fractures. *J Am Acad Orthop Surg* 2010, 18:180-189.
- [3] Handoll HH, Huntley JS, Madhok R: External fixation versus conservative treatment for distal radial fractures in adults. *Cochrane Database Syst Rev* 2007, 18(3):CD006194.
- [4] Knirk JL, Jupiter JB. Intra-articular fractures of the distal end of the radius in young adults. *J Bone Joint Surg Am*. 1986; 68:647-59.
- [5] Jupiter JB, Ring D, Weitzel PP. Surgical treatment of re-displaced fractures of the distal radius in patients older than 60 years. *J Hand Surg Am* 2002; 27:714-23
- [6] Wallander H, Hansson G, Tjernstrom B. Correction of persistent clubfoot deformities with the Ilizarov external fixator. Experience in 10 previously operated feet followed for 2-5 years. *Acta Orthop Scand* 1996; 67: 283-7.
- [7] Kristiansen B, Kofoed H. Transcutaneous reduction and external fixation of displaced fracture of proximal humerus. A controlled clinical trial. *J Bone Joint Surg Br* 1988; 70:821-24.
- [8] Patil YM, Patil AB, Balemane S. A prospective study to study the surgical outcomes in three- and four-part proximal humerus fracture with PHILOS plate. *J Sci Soc* 2012; 39:12-6.
- [9] Gupta AK, Gupta M, Sengar G, Nath R. Functional outcome of closed fractures of proximal humerus managed by Joshi's external stabilizing system. *Indian J Orthop* 2012;46:216-20.
- [10] Gulati S, Joshi BB, Milner SM. Use of Joshi External Stabilizing System in postburn contractures of the hand and wrist: a 20-year experience. *J Burn Care Rehabil* 2004;25:416-20.
- [11] Salafia A, Chauhan G. Joshi External Stabilising System (JESS) in proximal interphalangeal joint (PIP) contractures in leprosy. *Indian J Lepr* 1997;69:331-9.
- [12] Thomas S, John C, Johnny TP. Intra-articular distal radial fractures: external fixation or conventional closed reduction. *J Orthop* 2007;4:e39.
- [13] Suresh S, Ahmed A, Sharma VK. Role of Joshi's external stabilisation system fixator in the management of idiopathic clubfoot. *J Orthop Surg (Hong Kong)* 2003; 11:194-201.
- [14] Joshi BB. Joshi's external stabilization system (JESS): a simple mini external fixator for the management of hand trauma and its sequels. *Injury* 1997; 28:244.
- [15] Singh A, Srivastava RN, Jah M, Kumar A. Ligamentotaxis for complex calcaneal fractures using Joshi's external stabilization system. *Indian J Orthop* 2008; 42:330-5.
- [16] Joshi BB, Laud NS, Warriar S, Kanaji BG, Joshi AP, Dabake H. Treatment of CTEV by Joshi's external stabilization system (JESS). In: Kulkarni GS, editor. *Textbook of orthopaedics and trauma*, 1st ed. New Delhi: Jaypee Brothers Medical Publishers; 1999.
- [17] Anwar MH, Arun B. Short term results of correction of CTEV with JESS distracter. *J Orthop* 2004; 1: e3.
- [18] Graham TJ. Surgical correction of malunited fractures of the distal radius. *J Am Acad Orthop Surg*. 1997;5:270-281
- [19] Wolfe SW. Patterns and treatment of distal radius fractures. In: *Proceedings of the AAOS/ASSH update on the painful and injured wrist*. May 29-30, Rosemont, IL; p. 66. 2009
- [20] Jhonsson U. External fixation for re-dislocated Colles' fractures. *Acta Orthop Scand* 1983;54:878-83
- [21] Schuind F, Cooney WP 3rd, Burny F, An KN. Small external fixation devices for the hand and wrist. *Clin Orthop Relat Res* 1993; 293:77-82
- [22] Clyburn TA. Dynamic external fixation for comminuted intra-articular fractures of the distal end of the radius. *J Bone Joint Surg Am* 1987; 69:348-54.

- [23] Müller ME, Allgöwer M, Schneider R, Willenegger H. In: Manual of Internal Fixation: Techniques Recommended by the AO Group. 2nd ed. Berlin: Springer-Verlag; 1979