

The Selective Grinding Prosthetic Feeding Aid (PFA) Frequency Influence towards Cleft Distance and Premaxilla Angle of Infants with Unilateral Complete Cleft Lip and Palate

Damayanti, Lisda¹, Rikmasari, Rasmi², Alamsyah, G. N.³

^{1, 2, 3}Universitas Padjadjaran, Faculty of Dentistry, Sekeloa Selatan1, Bandung, Indonesia

Abstract: *The purpose of the research is to analyze the selective grinding frequency influence towards cleft distance and premaxilla angle of infant with unilateral complete and cleft lip palate with the use of Prosthetic Feeding Aid (PFA). Method: 10 infant with unilateral complete and cleft lip palate with wide alveolar cleft and premaxilla rotate position installed with PFA. Impression is done twice to each subject before and after PFA care. Pictures taken from each work model results. Tracing was made on sample pictures that was taken using the assigned postulate spots PhotoQuad program. Adjustment towards the device is done twice a week using selective grinding to the acrylic anatomy surface on the palatolateral major detector and anteromedial minor defect and relining soft liner process on the labial surface. Anatomy surface selective grinding is not exceed 1-1.5 mm on every visit. The analyze of the linkage between selective grinding frequency PFA with cleft distance and premaxilla angle using linkage test by counting person correlation coefficient. Result: the linkage analysis between selective grinding prosthetic feeding aid frequency with cleft distance premaxilla angle of infant with unilateral complete and cleft lip palate is there are positive linkage correlation in the amount of 41% or $r = 0.641$ that is not statistically significant with $t\text{-count} = 2,36$ or $p\text{ value} = 0,046 < 0,05$. The linkage analysis between selective grinding prosthetic feeding aid frequency with infant with unilateral complete and cleft lip and palate is there are positive linkage correlation in the amount of 23% or $r = 0.479$ that is not statistically significant with $t\text{-count} = 1.544$ or $p\text{ value} = 0.1611$. Conclusion: the more frequent of the selective grinding prosthetic feeding aid, the smaller the cleft distance and premaxilla angle.*

Keywords: Unilateral Complete Cleft Lip and Palate, Selective Grinding, Prosthetic Feeding Aid, Cleft Distance, Premaxilla Angle

Preliminary

Cleft lip and palate is a condition where lips and oral palate is not perfectly merge in one side so there's a distance between both sides. Unilateral complete and cleft lip palate involving a hard palate, soft palate, alveolar ridge and lip on one side.1 Maxilla segment on unilateral complete cleft lip will split in two parts, minor segment on the clefted side, and major segment on the unclefted side[1],[2].

Infant with cleft lips and a complete unilateral palate have an asymmetry face caused by deviation from the nasal tip. The nasal tip is deformed and become flat. Besides that, the premaxilla will rotate to the outside[2],[3]. The minor segment of maxilla will experience a hypoplastic and retroposition, furthermore filtrum and columella will be retracted on one side and tilted on the unclefted side. The orbicularis oris muscle is disconnected on the cleft lip tip. The alar on the clefted side will be sunken and pulled horizontally [2],[3],[4].

Infant with cleft lips and palate will experience difficulties to get a nutrition because the clefted anatomy structure, that's why the Prosthetic Feeding Aid (PFA) construction is needed. PFA is a device that is used for the patient with cleft lip or no palate before the cleft unification surgery.

The advantage of PFA use:[2],[5]

- 1) The cleft width reduction using palate stimulation growth.
- 2) Increase of the maxilla curve growth.
- 3) Increase of face and infant growth.

- 4) Increase of occlusion, breast milk drinking, speaking, and hearing growth.
- 5) The oral cavity tissue development and growth, like maintain the tongue in a god position.

Plat Hotz is a passive type orthopedic plat that align the cleft segment with the help of strapping and the use of plaster slowly. This device was made from the combination of hard and soft acrylic. It covers the alveolar segment passively and elongating on the posterior part toward the uvula cleft tip. This plat is giving a good adaptation in creating a normal swallowing pattern. It is used for 24 hours every day and only removed when it's cleaned [6].

On the la kogo design, the 2 mm acrylic elevation was made on the posterior plat. The elevation plays a role in forming a close box. Hotz Kogo design modification is a combination from mechanical palatal posterior enhancement and elongation to the cleft on uvula where the design assimilation producing the more maximum positive effect on the baby with cleft lip and palate[7].

Selective Grinding Prosthetic Feeding Aid

Prosthetic Feeding Aid (PFA) should have a good adaptation and retention on the baby's oral cavity. The baby observed for a few minutes after the device installation. Baby must be able to suck without feeling nausea and stertorous. After the observation the device can be used for one week for first phase adaptation [8]. On the adjustment phase, anatomy surface is modified so that the growth of alveolar major and minor segment can be directed. The purpose of the

modification is to reduce cleft width and draw closer the alveolar major and minor segment so that the maxilla's curve formed well[8].

Expected movement from PFA care is the major segment move to palatal and minor segment move towards the major segment. The modification series that was done by PFA are selective grinding and soft liner relining as in figure 1. Selective grinding process is done on major segment palatal part of the PFA anatomy surface and on the labial part of minor segment PFA anatomy surface. Soft liner relining is done on major segment PFA anatomy surface for about 1-1.5 mm[8].

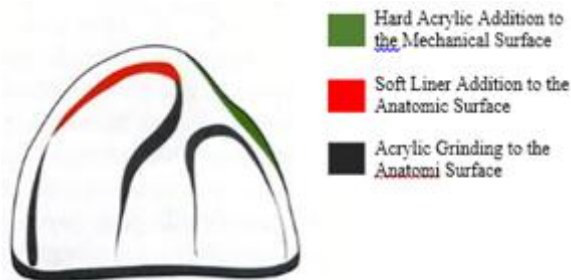

Figure 1: Prosthetic Feeding Aid anatomy surface modification [8]

Ingredients and Methods

Research was done on 10 infant patients with unilateral complete and cleft lip palate with the inclusion criteria as follows: infant that are old enough (more than 37 weeks old), minimum weight 2500 gram, born with good general circumstances based on pediatricians referrals.

Research was done in a few visit phase starting from the preliminary examination, printing phase, PFA construction, installation, selective grinding process every control and the printing phase before labioplasty.

Work model before the care and before labioplasty was done by taking pictures using Digital Nikon Coolpix L340 camera. The camera is attached on the tripod and positioned perpendicularly to work model with a 30 cm design and the model was placed on a pad with 7 cm ruler to calibrate every pictures of work model. The photo calibration technic will convert pictures scale (pixel) into the real distance in metric units (cm), calibration was done by placing calibration point on the 2 spots that distance is already known. Tracing was made on every sample pictures by using PhotoQuad of the benchmark points determination used. The linear measurement to get alveolar cleft width that measured from A-A' using centimeter units (cm). Angular measurement to see major alveolar segment which was measured from the nook that created from mid sagittal field and the line through point I. The result of angular measurement will be in degree units (°). Every model study measurement's result phase I and phase II before labioplasty was recorded, complete with selective grinding frequency calculation from every model in every visit. Each data result measurement was recorded and analyzed.




Figure 2 : Tracing photo using PhotoQuad program. A, the most lateral point from major segment; A', the most medial point from minor segment; I, papilla insivisis; T, tubermaxilaris point from minor segment; AA', cleft distance; TT', intertubermaxilaris line.

Result

Research was done to 10 infant with unilateral complete and cleft lip palate according to clinical medic examination including extra oral and intra oral and diagnosis.

Table 1: Cleft Lips and Complete Unilateral Palate Research Sample Characteristic

Gender	Sample Group			
	Number		Age (days)	Weight (Kg)
	n	%	range	range
Male	3	30%	3-15	2.2-3.3
Female	7	70%	9-49	2.5-4.1
Amount	10	100%		

The calculation linkage between selective grinding prosthetic feeding aid (PFA) with premaxilla position change were done according to linkage trial statistic calculation by calculate pearson coefficient and correlation.

Table 2: Selective Grinding Prosthetic Feeding Aid Frequency Linkage with Cleft Distance Resregion Analysis

Selective Grinding Prosthetic Feeding Aid Frequency Linkage with Cleft Distance Resregion Analysis	
r^2	0.410
<i>Adjusted r²</i>	0.337
<i>r</i>	0.641
<i>Std. Error</i>	0.265
10	<i>observations</i>
1	<i>predictor variable</i>
Premaxilla Position Change	<i>is the dependent variable</i>
Cleft Distance Change Resregion Model: $Y_1 = 0.0538 + 0.0971 F$ with: $Y_1 =$ Cleft Distance Change $F =$ Selective Grinding Prosthetic Feeding Aid Frequency	

In this linkage analysis there is a linkage with positive correlation about 41% or $r = 0.641$ that statistically significant with t count = 2.36 or p value = 0.046 < 0.05. The linkage correlation is positive which means the more often selective grinding Prosthetic Feeding Aid the bigger the cleft distance change.

Table 3: Selective Grinding Prosthetic Feeding Aid Frequency Linkage with Premaxilla Angle Regression Analysis

Selective Grinding Prosthetic Feeding Aid Frequency Linkage with Premaxilla Angle Regression Analysis	
r^2	0.230
Adjusted r^2	0.133
r	0.479
Std. Error	5.021
10	observations
1	predictor variable
Premaxilla Position Change	is the dependent variable
Premaxilla angle change regression model: $Y_1 = 0.0808 + 1.2019 F$ with: $Y_1 =$ Premaxilla Position Change $F =$ Selective Grinding Prosthetic Feeding Aid Frequency	

In this linkage analysis there is a linkage with positive correlation about 23% or $r = 0.479$ that statistically significant with t count = 1.544 or p value = 0.1611. The linkage correlation is positive which means the more often selective grinding Prosthetic Feeding Aid the bigger the premaxilla position change.

Discussion

Infant with unilateral complete and cleft lip palate, the upper jaw curve is divided into two segment, major segment and minor segment, and involving a soft palate, hard palate, and alveolar ridge [9]. On this condition premaxilla segment is pushed to the anterior, in its development premaxilla will be more prominent and wide due to the muscle pull around the mouth when it is functioning [10].

Pollastri et al.[11] and research result shows that the use of Prosthetic Feeding Aid (PFA) to the patients with cleft lips and palates is playing role in preventing maxilla segment shifted to the lateral and directing maxilla segment to the desired position.

The analysis result was due to the two maxilla segment that separated and the lip muscle of the condition, there was an unbalance muscle pull on the tissue around baby's mouth. Furthermore, this causing maxilla segment rotating, the asymmetry nasal septum, and widen cleft.

The uses of PFA will keep the maxilla segment not shifted when the muscle pulls. When doing control, selective grinding is done on the medial and palatal from major and minor segment. Also doing relining and soft liner on the anterior at the same time. This is causing the appearance of orthopedic force on the labial of the maxilla major segment and pushing major segment towards palatal. On the area where grinding process was done there is an empty space on the palatolateral that become a place where major segment is sliding. The grinding process was done for 1 until 1.5 mm. According to Grayson et al. [12] selective grinding is done every week for 5 until 1 mm. The excessive grinding process will affecting PFA retention and too much pressure from

relining soft liner will causing the tissue to receiving too much pressure and in the end causing injury to oral mucosa.

The orthopedic force from relining will cause the premaxilla to return to its correct arch. After the premaxilla in the correct arch and the major and minor maxilla is close, labioplasty can be done.

Conclusion

The more often selective grinding prosthetic feeding aid frequency, the smaller the distance between premaxilla cleft and angle and midsagittal field of infant with unilateral complete and cleft lip palate.

References

- [1] Allori AC, Mulliken JB, Meara JG, Shusterman S, Marcus. Classification of cleft lip/palate: then and now. *Cleft Palate Craniofac J* 2016;53(1):1-14.
- [2] Puri T, Patel D. Presurgical nasoalveolar molding in patients with unilateral and bilateral clefts-changing concepts and current approach. *J Cleft Lip Palate Craniofac Anomal* 2015;2:98-104.
- [3] Malek R. Cleft lip and palatelesion, pathophysiology and primary treatment. France: Martin Dunitz; 2013 . Chapter 6, Pathological anatomy. [cited2016 sept25]. Available from: https://69c0f8f27bfcd108a2643d799abab449113c3006.googledrive.com/host/0BygdC_1BxbDyTWFhdDhjbDZzZkU/Cleft-Lip-Palate-Pathophysiology-Treatment-1853174912.pdf
- [4] Patel D, Goyal R, Puri T. Presurgical nasoalveolar molding-an adjunct to facilitate surgical repair in infants with cleft lip and palate. *Modern Plastic Surg* 2013;3:34-42.
- [5] Vinson LA. Presurgical orthopedics in cleft lip and palate care. *Open J Dent and Oral Med* 2016;4(1):14-9.
- [6] Seibert RW, Bumsted RM. Cleft lip and palate. 2nd ed. St Louis: Mosby. 2007.p.1128-64.
- [7] Kogo M, Okada G, Ishii S, Shikata M, Iida A, Matsuyo T. Breast feeding for cleft lip and palate patients, using the hotz-type plate. *Cleft Craniofac J* 1997;34(4):351-2.
- [8] Taylor TD. Clinical maxillofacial prosthesis. Illinois: Quintessence Inc.2000. p.67-8,71.
- [9] Smith HW. The atlas of cleft lip and palate surgery. New York:Grone and Stratton Inc. 1983. p.50-1.
- [10] Ortiz-Monasterio F, Serrano A, Barrera G, Rodriguez-Hoffman H, Vinageras E. A study of untreated adult cleft palate patients. *Plast & Reconstruct Surg* 1966; 38(1):36-41.
- [11] Pollastri G, Sticco E. Analysis of morphological variations of the maxilla in unilateral complete cleft and palate after presurgical orthopedic treatment by a functional obturating plate. *Stomatol J* 2000;49:13-20.
- [12] Grayson BH, Santiago PE, Brecht LE, Cutting CB. Presurgical nasoalveolar molding in infants with cleft lip and palate. *Cleft Palate Craniofac J* 1999;36:486-98.

Attachment 1
Before and After Prosthetic Feeding Aid Treatment Measurement Results

Subject	Cleft Side	Treatment Beginning Age (days)	Labioplasty Reference Age(days)	Selective Grinding Frequency	Premaxila Angle(in degree)		Cleft Distance (in mm)	
					Before	After	Before	After
1	Left	49	110	5	14.9	8.1	1.2	0.4
2	Right	10	72	2	26.3	26.2	1.1	1
3	Left	19	89	4	34.7	17.3	1.6	1.1
4	Left	15	117	7	17.1	12.7	1.5	0.4
5	Right	22	111	9	33.6	22.3	1.6	1.1
6	Left	9	97	5	12.8	9.5	1.2	0.4
7	Left	10	115	4	16.4	13.7	0.8	0.6
8	Left	3	108	4	17.2	13.7	1.4	0.9
9	Right	9	89	2	26.2	26	1.3	1.2
10	Left	15	140	6	23.3	14.5	1	0.4

