

# A Prospective Observational Study to Describe the Clinical Profile, Diagnosis and Prognosis of Cerebral Sinus Venous Thrombosis

Dr. Marla Ashok Kumar, M.D

Assistant Professor, Department of General Medicine, Gandhi Medical College

**Abstract:** Cerebral sinus venous thrombosis (CSVT) is an uncommon condition. Its clinical presentation is varied and often dramatic. It often affects young to middle-aged patients, and more commonly women. Important clinical features to suggest this disorder are presentation with recent headache, seizures, papilloedema and focal deficits in the appropriate clinical settings. Management with unfractionated heparin, LMWH and oral anticoagulation is appropriate. Surgical decompression is helpful in the case of continuing deterioration, inspite of maximum medical management.

**Keywords:** CSVT Cerebral sinus venous thrombosis CT Computed tomography CTV Computed tomography venography CVT Cortical venous thrombosis DWI Diffusion weighted imaging

## 1. Introduction

Cerebral sinus venous thrombosis (CSVT) is an uncommon condition. Its clinical presentation is varied and often dramatic. It often affects young to middle-aged patients, and more commonly women. Although recognized for more than 100 years, it has only in recent years come to be diagnosed frequently ante-mortem. The annual incidence is currently estimated to be 3-4 cases per 1 million people. 3 out of 4 people with CSVT are women. It accounts for 10-20 % of the etiology of young strokes in India.

CVST most commonly involves superior sagittal sinus (72%) followed by lateral sinus (70%). In 30 to 40% of cases more than one sinus is involved. The diagnosis of CVST requires high index of suspicion because of its varied presentations.

Neuroimaging is the corner stone in the diagnosis of cerebral venous sinus thrombosis. Imaging modalities of choice in CVST are CT scan and MRI with MR venogram. CT scan may be normal in 15-30% cases but MRI with MRV is almost 100% diagnostic.

CVST has an acute case fatality of less than 5% and almost 80% of patients recover without sequelae. It has been found that early diagnosis of cerebral venous thrombosis is essential because early treatment may prevent morbidity and may even be life saving.

## 2. Objectives

To study the clinical profile and radiological features in cerebral venous thrombosis.

## 3. Patients & Methods

**Type of Study:** A prospective study over 80 patients with confirmed diagnosis of cerebral sinus venous thrombosis.

**Duration of Study:** This study was carried out on patients who were admitted in department of General Medicine,

Gandhi Hospital, Secunderabad during a period of January 2015 to October 2016.

### Inclusion Criteria

All patients aged >18 years suspected to have cerebral venous thrombosis based on clinical history and examination were evaluated but only those with confirmed diagnosis (based on neuroimaging) of cerebral venous sinus thrombosis were taken up for the study.

### Exclusion Criteria

- Hypertensive haemorrhage
- Atherothrombotic stroke
- Metabolic encephalopathies

## 4. Observation & Results

A total of 80 cases of cerebral sinus venous thrombosis were evaluated in the present study.

- 1) The mean Majority of them youngest being 18 age of the patients in the present study was  $29.8 \pm 8.7$ . were in the age group of 18-30 contributing to 67.5 %.
- 2) Male:Female ratio in our study was 2:3.
- 3) The mean age of female patients is 26.62 with a standard deviation of 5.6, where as that of male patients mean age is 34.62 with standard deviation of 10.18 in the present study.
- 4) Those who presented within 48 hours were considered to have acute onset, with onset longer than 48 hours but less than 1 month were considered subacute, and with onset more than 1 month as chronic (Boussier et al, 1985).

In the present study, 38 cases (47.5%) of CSVT had subacute presentation, followed by 30 cases (37.5%) with acute presentation.

- 5) In the present study, 42 patients (52.5%) were conscious and 18 patients (22.5%) were drowsy at the time of presentation.
- 6) In the present study, most common symptom is headache present in 85%. (68 cases) followed by convulsions in 65% (52 cases).

Volume 6 Issue 5, May 2017

[www.ijsr.net](http://www.ijsr.net)

Licensed Under Creative Commons Attribution CC BY

- 7) In the present study, hemiparesis was present in 40%, papilloedema in 40% and Dysphagia in 17.5% of patients.
- 8) In the present study, out of 80 patients, 26 were anemic, accounting for 32.5% and the mortality was higher when the degree of anaemia was severe.
- 9) In the present study, 44 cases (55%) had haemorrhagic infarction, followed by non-hemorrhagic infarction comprising 36 cases (45%).
- 10) 22 patients were subjected to CSF analysis wherever there was suspicion of meningitis, out of which 14 were normal and pleocytosis seen in 8 patients and protein rise in 4 patients.
- 11) In the present study, the most common sinus involved was superior sagittal sinus in 56 patients accounting to 70% followed by transverse sinus (42.5%) in 34 patients.

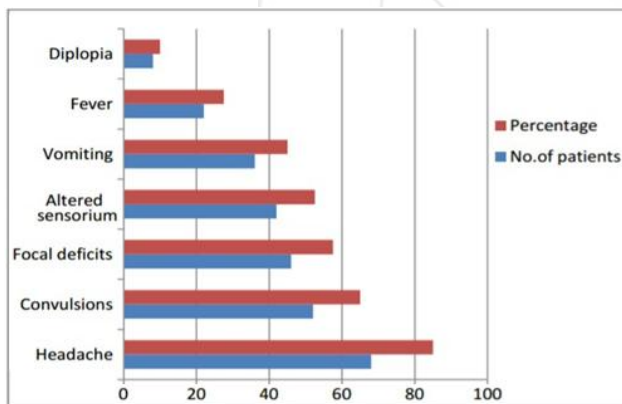
and long term outcomes when the acute phase of illness has been survived.

## References

- [1] Bousser MG. Cerebral venous thrombosis: nothing, heparin or local thrombolysis. *Stroke*,1999;30:481-3.
- [2] Lath R, Kumar S, Reddy R, Boola GR, Ray A, Prabhakar S, Ranjan A. decompressive surgery for severe cerebral venous sinus thrombosis. *Neurol India* 2010;58:392-7.
- [3] Ameri A, Bousser MG. Cerebral venous thrombosis. *NeurolClin*, 1992.10:87-111.
- [4] Villringer A, Mehraen S, Einhüpl KM. Pathophysiological aspects of cerebral sinus venous thrombosis. *J Neuroradiol*, 1994. 21:72-80.
- [5] Bousser MG, Chiras J, Bories J, Castagne P. Cerebral venous thrombosis - a review of 38 cases. *Stroke*, 1985;16:199-213.
- [6] Bousser MG, Barnett HJM. Cerebral venous thrombosis. In: stroke: pathophysiology, diagnosis and management, 4th edition. New York. ChurchillLivingstone, 2004;300-21.
- [7] Wang AM. MRA of venous sinus thrombosis. *ClinNeurosci* 1997;4:158-64.
- [8] Nagaraja D, Sarma GR. Treatment of cerebral sinus/venous thrombosis. *Neurol India* 2002;50:114.

**Table 6:** Initial symptoms at presentation

Symptom	No. of patients	Percentage
Headache	68	85
Convulsions	52	65
Focal deficits	46	57.5
Altered sensorium	42	52.5
Vomiting	36	45
Fever	22	27.5
Diplopia	8	10



**Graph 6:** Initial symptoms at presentation

## 5. Conclusions

- Clinical presentation is extremely varied and symptoms may evolve over hours to few weeks.
- Important clinical features to suggest this disorder are presentation with recent headache, seizures, papilloedema and focal deficits in the appropriate clinical settings.
- Neuroimaging plays a pivotal role in diagnosis. MRI with MRV is the current diagnostic modality of choice.
- Management with unfractionated heparin, LMWH and oral anticoagulation is appropriate. surgical decompression is helpful in the case of continuing deterioration, inspite of maximum medical management.
- Contrary to ischemic arterial stroke, CSVT could be described as an 'all or nothing' disease with good short