

# Comparative Study of Pterygium Excision Using Conjunctival Autograft and Amniotic Membrane

Mudasir Zahoor<sup>1</sup>, Imtiyaz Ahmad Lone<sup>2</sup>, Nusrat Shaheen<sup>3</sup>, Reyaz A Untoo<sup>4</sup>

<sup>1</sup>Post-Graduate scholar, Post-Graduate Department of Ophthalmology, Sher-i-Kashmir institute of Medical Sciences Medical College, Srinagar, India

<sup>2</sup>Associate Professor, Post-Graduate Department of Ophthalmology, Sher-i-Kashmir institute of Medical Sciences Medical College, Srinagar, India

<sup>3</sup>Assistant Professor, Post-Graduate Department of Ophthalmology, Sher-i-Kashmir institute of Medical Sciences Medical College, Srinagar, India

<sup>4</sup>Professor & Head, Post-Graduate Department of Ophthalmology & Principal, Sher-i-Kashmir Institute of Medical Sciences Medical College, Srinagar, India

## Address for Correspondence

**Imtiyaz Ahmad Lone**

Associate Professor, Post-Graduate Department of Ophthalmology, Sher-i-Kashmir Institute of Medical Sciences Medical College, Srinagar, India

E mail: imtiyazalone[at]yahoo.co.in

**Abstract:** ***Aim:** To compare the recurrence rate of pterygium after excision with free conjunctival autograft versus amniotic membrane graft. **Methods:** The present study was a comparative, randomised prospective study. One hundred patients who presented with primary pterygium during the study period were randomly assigned to one of the two groups- one group (comprising of 50 patients) underwent pterygium excision with conjunctival autograft and the other group (comprising of 50 patients) underwent pterygium excision with amniotic membrane graft. Patients were followed up postoperatively upto six months. The results at 6 weeks and 6 months were used to grade the final appearance. The recurrence rates between the two groups at 6 weeks and 6 months were analyzed using the  $\chi^2$  test. **Results:** In the conjunctival autograft group, the recurrence was seen in 1 out of 50 patients (= 2%) and in the amniotic membrane group, the recurrence rate was 12% (6 out of 50). The recurrence rate in the amniotic membrane group was significantly higher than that in the conjunctival autograft group ( $p < 0.005$ ). **Conclusions:** Amniotic membrane graft had a higher recurrence rate than conjunctival autograft.*

**Keywords:** Pterygium, Conjunctival Autograft, Amniotic Membrane

## 1. Introduction

Pterygium is a triangular fibrovascular subepithelial ingrowth of degenerative bulbar conjunctival tissue over the limbus onto the cornea, which may be atrophic, stationary or progressive. Pterygia tend to occur in hot and dry climatic regions, a high risk prevails in outdoor workers exposed to sunlight, especially those working in the setting of highly reflective surfaces.

Despite the multifactorial pathogenesis, surgery is the mainstay of treatment. The primary concern in pterygium surgery is recurrence defined by regrowth of the fibrovascular tissue across the limbus and on to the cornea.

If no additional measures are performed, pterygium excision alone is commonly referred to as bare sclera excision. The recurrence rates for bare sclera excision alone are unacceptably high (ranging from 30 to 80%) when compared with other treatment modalities (1-3). As such, bare sclera excision alone is no longer recommended for the treatment of pterygium. Pterygium excision is often combined with various adjunctive measures to prevent recurrence of the disease. These may be broadly classified as adjunctive medical methods, beta-irradiation, and surgical methods.

Intraoperative (0.02% for 2-3 minutes) and postoperative (0.04 or 0.02% four times a day for 1-2 weeks) mitomycin C remain the most commonly used medical adjunctive therapies for the prevention of pterygium recurrence. The surgical options available include the use of conjunctival autograft, limbal and limbal-conjunctival transplant, conjunctival flap and conjunctival rotation autograft surgery, amniotic membrane transplant, cultivated conjunctival transplant, lamellar keratoplasty and use of fibrin glue.

Many authors have reported that amniotic membrane grafts are a viable alternative to conjunctival autografts in reducing recurrences after pterygium excision. The possible mechanisms of preventing pterygium recurrence include promotion of conjunctival epithelium, inhibition of inflammation by inhibiting chemokine expression by fibroblasts and interleukin-1 expression by epithelial cells, and inhibition of neovascularisation by inhibiting vascular endothelial cell growth. As there have been few randomised studies comparing the recurrence rate between conjunctival autografts and amniotic membrane grafts in both primary and recurrent pterygium, we conducted a randomised prospective controlled study to examine this question.

Volume 6 Issue 4, April 2017

[www.ijsr.net](http://www.ijsr.net)

Licensed Under Creative Commons Attribution CC BY

## 2. Aims and Objectives

The study was conducted in the Postgraduate department of Ophthalmology SHER-I-KASHMIR INSTITUTE OF MEDICAL SCIENCES (SKIMS) MEDICAL COLLEGE BEMINA to compare the recurrence rate of pterygium after excision with free conjunctival autograft versus amniotic membrane graft.

## 3. Materials and Methods

The present study was a comparative, randomised prospective study. One hundred consecutive patients who presented with primary pterygium during the study period were randomly assigned to one of the two groups- one group (comprising of 50 patients) underwent pterygium excision with conjunctival autograft and the other group (comprising of 50 patients) underwent pterygium excision with amniotic membrane graft. Patients with glaucoma, ocular surface abnormalities, ocular or adnexal infections, recurrent pterygium, and collagen vascular disease were excluded from the study.

To control for the surgeon bias, all procedures were performed by a single surgeon. For conjunctival autografts, a free graft of size similar to the exposed area was obtained from the superotemporal bulbar conjunctiva after raising the conjunctiva by injecting xylocaine. For amniotic membrane grafts, commercially available amniotic membrane sterilized by gamma irradiation was cut into the same size as the defect. Both types of graft were secured, flattened and approximated to the recipient episcleral tissue edge by 6-8 interrupted 10-0 nylon sutures.

Patients were followed up postoperatively on day one, one week, four weeks, six weeks and six months. Recurrence of pterygium and any postoperative complication were noted. The results at 6 weeks and 6 months were used to grade the final appearance based on the criteria given by Prabhasawat et al.(4) The recurrence rates between the two groups at 6 weeks and 6 months was analyzed using the  $\chi^2$  test.

## 4. Results

A total of 100 eyes of 100 patients were included in the study. In the conjunctival autograft group there were 30 males and 20 females; in amniotic membrane group there were 26 males and 24 females ( $p=0.420$ ). In conjunctival autograft group age ranged from 18-68 years (mean  $40.06 \pm 12.83$  years). In amniotic membrane group age range was 21-63 years (Mean  $39.64 \pm 11.61$  years) ( $p=0.864$ ). The ratio of the right and left eyes; gender distribution; age range and size of pterygia were not statistically different between the two groups.

In conjunctival autograft group, 1 patient had grade 2 recurrence at 6 weeks which progressed to grade 3 at 6 months. In amniotic membrane group, 6 patients had grade 2 recurrence at 6 weeks which remained grade 2 at 6 months in 1 patient, progressed to grade 3 recurrence in 4

patients and progressed to grade 4 in 1 patient. Thus, there is a significant difference in the recurrence rate between the two groups at 6 weeks and 6 months. Amniotic membrane graft (12%) has significantly higher recurrence rate than conjunctival autograft (2%). ( $p=0.046$  which is  $<0.05$ ).

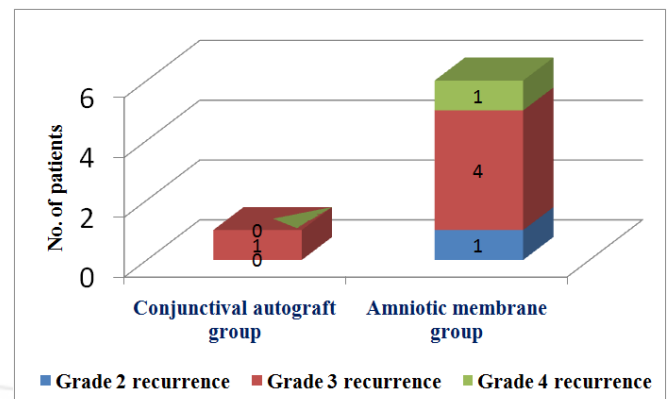


Figure 1: Recurrence in the two groups at 6 months

In the conjunctival autograft group, suture granuloma occurred in 2 patients (4%) and in the amniotic membrane group, suture granuloma occurred in 3 patients (6%) ( $z=0.46$ ,  $p=0.646$ ). These suture granulomas responded to conservative treatment in the form of suture removal and topical steroid therapy in 4 cases and required revision surgery with excision of granuloma in 1 case. No other complication was noted in either group. Thus there was no significant difference in complication rate between two groups. No symblepharon occurred in any of the patients.

## 5. Discussion

The reported recurrence rates of pterygium after excision vary greatly not only among different surgical procedures but also between different groups carrying out the same procedure. To eliminate such variability, the same technique was carried out by the same surgeon throughout the study. With this variable controlled, and similar demographic data and sufficient follow up, we could compare the role of conjunctival autografts and amniotic membrane grafts in covering the pterygium excision defects to reduce the recurrence rate. Our result, confirms that conjunctival autografts achieve the best result, with a recurrence rate of 2% at 6 months in a total of 50 eyes. The recurrence rates in our study was lower in both groups than those previously reported, possibly due to the race of our patients and decreased incidence of UV exposure.

The common age at presentation is 40-50 years. In our study 57% patients were in 30-50 years age group. Male preponderance is seen in most studies; our study agrees with this as 56 of our patients were males and 44 were females. The primary outcome measure was the recurrence seen in 6 of 50 (12%) in amniotic membrane group and 1 of 50 (2%) in conjunctival autograft group. This was comparable to that found in other studies like recurrence rate of 2.6% in CLAT and 10.9% in AMT found in Prabhasawat P *et al.* study, (4) 3.8% and 5.4% respectively in CLAT and AMT category in David Hui-Kang Ma *et al.*

study, (5) 2.6% in CLAT and 3% in AMT category in Soloman A *et al* study.(6)

Operative complications related to pterygium excision are uncommon, and are generally related to the surgical technique. This includes excessive bleeding, button hole of the conjunctiva graft, perforation of the globe with the suture needle, and injury to the medial rectus muscle. The main postoperative complication is recurrence. Other complications such as granuloma, dellen and persistent epithelial defects are not uncommon, but these may be easily treated with no significant long-term sequelae. Complications from pterygium excision with conjunctival autograft and amniotic membrane in this study were infrequent and included suture granuloma (2 cases in conjunctival autograft group and 3 in amniotic membrane group).

Although this study shows that amniotic membrane grafts are less proficient than conjunctival autografts in reducing recurrences after pterygium excision, it indicates that this technique could be considered as an alternative in the surgical management of pterygia, especially when the bare sclera technique alone has an unacceptably high recurrence, and complications related to mitomycin-C as an adjunctive treatment are a concern. The amniotic membrane graft can be considered to be the first choice for those with advanced and diffuse conjunctival involvement (bi-head) or those who might like to preserve the donor bulbar conjunctiva for a prospective glaucoma-filtering procedure.

## References

- [1] Frucht-Pery J, Charalambos SS, Ilsar M. Intraoperative application of topical mitomycin C for pterygium surgery. *Ophthalmology* 1996; 103:674–677.
- [2] Lam DS, Wong AK, Fan DS, et al. Intraoperative mitomycin C to prevent recurrence of pterygium after excision: a 30-month follow-up study. *Ophthalmology* 1998; 105:901–904.
- [3] Gupta VP, Saxena T. Comparison of single-drop mitomycin C regime with other mitomycin C regimes in pterygium surgery. *Ind J Ophth* 2003; 51:59–65.
- [4] Prabhasawat P, Barton K, Burkett G, et al. Comparison of conjunctival autografts, amniotic membrane grafts, and primary closure for pterygium excision. *Ophthalmology* 1997;104:974–85.
- [5] David Hui-Kang Ma, Lai-Chu See, Su-Bin Liao, et al. Amniotic membrane graft for primary pterygium: comparison with conjunctival autograft and topical mitomycin C treatment. *Br J Ophthalmol* 2000;84:973–978.
- [6] Solomon A, Pires RT, Tseng SC. Amniotic membrane transplantation after extensive removal of primary and recurrent pterygia. *Ophthalmology* 2001; 108:449–460.

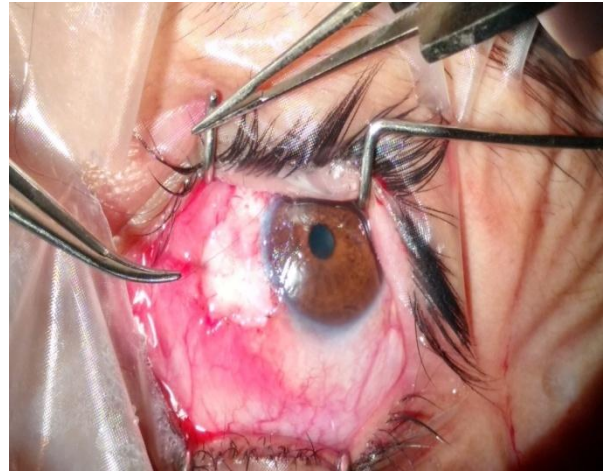


Figure 1: Pterygium excision with conjunctival autograft being done.

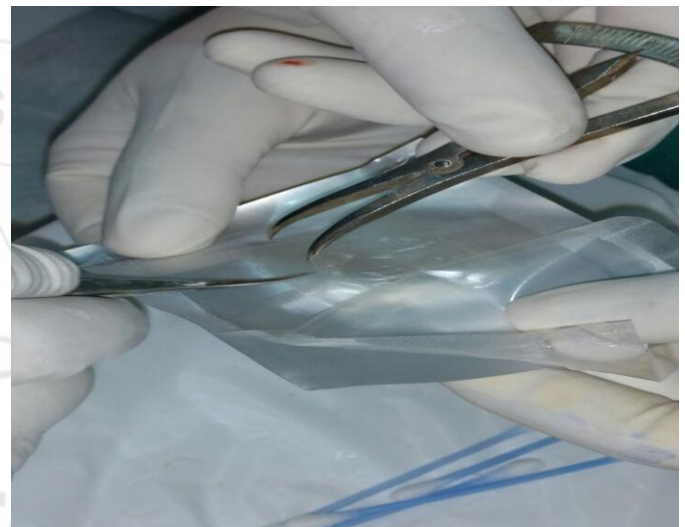


Figure 2: Dried amniotic membrane of appropriate size being cut