

Clinical Evaluation of Nd:YAG Laser Applications during Nonsurgical Periodontal Treatment in Patients With Chronic Periodontitis

Mariya Miteva¹, Stefan Peev², Elitsa Sabeva³, Ivailo Hristov⁴

Department of Periodontology and Dental Implantology, FDM, Medical University of Varna

Abstract: *The purpose of this study was to compare the clinical efficacy of nonsurgical periodontal treatment with and without Nd:YAG laser (NDL) applications in patients with chronic periodontitis (CP). The study population consisted of 30 patients with generalized CP. The study compared the clinical effects of scaling and root planing (SRP) and SRP plus NDL in periodontal pockets ≥ 4 mm with bleeding on probing (BoP) of patients with CP. The study patients were divided into two groups: SRP-group and SRP + NDL group. Clinical examinations were performed immediately before SRP (the baseline) as well as 1,5 month and 3 months after treatment. The recovery for pocket depth (PD), gingival margin and clinical attachment level were almost equal in both control and test groups. SRP plus NDL application versus SRP application alone did not lead to significant differences in any clinical parameters between the two groups of patients. Our results do not justify the use of Nd: YAG laser as an adjunct to the nonsurgical periodontal treatment.*

Keywords: nonsurgical periodontal treatment, Nd:YAG laser

1. Introduction

Periodontal disease is initiated by pathogenic plaque biofilm and characterized by bacteria-induced inflammatory destruction of tooth-supporting structures and alveolar bone. Currently, the most widely accepted and effective treatment approach for periodontal disease is the mechanical removal of the bacterial biofilm and their toxins from the tooth surface by scaling and root planing (SRP). Methods that can be used as adjuncts to SRP have been proposed to promote reduction or elimination of periodontal pockets. The aim of this study was to compare the effect of NDL with SRP versus SRP alone in the treatment of chronic periodontitis.

2. Literature Survey

The first application of the lasers for tooth tissues is reported by Goldman et al. [1] and Stern and Sognaes [2]. Each article describes the effect of ruby laser on enamel and dentin. Nevertheless, the current use of lasers in dental medicine originates from an article published in 1985 by Myers and Myers [3]. It describes the elimination of tooth cavity in vivo using modified ophthalmic Nd: YAG laser [4]. Four years later it is supposed that Nd: YAG can be used for oral soft tissue surgery [5], which eventually leads to nowadays connection between the lasers and clinical periodontology. [6, 7, 8]

The wavelength of Nd: YAG laser is highly absorbed by pigmented tissues, making it a very effective surgical laser for cutting and coagulating of soft tissues, with good hemostasis. In addition to his surgical applications [9] there is a study on the use of Nd: YAG laser for nonsurgical sulcus debridement in control of periodontal diseases [10] and a laser-assisted new attachment procedure (LANAP). [11]

Studies of Israel et al. [12], Spencer et al. [13] and Yamaguchi et al. [14] have concluded that treatment with

Nd: YAG laser and ultrasonic scaling result in significant improvements in clinical parameters compared to baseline, while Slot et al. [15] did not reveal any advantages in using Nd: YAG laser as an adjunct to SRP in both the active phase and the maintenance phase of periodontal treatment.[16] These findings are confirmed by other authors as well. [17, 18, 19, 20]

3. Material

The study included 30 male and female patients aged between 40-62 years, systemically healthy, none-smokers with presence of chronic generalized periodontitis - superficialis or profunda. Patients were divided into two groups - Group 1 (SRP) and Group 2 (SRP + Nd: YAG).

Supra- and subgingival plaque and calculus are removed (scaling) with ultrasound equipment and tips for supra- and subgingivally instrumentation. After cleaning supragingival tooth surfaces are polished with rubber, brush and an abrasive paste. A rinse solution that contains 0.1% chlorhexidine and inhibits plaque formation was prescribed to the patients bid for 2 weeks. A toothpaste that inhibits plaque formation was prescribed to the patients as well.

On the next visit the pocket depth, gingival margin, extent of furcation coverage and mobility were examined. Debridement of the root surfaces is performed within 24 hours (as per the principle of complete oral cavity disinfection - full mouth disinfection) with manual Gracey curettes with vertical, horizontal and oblique moves to a tactile sense of clean and smooth root surface. During the instrumentation washes with physiological saline solution (0,9% NaCl) are carried out - Group 1. After manual instrumentation in Group 2 the periodontal pockets are treated with Nd: YAG laser *SmartFile* DEKA with a fiber which is 300 μ m in diameter with the factory settings of the laser apparatus in program "Periodontal Treatment" and parameters as follow: power of 1.00 W, frequency 10 Hz, 100 mJ energy in short pulse and water cooling. The fiber is

inserted into the periodontal pocket in depth measured from -1 mm and moves with spiral movements in coronary direction. The processing time is 40 sec. per a periodontal pocket. Patient and staff put protective eyeglasses.

The studied parameters - pocket depth, gingival margin and clinical attachment level are registered again after six weeks and after three months post treatment.

The analysis of all results were done using IBM SPSS Statistics 19 software.

4. Results

On Figures 1, 2 and 3 are shown the average pocket depth, clinical attachment level and gingival margin by periods and surfaces.

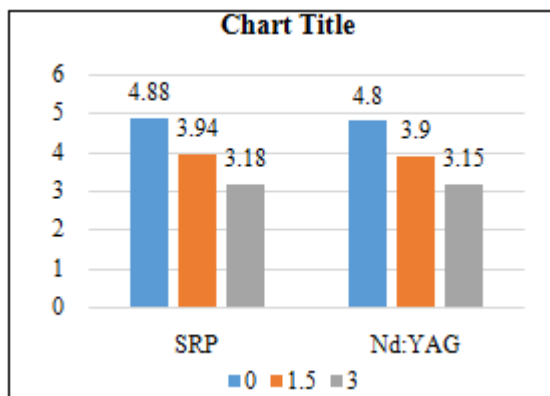


Figure 1: Pocket depth by groups and periods

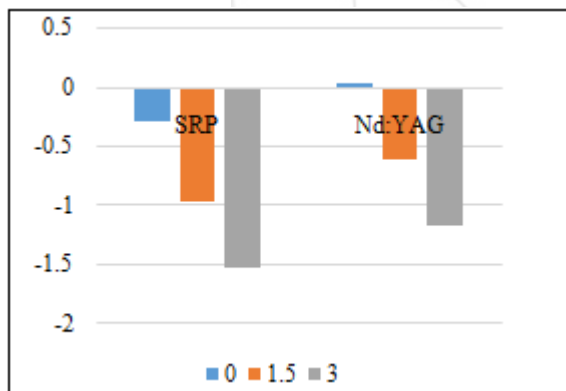


Figure 2: Gingival margin by groups and periods

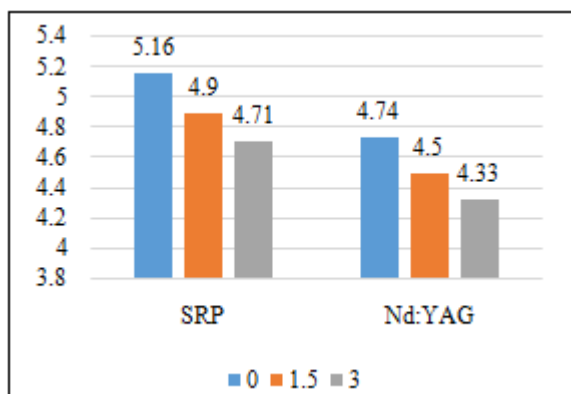


Figure 3: Clinical attachment level by groups and periods

After treatment in both study groups a statistically significant reduction in the pocket depth after six weeks and after three months after treatment has been observed, the differences between the groups were insignificant.

Reducing the pocket depth by periods for both treatment groups was approximately the same for the six tested surfaces and it is as follows: a reduction in depth on average by 0.94 mm in the SRP-group and 0.88 mm for SRP + Nd : YAG group has been observed six weeks after treatment. Three months after that was discovered decrease in the monitored parameter with another 0.76 mm for SRP-group and 0.74 mm for SRP + Nd: YAG group. The total reduction from baseline to the third month is average of 1.7 mm for the first group and 1.62 mm, respectively, for the second group.

It is reported remarkable increase in the values of gingival recession or decrease in gingival margin in both groups six weeks after treatment as well as three months after treatment. The reduction is 0.68 mm at the sixth week and additionally 0.57 mm to the third month. The exposed difference is statistically significant. The overall average reduction from baseline to the third month is 1.25 mm for the SRP-group. For the SRP+Nd: YAG group the values are respectively 0.65 mm at the sixth week, 0.57 mm to the third month and the total reduction is 1.22 mm.

The clinical attachment level in the SRP group shows a statistically significant decrease to the third month, an exception is the distal-vestibular area. The decrease in the values from baseline to the sixth week is 0.26 mm, reducing by further 0.19 mm to the third month. The total reduction in the value of clinical attachment level is expressed in gain of 0.45 mm to the third month after treatment. In the SRP+ Nd: YAG group it is also observed a statistically significant decrease until the third month, except for the vestibulo-central and media-palatal areas. It is most likely due to the fact that this area is the least affected by a periodontal disease. The decrease in the values from baseline to the sixth week is 0.23 mm, reducing by further 0.18 mm to the third month. The total reduction in the clinical attachment level is expressed in gain of 0.41 mm to the third month after treatment.

5. Discussion

Within our study, nonsurgical periodontal therapy resulted in a reduction in the pocket depth, a decrease in values of margo gingivalis and gain of clinical attachment level.

Almost 1/3 of the registered periodontal pockets are with pocket depth (PD) ≥ 6 mm before starting treatment, and in the other cases the depth is 4-5 mm.

From 373 periodontal pockets with PD ≥ 6 mm, their number has decreased to 137 for the SRP+Nd: YAG group and a decrease from 463 to 147 has been observed for the SRP-group after six weeks. Until the third month the number is 24 for the SRP+Nd: YAG group and 27 for the SRP-group.

Reducing PD of the periodontal pockets that were ≥ 6 mm to values of 4-5 mm confirms that debridement has become a "gold standard" in the non-surgical treatment of periodontal diseases. [21]

The healing processes take place at the expense of increase in the gingival recession, which is almost the same for both groups - 1.25 mm for the SRP-group and 1.22 mm for the SRP+Nd: YAG group, and minimum gain of clinical attachment of 0.45 mm for the SRP-group and 0.41 mm for the SRP+Nd: YAG group.

No statistically significant difference in the studied parameters between the SRP-group and the SRP+Nd: YAG group has been observed. These results are confirmed by other authors as well [15, 19, 22, 23, 24], but they are in contradiction of some studies that prove statistically significant difference [25, 26, 27, 28].

6. Conclusion

Although there appear to be many claims surrounding the use of laser therapy in addition to or in place of traditional therapy, there is no evidence that any laser system adds clinical value over and above SRP and conventional surgical treatment. No long-term clinical studies have shown that laser therapy alone can be used effectively to treat adult chronic periodontitis. Such therapy does, however, add cost to the patient's expenses for periodontal therapy.

References

- [1] Goldman L, Hornby P, Meyer R, Goldman B. Impact of the laser on dental caries. *Nature*. 1964 Jul 25;203:417. PubMed PMID: 14197393.
- [2] Stern RH, Sognnaes RF. Laser inhibition of dental caries suggested by first tests in vivo. *J Am Dent Assoc*. 1972 Nov;85(5):1087-90.
- [3] Myers TD, Myers WD. In vivo caries removal utilizing the YAG laser. *J Mich Dent Assoc*. 1985 Feb;67(2):66-9.
- [4] Stern RH, Sognnaes RF. Laser inhibition of dental caries suggested by first tests in vivo. *J Am Dent Assoc*. 1972 Nov;85(5):1087-90.
- [5] Myers TD. What lasers can do for dentistry and you. *Dent Manage*. 1989 Apr;29(4):26-8, 30.
- [6] Midda M, Renton-Harper P. Lasers in dentistry. *Br Dent J*. 1991 May 11;170(9):343-6.
- [7] Midda M. Lasers in periodontics. *Periodontal Clin Investig*. 1992 Spring;14(1):14-20.
- [8] Midda M. The use of lasers in periodontology. *Curr Opin Dent*. 1992 Mar;2:104-8.
- [9] Fornaini C, Rocca JP, Bertrand MF, Merigo E, Nammour S, Vescovi P. Nd:YAG and diode laser in the surgical management of soft tissues related to orthodontic treatment. *Photomed Laser Surg*. 2007 Oct;25(5):381-92.
- [10] Aoki A, Mizutani K, Takasaki AA, Sasaki KM, Nagai S, Schwarz F, Yoshida I, Eguro T, Zereto JL, Izumi Y. Current status of clinical laser applications in periodontal therapy. *Gen Dent*. 2008 Nov-Dec;56(7):674-87; quiz 688-9, 767.
- [11] Slot DE, Kranendonk AA, Paraskevas S, Van der Weijden F. The effect of a pulsed Nd:YAG laser in non-surgical periodontal therapy. *J Periodontol*. 2009 Jul;80(7):1041-56.
- [12] Israel M, Cobb CM, Rossmann JA, Spencer P. The effects of CO₂, Nd:YAG and Er:YAG lasers with and without surface coolant on tooth root surfaces. An in vitro study. *J Clin Periodontol*. 1997 Sep;24(9 Pt 1):595-602.
- [13] Spencer P, Cobb CM, McCollum MH, Wieliczka DM. The effects of CO₂ laser and Nd:YAG with and without water/air surface cooling on tooth root structure: correlation between FTIR spectroscopy and histology. *J Periodontal Res*. 1996 Oct;31(7):453-62.
- [14] Yamaguchi H, Kobayashi K, Osada R, Sakuraba E, Nomura T, Arai T, Nakamura J. Effects of irradiation of an erbium:YAG laser on root surfaces. *J Periodontol*. 1997 Dec;68(12):1151-5.
- [15] Slot DE, Timmerman MF, Versteeg PA, van der Velden U, van der Weijden FA. Adjunctive clinical effect of a water-cooled Nd:YAG laser in a periodontal maintenance care programme: a randomized controlled trial. *J Clin Periodontol*. 2012 Dec;39(12):1159-65.
- [16] Slot DE, Kranendonk AA, Van der Reijden WA, Van Winkelhoff AJ, Rosema NA, Schulein WH, Van der Velden U, Van der Weijden FA. Adjunctive effect of a water-cooled Nd:YAG laser in the treatment of chronic periodontitis. *J Clin Periodontol*. 2011 May;38(5):470-8.
- [17] Jensen J, Lulic M, Heitz-Mayfield LJ, Joss A, Lang NP. Nd:YAG (1064 nm) laser for the treatment of chronic periodontitis: a pilot study. *J Invest Clin Dent*. 2010 Aug;1(1):16-22.
- [18] Liu CM, Hou LT, Wong MY, Lan WH. Comparison of Nd:YAG laser versus scaling and root planing in periodontal therapy. *J Periodontol*. 1999 Nov;70(11):1276-82.
- [19] Miyazaki A, Yamaguchi T, Nishikata J, Okuda K, Suda S, Orima K, Kobayashi T, Yamazaki K, Yoshikawa E, Yoshie H. Effects of Nd:YAG and CO₂ laser treatment and ultrasonic scaling on periodontal pockets of chronic periodontitis patients. *J Periodontol*. 2003 Feb;74(2):175-80.
- [20] Radvar M, MacFarlane TW, MacKenzie D, Whitters CJ, Payne AP, Kinane DF. An evaluation of the Nd:YAG laser in periodontal pocket therapy. *Br Dent J*. 1996 Jan 20;180(2):57-62.
- [21] Cobb CM. Non-surgical pocket therapy: mechanical. *Ann Periodontol*. 1996 Nov;1(1):443-90.
- [22] Neill ME, Mellonig JT. Clinical efficacy of the Nd:YAG laser for combination periodontitis therapy. *Pract Periodontics Aesthet Dent*. 1997 Aug;9(6 Suppl):1-5.
- [23] Ratka-Krüger P, Mahl D, Deimling D, Mönting JS, Jachmann I, Al-Machot E, Sculean A, Berakdar M, Jervøe-Storm PM, Braun A. Er:YAG laser treatment in supportive periodontal therapy. *J Clin Periodontol*. 2012 May;39(5):483-9.
- [24] Schwarz F, Sculean A, Georg T, Reich E. Periodontal treatment with an Er: YAG laser compared to scaling and root planing. A controlled clinical study. *J Periodontol*. 2001 Mar;72(3):361-7.

- [25] Kelbauskiene S, Maciulskiene V. A pilot study of Er,Cr:YSGG laser therapy used as an adjunct to scaling and root planing in patients with early and moderate periodontitis. *Stomatologija*. 2007;9(1):21-6.
- [26] Qadri T, Javed F, Poddani P, Tunér J, Gustafsson A. Long-term effects of a single application of a water-cooled pulsed Nd:YAG laser in supplement to scaling and root planing in patients with periodontal inflammation. *Lasers Med Sci*. 2011 Nov;26(6):763-6.
- [27] Schwarz F, Pütz N, Georg T, Reich E. Effect of an Er:YAG laser on periodontally involved root surfaces: an in vivo and in vitro SEM comparison. *Lasers Surg Med*. 2001;29(4):328-35.
- [28] Yilmaz S, Algan S, Gursoy H, Noyan U, Kuru BE, Kadir T. Evaluation of the clinical and antimicrobial effects of the Er:YAG laser or topical gaseous ozone as adjuncts to initial periodontal therapy. *Photomed Laser Surg*. 2013 Jun;31(6):293-8.

