

A Study of Incidence of Echogenic Cardiac Focus in Second Trimester Ultrasound:

Dr Srinivas Prasad

Department of Radiology and Imaging, East Point Medical College, Bangalore

Abstract: *The frequency of chromosomal anomalies is 1 in 165. Hook established the relationship between advanced maternal age and fetal aneuploidy. The most common of such markers for aneuploidy include: echogenic intracardiac focus (EIF). The majority of this associated with an increased risk of trisomy 21. There is conflicting evidence in the literature regarding not only the management of isolated ultrasound EIF but also its potential association with aneuploidy. There is a paucity of information in the literature regarding the prevalence of these markers in different population. This study is one such novel effort to find the incidence of presence of EIF in actual confirmed cases of Down syndrome.*

Keywords: Down syndrome, Echogenic cardiac focus, second trimester, Aneuploidy

1. Introduction

The frequency of chromosomal anomalies is 1 in 165 [1]. Hook established the relationship between advanced maternal age and fetal aneuploidy [2]. The most common of such markers for aneuploidy include: echogenic intracardiac focus (EIF). The majority of this associated with an increased risk of trisomy 21 [3], [4]. There is conflicting evidence in the literature regarding not only the management of isolated ultrasound EIF but also its potential association with aneuploidy [5,6]. There is a paucity of information in the literature regarding the prevalence of these markers in different population [7].

Down syndrome (Trisomy 21) is a condition derives its name from Dr Langdon Down, who first described it in the Clinical Lecture Reports of the London Hospital in 1866. The chromosomal basis of Down syndrome was not established until 1959 by Lejeune and his colleagues in Paris. The overall birth incidence, when adjusted for the increasingly widespread impact of antenatal screening, is approximately 1: 1000 in the United Kingdom, which has a national register. In the United States, the birth incidence has been estimated at approximately 1 1800. In the United Kingdom, approximately 60% of Down syndrome cases are detected prenatally. There is a strong association between the incidence of Down syndrome and advancing maternal age. The most common finding in the newborn period is severe hypotonia. Usually the facial characteristics of upward sloping palpebral fissures, small ears, and protruding tongue prompt rapid suspicion of the diagnosis, although this can be delayed in very small or premature babies. Single palmar creases are found in 50% of children with Down syndrome in contrast to 2% to 3% of the general population. Congenital cardiac abnormalities are present in 40% to 45% of babies with Down syndrome, with the three most common lesions being atrioventricular canal defects, ventricular septal defects, and patent ductus arteriosus.

Sophisticated ultrasonography has resulted in the identification of subtle anomalies in the fetus, the significance of which is not always clear. For example, choroid plexus cysts are sometimes seen in the developing cerebral ventricles in mid-trimester. Initially, it was thought

that these were invariably associated with the fetus having trisomy 18 but in fact they occur frequently in normal fetuses, although if they are very large and do not disappear spontaneously they can be indicative of a chromosome abnormality. Increased echogenicity of the fetal bowel has been reported in association with cystic fibrosis. Initial reports suggested this finding could convey a risk as high as 35 10% for the fetus having cystic fibrosis, but it is now clear that this risk is probably no greater than 1% to 2%. Novel ultrasonographic findings of this kind are often called soft markers, and their interpretation must be approached cautiously in the effort to distinguish normal from abnormal variation.

This study is one such novel effort to find the incidence of presence of EIF in actual confirmed cases of Down syndrome.

2. Aims and Objectives

To study and to find the incidence of presence of EIF in actual confirmed cases of Down syndrome.

3. Materials and Methods

This study was done in the Department of Radiology and Imaging, East Point College and Research Sciences.

This study is a multiple step randomized double blinded fold study.

This study was done from December 2014 to December 2016.

The study was done using 141 subjects.

Detailed History was taken and after relevant clinical Examination that was done in the Department of OBG, the scanning was posted in the Department of Radiodiagnosis and Imaging.

The patient was asked to drink water and was asked to lie down in a supine position. After applying the USG gel the abdominal scan was done. The placenta was located and then immediately fetal cardiac shadow was noted. Then the Echogenic Cardiac Focus was tested for hyper echogenicity.

Volume 6 Issue 4, April 2017

www.ijsr.net

Licensed Under Creative Commons Attribution CC BY

If positivity was found then the other markers were routinely checked for. The other so called soft tissue markers were also examined and in case the others were visible then that particular soft tissue marker was also noted and the patient was asked to undergo further Pre Natal Diagnoses which was done after thorough Genetic Counseling. So after the scrutiny 140 confirmed cases of Downs syndrome were identified and in them the incidence of Echogenic cardiac focus was confirmed.

4. Result

Table 1: Mean age of the study population:

Total	Mean Age	Standard Deviation
141	34.33 years	2.46 years

The mean age of the population was found to be 34.33 years and the standard deviation was found to be 2.46 years.

Table 2: Frequency of Echogenic cardiac Focus Positivity:

Total	Echogenic cardiac Focus Present	Echogenic cardiac Focus Not Found
141	71	69

The Echogenic cardiac Focus was found in 71 patients and in 69 patients even though they were confirmed to be Downs syndrome no Echogenic cardiac Focus was found to be there.

Image 1: Frequency of Echogenic cardiac Focus Positivity:

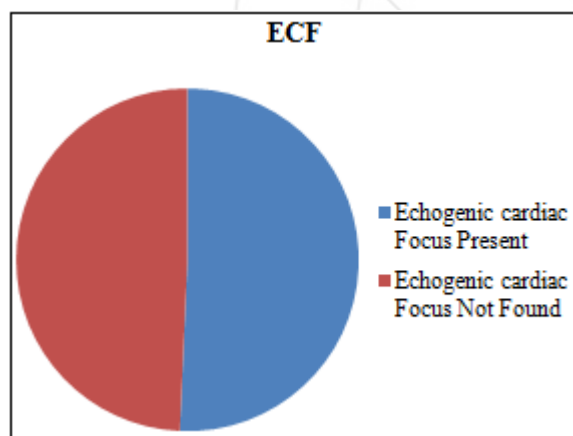


Table 3: Association of Echogenic cardiac Focus with Downs Syndrome:

Total	X ² value	p value
69	2.542	0.468

So the incidence of Echogenic cardiac Focus is not significantly associated with that of Downs Syndrome.

5. Discussion

The mean age of the population was found to be 34.33 years and the standard deviation was found to be 2.46 years. The age of the population was on a higher side and is in agreement with the study of Hook EB². The incidence of Echogenic cardiac Focus is not significantly associated with that of Downs Syndrome. The study is in agreement with Andrei Rebarber et al⁸. Even though it was not found to be

significantly associated but still it's a powerful tool in India because it is cheap and also forms the first line of diagnosis.

Ultrasonography offers a valuable means of prenatal diagnosis. It can be used not only for obstetric indications, such as placental localization and the diagnosis of multiple pregnancies, but also for prenatal diagnosis of structural abnormalities not associated with known chromosomal, biochemical or molecular defects. Ultrasonography is particularly valuable because it is non-invasive and conveys no known risk to the fetus or mother. It does, however, require expensive equipment and a skilled, experienced operator. For example, a search can be made for polydactyly as a diagnostic feature of a multiple abnormality syndrome, such as one of the autosomal recessive short-limb polydactyly syndromes that are associated with severe pulmonary hypoplasia invariably lethal. Similarly; a scan can reveal that the fetus has a small jaw, which can be associated with a posterior cleft palate and other more serious abnormalities in several single-gene syndromes

6. Conclusion

The incidence of Echogenic cardiac Focus is not significantly associated with that of Downs Syndrome. Even though it was not found to be significantly associated but still it's a powerful tool in India because it is cheap and also forms the first line of diagnosis.

References

- [1] Drugan A, Johnson MP, Evans MI. Ultrasound screening for fetal chromosome anomalies. American Journal of Medical Genetics. 2000;90:98–107. doi: 10.1002/(SICI)1096-8628(2000117)90:2<98::AID-AJMG2>3.0.CO;2-H.
- [2] Hook EB. Chromosome-Abnormalities in Older Women by Maternal Age - Evaluation of Regression-Derived Rates in Chorionic Villus Biopsy Specimens. American Journal of Medical Genetics. 1990;35:184–187.
- [3] Snijders RJM, Shawa L, Nicolaidis KH. Fetal Choroid-Plexus Cysts and Trisomy-18 - Assessment of Risk-Based on Ultrasound Findings and Maternal Age. Prenatal Diagnosis. 1994;14:1119–1127.
- [4] Lehman CD, Nyberg DA, Winter TC, Kapur RP, Resta RG, Luthy DA. Trisomy-13-Syndrome - Prenatal Us Findings in A Review of 33 Cases. Radiology. 1995;194:217–222.
- [5] Winter TC, Anderson AM, Cheng EY, Komarniski CA, Souter VL, Uhrich SB, Nyberg DA. Echogenic intracardiac focus in 2nd-trimester fetuses with trisomy 21: Usefulness as a US marker. Radiology. 2000;216:450–456.
- [6] Bettelheim D, Deutinger J, Bernaschek G. The value of echogenic foci ('golfballs') in the fetal heart as a marker of chromosomal abnormalities. Ultrasound in Obstetrics & Gynecology. 1999;14:98–100.
- [7] Shipp TD, Bromley B, Lieberman E, Benacerraf BR. The frequency of the detection of fetal echogenic intracardiac foci with respect to maternal race. Ultrasound in Obstetrics & Gynecology. 2000;15:460–462.

- [8] Andrei Rebarber,¹Kenneth A Levey,²Edmund Funai,²Susan Monda,¹ and Michael Paidas² An ethnic predilection for fetal echogenic intracardiac focus identified during targeted midtrimester ultrasound examination: A retrospective review BMC Pregnancy Childbirth. 2004; 4: 12.

