

# Bilateral Indolent Mooren's Ulcer – A Rare Case Report

Dr. Bhanu Devi<sup>1</sup>, Dr. Kousik Sarkar<sup>2</sup>

<sup>1</sup>Professor & HOD, Upgraded Department of Ophthalmology, Assam Medical College & Hospital, Dibrugarh, Assam, India  
<sup>2</sup>Post Graduate Trainee, Upgraded Department of Ophthalmology, Assam Medical College & Hospital, Dibrugarh, Assam, India

**Abstract:** Mooren's ulcer is a rare idiopathic peripheral ulcerative keratitis, causing progressive peripheral guttering of cornea. A 62 year old male presented with progressive bilateral peripheral guttering of cornea with no associated systemic symptoms. He was treated with topical steroids and conjunctival resection with amniotic membrane transplantation. Patient was improved symptomatically.

**Keywords:** Mooren's ulcer, Indolent variety, Conjunctival resection, Amniotic membrane transplantation

## 1. Introduction

Mooren's ulcer is a painful, progressive, chronic ulcerative keratitis that begins peripherally and progresses circumferentially and centrally. It is an idiopathic disease occurring in complete absence of any diagnosable systemic disorder that could be responsible for the progressive destruction of the cornea. The disease is strictly a peripheral ulcerative keratitis (PUK), with no associated scleritis [1]. The disorder was named as Mooren's ulcer after Dr. Mooren, who was the first to clearly describe this insidious corneal problem and define it as a clinical entity in 1863 and 1867 [2].

## 2. Case Report

A 62 years old male Patient came in OPD with chief complains of mild pain, irritation & redness of both eyes since 15 - 20 days with Photophobia & progressive blurring of vision. No history of any previous ocular trauma, chemical burn, herpes simplex, herpes zoster, TB, any other infectious or venereal disease etc. There were also no h/o any other systemic complaints like joint pain, chest pain, cough, ear & or nose deformity, urinary abnormality at the time of presentation, recent & remote past.

involving the periphery of the cornea, resulting corneal thinning (see Figure 2). At 6-9 o'clock position there was full thickness thinning resulting iris prolapse (see Figure 2). Edge of the lesion was steep at 5-6 o'clock position and sloping at 9-5 o'clock position with irregular margins (see Figure 4) There was conjunctivalization of cornea at 11-1 o'clock position (see Figure 2)

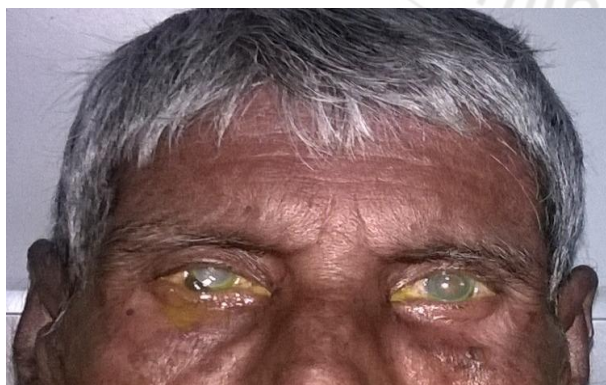

Figure 1: Bilateral corneal ulceration

On examination:

Visual acuity of Right eye was HM + at the time of presentation. Both conjunctival and ciliary congestion were present. Cornea was hazy and an ulcerative lesion, present

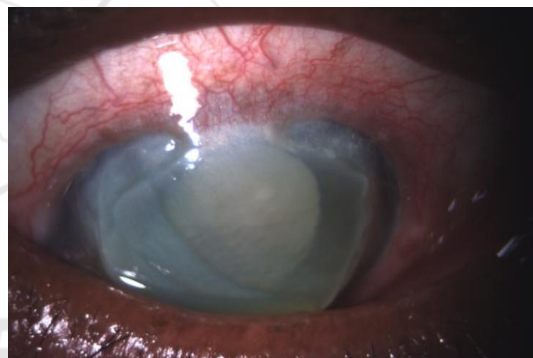

Figure 2: Peripheral ulcerative lesion

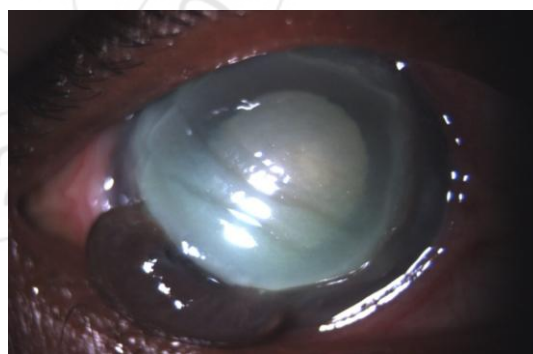


Figure 3: Iris prolapse

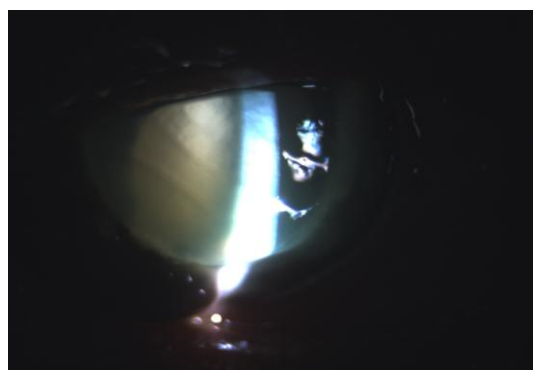


Figure 4: Steep edge of ulcer

Volume 6 Issue 3, March 2017

[www.ijsr.net](http://www.ijsr.net)

Licensed Under Creative Commons Attribution CC BY

In left eye visual acuity was 6/24 at the time of presentation with very mild conjunctival and ciliary congestion. Cornea was hazy and an ulcerative lesion involved the corneal periphery causing thinning of cornea (Figure 5). Edge of the lesion was steep at 3-7 o'clock position and sloping at 9-3 o'clock position (Figure 6). At 12-1 o'clock position there was conjunctivalization of the cornea.

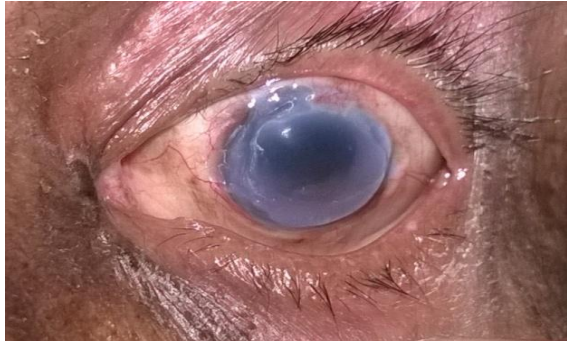


Figure 5: Peripheral corneal ulceration



Figure 6: Steep edge

There was no clear space between limbus & the lesion in both eyes. Corneal sensation was slightly diminished in both eyes and the ulcer was stained positive with fluorescein. Lens of the right eye was cataractous and there was pseudophakia of left eye.

Routine blood and urine examination was within normal limits. Random blood sugar was 93 mg/dl. Chest X-ray was within normal limit. RA factor was negative. No abnormality detected on X-ray of small joints of hands & feet and sacroiliac joint. Anti ds-DNA, anti ANA, p-ANCA, c-ANCA was negative. No organisms detected on microbiological culture of the lesion and lid secretions.

The case was treated with topical steroid 1% prednisolone acetate initially at 1 hourly interval, then tapered. Cycloplegic, 1% atropine sulphate, 8 hrly, artificial tear substitute, 4 hrly and oral non steroidal anti-inflammatory drugs twice daily were also given. 2 days later conjunctival resection with amniotic membrane transplantation of right eye (Figure 7) and conjunctival resection of left eye was done. Visual acuity of the right eye improved to FC+ and left eye to 6/18 after 15 days.

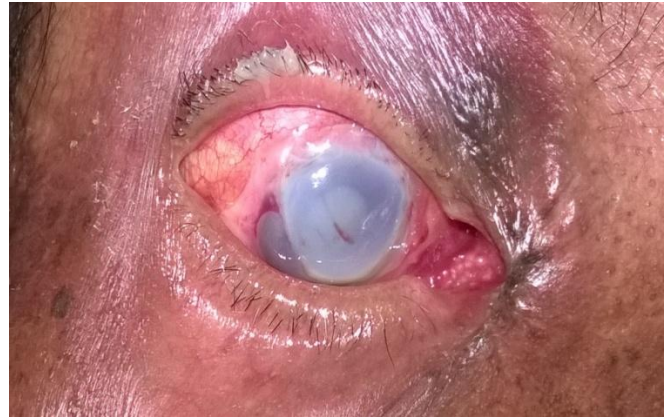

Figure 7: Amniotic membrane transplantation of right eye

### 3. Discussion

Mooren's ulcer is an idiopathic disease, occurs in absence of any systemic disorder that could be responsible for progressive destruction of cornea. Strictly it is a peripheral ulcerative keratitis (PUK), with no associated scleritis. Possibly Mooren's ulcer represents a type 3 hypersensitivity reaction [3]. Wood and Kaufman described two clinical types of Mooren's ulcer [4]. The first, limited type, is usually unilateral, with mild to moderate symptoms, and generally responds well to medical and surgical treatment. This type is believed to occur in older patients and is known as typical or benign Mooren's ulcer. The second type is bilateral although both eyes may not be affected simultaneously, with relatively more pain and generally a poor response to therapy. The bilateral variety primarily occurs in younger patients and is known as atypical or malignant Mooren's ulcer. However, in 1990, Lewallen and Courtright, in their review of the published series of Mooren's ulcer, found that 43% of older patients had bilateral disease, whereas bilateral disease was present in only one-third of patients younger than 35 years [5].

Watson based on clinical presentation and anterior segment fluorescein angiographic findings, divided Mooren's ulcer into three distinct varieties [6]. Unilateral Mooren's ulceration is a painful progressive corneal ulceration in elderly patients and is associated with nonperfusion of the superficial vascular plexus of the anterior segment. Bilateral aggressive Mooren's ulceration, which occurs in young patients, progresses circumferentially, then centrally in the cornea. There is vascular leakage and new vessel formation, extending into the base of the ulcer. Bilateral indolent Mooren's ulceration usually occurs in middle-aged or aged patients presenting with progressive peripheral corneal guttering in both eyes, with little inflammatory response. There is no change from normal vascular architecture except an extension of new vessels into the ulcer.

So, going through this classification we can say that, our case falls into bilateral indolent variety.

Recently, topical ciclosporin 0.5% ophthalmic solution 4 to 6 times daily has been successfully used to treat Mooren's ulcer without the potential side effects of oral immunosuppressants [7]. Those cases of bilateral or progressive Mooren's ulcer

that fail therapeutic steroids and conjunctival resection will require systemic cytotoxic chemotherapy to bring a halt to the progressive corneal destruction.

#### 4. Conclusion

Mooren's Ulcer is a distinct entity, but it is a diagnosis of exclusion. Other causes of peripheral ulcerative keratitis should be ruled out, such as infections, collagen vascular diseases, and degenerative processes.

Precise pathophysiology of Mooren's Ulcer remains uncertain. Advances have been made in its step-approach management; however, significant percentage of cases remains refractory to available therapies, and result in severe visual morbidity.

#### References

- [1] Cornea, 3<sup>rd</sup> ed. By Krachmer, Mannis & Hollland : chapter:95 - Mooren's Ulcer, Prashant Garg, Virender S. Sangwan
- [2] Mooren A: Ulcus Rodens. Ophthalmiatische Beobachtungen. Berlin, A. Hirschwald, 1867. 107-110
- [3] Albert Jakobiec's Principles & Practice of Ophthalmology: chapter: 46 - - Immunologic Disorders of the Conjunctiva, Cornea, and Sclera, C. Stephen Foster
- [4] Wood T, Kaufman H: Mooren's ulcer. Am J Ophthalmol 1971; 71:417-422
- [5] Lewallen S, Courtright P: Problems with current concepts of the epidemiology of Mooren's corneal ulcer. Ann Ophthalmol 1990; 22:52-55
- [6] Watson PG: Management of Mooren's ulceration. Eye 1997; 11:349-356
- [7] Zhao JC, Jin XY: Immunological analysis and treatment of Mooren's ulcer with cyclosporin A applied topically. Cornea 1993; 12:481-488