

Radiographical Evaluation of Anterior Mental Loop Presence, Position and Length in Iraqi Sample using Cone Beam Computed Tomography

Areej A. Najm, B.D.S., M.Sc.¹, Resha J. Al-Sudani, B.D.S., M.Sc.², Alaa Salah Mahdi, B.D.S., M.Sc.³

¹Lecturer, Department of Oral Diagnosis, College of Dentistry, University of Baghdad, Iraq)

²Assist. Lec, Department of Oral Diagnosis, College of Dentistry, University of Baghdad, Iraq)

³Assist Lec, Department of Oral Diagnosis, College of Dentistry, University of Baghdad, Iraq)

Abstract: Background: Anterior mental loop represent the terminal portion of inferior alveolar nerve when directed outward, upward and backward to open at mental foramen. This study aims to detect the presence of anterior mental loop, measuring its length, position and assess the prevalence in Iraqi sample using CBCT and to demonstrate the importance and accuracy of CBCT. Materials and Method: in this retrospective study one hundred fifty CBCT images retrieved from patients archives in Baghdad dental center/ Iraq. About 300 mandibular nerves and mental foramen evaluated of 75 male and 75 female. Anterior mental loop detected, length measured and position in relation to buccal, lingual, superior and inferior cortical bones was evaluated. All measurements done by CBCT program software then data analyzed. Results: the prevalence of anterior mental loop was (48.6%) present in 73 CBCT images (44 male and 29 female) with no significant difference. Unilateral cases (45 case) was more than bilateral cases (28 case) but the difference was statistically non significant. There was extremely high significant difference in anterior loop length in relation to gender (longer in male), and high significant difference in anterior loop position (distance between anterior loop and lingual cortical bone) in relation to other bony surfaces. Conclusion: pain, parasthesia and discomfort associated with surgical procedures involving the interforaminal region of mandible occur due to accidental injury to anterior mental loop. so a precise evaluation of anatomical structures in the interforaminal region especially the anterior loop is highly recommended to prevent damage to the neurovascular bundle during implant placement, treatment of fracture mandibule, osteotomy and genioplasty.

Keywords: anterior mental loop, implant, mental foramen and CBCT

1. Introduction

One of the most frequent complications occur during Implant placement or any surgical procedures in the mandibular interforaminal region is a damage or injury to the neurosensory bundles of the chin and lower lip. This complication occurs when important structures such as the mental foramen, the anterior mental loop and the incisive canal are not properly identified and protected⁽¹⁾.

The inferior alveolar nerve pass through mandibular canal, at premolar region it divides into two branches (mental and incisive), sometimes it continued beyond the anterior margin of mental foramen and curved upward, backward to exit through mental foramen, forming the anterior mental loop.^(2,3)

The mental and buccal nerves provide sensation to the lower lip and chin (skin and mucous membrane), and the vestibular gingiva of the mandibular anterior teeth, while the incisive branch innervates the anterior teeth including the first premolar⁽⁴⁾.

Implant placement in mandibular premolar region should be done carefully due to presence of mental foramen with its great differences in location and number. In addition to the presence of anterior mental loop which may be unilateral, bilateral or absent in some cases⁽⁵⁾.

This loop represent an important structure that should be noticed or diagnosed prior to implant placement to prevent

complications such as iatrogenic damage to nerve, bleeding, parasthesia, anaesthesia and dysthesia.⁽⁶⁾

In some patient, the mandibular canal bifurcates in the inferior superior or medial lateral plane^(5,7). The bifurcated mandibular canal may manifest more than one mental foramen. This may or may not be seen on panoramic film or periapical films, they are associated with false positive or false negative results. Therefore the use of appropriate imaging techniques is necessary to allow accurate identification of presence and location of these vital structures, avoiding injuries during surgical procedures in the mandibular interforaminal region, including insertion of dental implants, mentoplasty and rehabilitation after trauma.⁽⁸⁾

Several studies performed to determine the prevalence, position and anterior loop length, and the results were greatly different.⁽⁹⁾ Radiographic studies performed by OPG or periapical reported the length ranged between (0 – 7.5 mm), which may be underestimated^(10,11), or overestimated^(10,12) due to its 2D representation of 3D object. Other studies performed by surgical dissection of cadavers with probe may give overestimated length due to penetration of incisal canal. on other hand some dissection studies may used markers for comparison with radiograph^(11,13).

Studies used CT scan revealed a higher prevalence of anterior mental loop compared to plane radiograph but it still not accepted to be used (unless it's necessary) due to its high radiation dose and cost.^(14,15)

Volume 6 Issue 3, March 2017

www.ijsr.net

Licensed Under Creative Commons Attribution CC BY

Previous researchers set a standard reference for the anterior loop measurements which was a plane represent its most anterior margin that is coincident with the origin of the incisive canal as ^(12,16,17). A radiologic study set a cutoff point of 3 mm as the maximum diameter of the incisive canal as it separates from the anterior loop ^(15,18).

Cone beam computed tomography (CBCT) is a relatively new imaging modality that provides a detailed evaluation of important bony structures and provide imaging in three planes (axial, coronal and sagittal) without magnification and distortion in addition to its advantageous of multiplaner reformation and high resolution compared to conventional radiography ⁽¹⁸⁾, a relatively low radiation dose and high quality images that demonstrate the real size of anatomical structures of interforaminal region. ^(19,20)

The aims of this study were to detect the presence of anterior mental loop, measuring its length, position and assess the prevalence in Iraqi sample using CBCT.

2. Material and Methods

The sample consist of 150 Iraqi patients (75 male and 75 female) with age ranged between 18-45 years old, attending CBCT unit in Baghdad dental center for various diagnostic purpose, the images tacked by using 3D Cranex CBCT unit with field of view (Midi FOV 61x78 mm application area), both sides of mandible are examined and selected carefully according to the following criteria:

- 1) The anterior part of the body of mandible appears clearly without blurring and image must be of adequate diagnostic quality.

- 2) No pathological lesion, bony disease, congenital abnormalities, fracture, tumor affecting the examined area.

Each selected image was processed with (on dimand version 1.0 x64 edition) software, the slice thickness was 0.1 mm for axial and cross sectional view, then each image was evaluated for the presence of anterior mental loop (whether it's bilateral or unilateral), or it may be absent. The measurements were done in 3 view: axial, reconstructed panoramic, and cross sectional. In axial view the appropriate slice is selected, the most anterior part of mental foramen marked as a first marker, then the most mesial part of mental nerve was marked as a second marker ⁽²¹⁾. The distance between the two points was measured by drawing two parallel line one represent the first marker and the second represent the second marker, both of them perpendicular to the inferior border of mandible, by using reconstructed panoramic view ⁽¹⁴⁾. Then 4 distances were measured in cross section at middle part of the length of mental loop, from the most superior border of the loop to the alveolar crest (SAL), from the most lingual border of the loop to the outer surface of the lingual cortical plate (LAL), from the most buccal border of the loop to the outer surface of buccal cortical plate (BAL), and from the most inferior border of the loop to the outer surface of the inferior cortical plate (IAL). (As shown in fig 1-2)

All data collected and analyzed. the prevalence of anterior mental loop was calculated, the mean value, range, SD of the anterior loop length and its location were calculated.

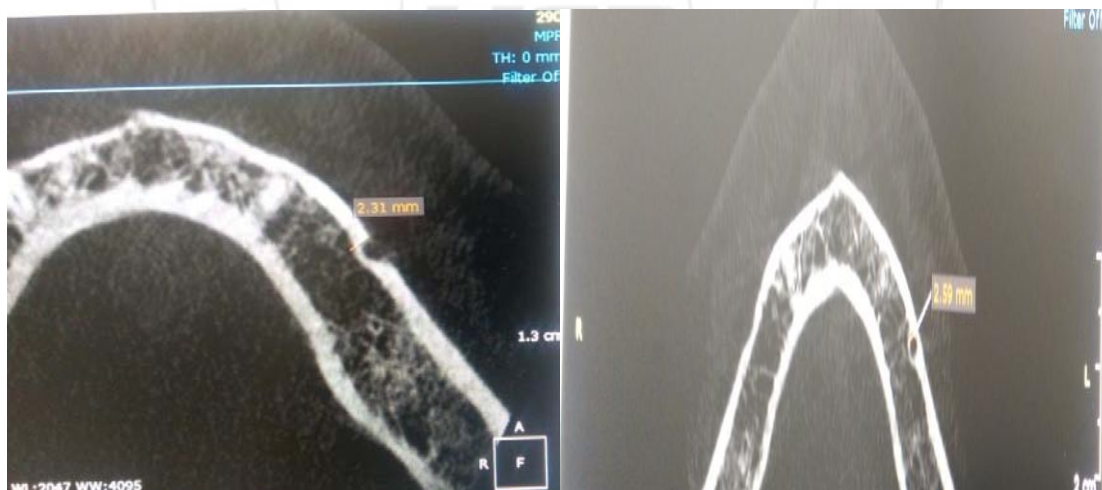

Figure 1: The measurement of the most anterior part of AML (left) and the measurement of the most mesial part of AML (right).

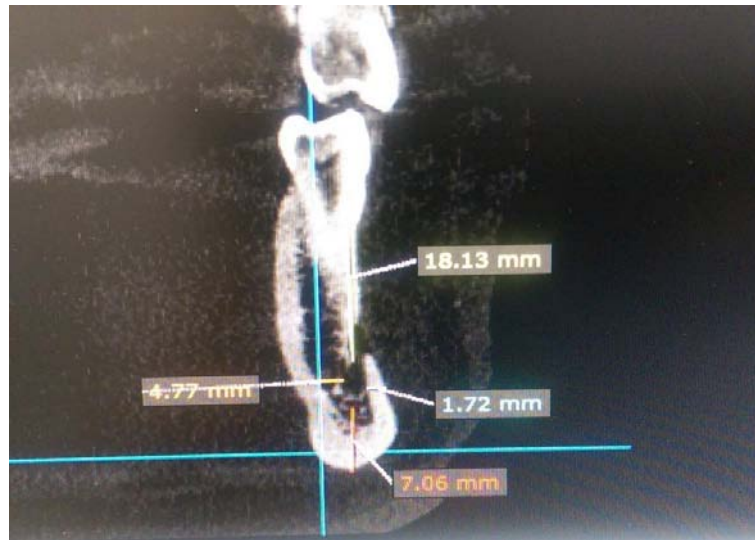


Figure 2: Measurement the AML position

3. Results

One hundred fifty CBCT images were evaluated (300 hemi mandibles), anterior mental loop was detected in 73 images only (48.6 %). Male patients represent 60.2 % of the detected cases (44 images from 73) while female patients represent 39.7% (29 images from 73).

For male patients , anterior mental loop found unilaterally in 26 case and bilaterally in 18 case, while for female patients , the loop detected unilaterally in 19 case and bilaterally in 10 cases only.(the details was shown in table 1 and 2)

Table 1: Prevalence of anterior loop in relation to gender

Gender	Prevalence Number (%)		Total	P- value
	not present	present		
Male	31 (20.6%)	44 (29.3%)	75 (50%)	P> 0.9
Female	46 (30.6%)	29 (19.3 %)	75 (50%)	NS
Total	77 (51.3%)	73 (48.6%)	150(100%)	

Table 2: Percentage of anterior loop occurrence in relation to side of mandible

Side of mandible	Prevalence		Total	P- value
	Number	(%)		
Bilateral	28	38.5	28 (38.5%)	P> 0.05
Unilateral	Right	20	45 (61.6 %)	NS
	Left	25		
Total	73 (100%)			

The length of the anterior loop and distance between anterior loop and surrounding bones were measured in relation to gender. The mean \pm SD of SAL, IAL, BAL, and LAL for male were (17.47 \pm 0.8), (7.61 \pm 0.8), (1.13 \pm 0.3), (4.38 \pm 0.4) respectively, and for female (17.24 \pm 0.5), (7.78 \pm 0.9), (1 \pm 0.3), (4.12 \pm 0.3) respectively. High significant differences between genders in distance between loop and lingual cortex (LAL) were found. The length of anterior loop was measured and longer loop detected in male patients (1.77 mm). The difference was extremely highly significant P < 0.0001. (The details shown in table 3)

Table 3: Measurements of anterior loop length and distance with surrounding bones in relation to gender

Distance	Gender	N	Mean	SD	SE	min	max	low 95% conf. limit	up 95% conf. limit	P- value
SAL	male	44	17.47	0.8	0.1	16.3	18.9	17.23	17.72	0.08
	female	29	17.24	0.5	0.1	16.4	18.4	17.01	17.46	NS
IAL	male	44	7.61	0.8	0.1	6.4	9	7.3	7.8	0.3
	female	29	7.78	0.9	0.1	6.3	9	7.4	8.1	NS
BAL	male	44	1.13	0.3	0.5	0.6	1.9	1	1.2	0.3
	female	29	1	0.3	0.5	0.5	1.8	0.8	1.1	NS
LAL	male	44	4.38	0.4	0.6	2.9	5.1	4.2	4.5	0.009 HS
	female	29	4.12	0.3	0.6	3.9	5	4	4.2	
Length	male	44	1.77	0.6	0.09	0.7	2.7	1.5	1.9	P<0.0001
	female	29	1.05	0.5	0.09	0.5	2.3	0.8	1.2	extremely Significant

Also the same measurements were repeated in relation to side of mandible. The mean \pm SD of SAL, IAL, BAL, and LAL for left side were (17.38 \pm 0.7), (7.57 \pm 0.9), (1.05 \pm 0.3), (4.31 \pm 0.3) respectively, and for right side (17.37 \pm 0.6), (7.78 \pm 0.9), (1.01 \pm 0.3), (4.26 \pm 0.4) respectively,

with no significant difference in any measurements. The anterior loop was longer in left side (1.54 mm) but the difference was statistically non significant. (The details shown in table 4)

Table 4: Measurements of anterior loop length and distance with surrounding bones in relation to side of mandible.

Distance	Side of mandible	N	Mean	SD	SE	min	max	low 95% conf. limit	up 95% conf. limit	P- value
SAL	left	25	17.38	0.7	0.1	16.3	18.9	17.1	17.5	0.9
	right	20	17.37	0.6	0.1	16.5	18.8	17.1	17.5	NS
IAL	left	25	7.57	0.9	0.1	6.2	9	7.3	7.8	0.2
	right	20	7.78	0.9	0.1	6.4	9	7.5	8	NS
BAL	left	25	1.05	0.3	0.05	0.4	1.9	0.9	1.1	0.5
	right	20	1.01	0.3	0.04	0.5	1.8	0.9	1.1	NS
LAL	left	25	4.31	0.3	0.05	3.9	5	4.2	4.4	0.5
	right	20	4.26	0.4	0.06	2.9	5.1	4.1	4.3	
Length	left	25	1.54	0.7	0.1	0.5	2.7	1.3	1.7	0.3
	right	20	1.4	0.6	0.09	0.5	2.7	1.2	1.5	NS

Anterior mental loop located more inferiorly and buccally as shown in table 5

Table 5: length of anterior mental loop in relation to position

	length	SAL	IAL	BAL	LAL
Mean	1.41	17.35	7.69	1.06	4.25
SD	0.7	0.6	0.9	0.3	0.4

4. Discussion

In this study anterior mental loop presence, length and position in relation to surrounding bone were measured using CBCT. About 300 mandibular canals and mental foramen evaluated and the anterior loop was detected in 73 patients (48.6%). The length and position were measured accurately using the CBCT. The mean length was 1.4 ± 0.6 mm ranged from 0.5 – 2.7 mm and it was longer in male patients with extremely high significant difference. while the position including four distances in relation to superior, inferior, buccal and lingual bony cortex of mandible. The mean of these distances were (17.4 ± 0.1) , (7.6 ± 0.9) , (1.08 ± 0.3) , and (4.3 ± 0.4) mm respectively.

Different diagnostic methods used for detection and measurements of anterior mental loop prevalence, position and length, some studies conducted on cadavers and dissected mandibles or dry skulls with markers and others performed by OPG, CT and CBCT.

In 1990 Misch and Crawford⁽²⁰⁾ evaluated 324 OPG and detected the anterior loop in 12% only and the mean length was 5mm. Bravitz et al. in 1993⁽¹²⁾ conduct a study in two way by cadavers dissection and OPG for 35 case, reported 54% for OPG and 11% in dissected cadavers. In 1993 another study was performed by Arzouman et al.⁽¹¹⁾ on 25 dried skull. the loop length and size measured in two OPG for each skull (one with marker injected into mandibular canal – method A, and the other without marker method B) and recorded loop length about 6.95 mm with a higher prevalence (76%) and larger size (4.64) in method A compared to method B (56% and size of 2.75). Solar et al. in 1994⁽²²⁾ examined 37 dissected cadavers and recorded a similar results to Arzouman, 60% prevalence and 5 mm length. These results were differed in comparison to the results of this study, which may be attributed to the difference in method used, because the cadaver provide real vision but the measurements done with probe or marker that may cause penetration into incisal canal resulting in larger length and size. And the OPG didn't give a precise measurements and even detection because its two dimension

representation of three dimensional object. Large percentage of false positive and negative results obtained due to perforation of incisal canal due to forceful injection of markers or may due to misinterpretation of incisal canal wide orifice as anterior mental loop. Rosenquist in 1996⁽²¹⁾ also used 58 cadavers and reported prevalence of loop 24% and length ranged between (0-1)mm. Mardinger et al. in 2000⁽¹⁶⁾ evaluated 46 hemimandible by OPG and surgical exposure, the prevalence was 19% and length ranged between 0.5 – 2.95 mm in OPG, while by surgical exposure it was 28% and length ranged 0.4- 2.19 mm. These length measurements were equals to the length ranged of this study.

Similar study conducted in 2003 by Kuzmanovic et al.⁽¹⁰⁾ on 22 cadavers, the prevalence in OPG was (27%) and the length was ranged between (0.5-3 mm) while in dissected cadaver was present in (35%) and length measurements was (0.4- 3.31) mm. Jacobs et al. in 2004⁽²³⁾ used OPG only to evaluate the prevalence of anterior loop and the result was 11%. The length results of the present study were agreed with these previous studies, but the prevalence was higher and this is due to high accuracy of CBCT (3D) compared to OPG (2D).

Another study conducted in 2004 by Neiva et al.⁽¹³⁾, 22 cadavers examined and anterior loop present in 88% of the cases and mean length was 4.1 mm. Uchida et al. in 2007⁽¹⁷⁾ measured the anterior loop length in 75 hemimandibles, the percentage was 62.7% and length ranged between (1-6.6)mm. these results were higher than the results of the present study and this may be due to differences in methods utilized and patients race and size.

Lower percentage of anterior loop was noticed with radiographical studies using OPG such as (Kaya, 2008 and Ngeow, 2009)^(14,24) 28% and 40.2% respectively. This due to small sample size and low accuracy of 2D (OPG) compared to the present methods used CBCT and large sample size.

Few studies performed with CBCT to measure the anterior loop length and position, so there was some difficulties for comparison of the present study results.

Uchida et al. in 2009⁽¹⁹⁾ performed another study to compare the accuracy of CBCT with that of direct surgical exposure of cadavers. and concluded that CBCT was more reliable, and recorded a mean length of 2.2 mm and diameter was 1.9 ± 1.7 mm. this result was agreed with the results of present study.

High percentage was recorded by this study compared to results of Ritter et al. in 2012⁽²⁵⁾ it was (31%) which may be due to great difference in sample size, but there were agreements in mean length (1.4 mm) and maximum length (4.6 mm) reported.

The results of this study agreed with CBCT studies done by many authors Apostolakis and Brown (2013)⁽¹⁸⁾, Rosa et al. (2013)⁽²⁶⁾, Chen et al. (2013)⁽²⁷⁾ and Lu et al. (2014)⁽²⁸⁾, they reported the length ranged (0-6 mm) with small difference in prevalence which due to differences in races and sample size.

The results of Watanabe et al. in 2010⁽²⁹⁾ agreed with those of present study. There was a high significant difference between male and female in anterior loop length (longer in male) and its distance to lingual cortex, with no significant difference in position of anterior mental loop to other surfaces.

5. Conclusion

CBCT is the preferred imaging for dental implant, it provides accurate measurements and assessments for different structures in maxillofacial region. The precise information obtained by CBCT should be kept in surgeon mind to identify the safest zone during implant placement in mental foramen region.

References

- [1] Juodzbaly G., Wang HL., Sabalys G. Anatomy of mandibular vital structures. Part II: Mandibular incisive canal, mental foramen and associated neurovascular bundles in relation with dental implantology. *J Oral Maxillofac B Res.* 2010; 1: 3.
- [2] Sun-Kyoung Yu, Seog Kim, Shin Gu Kang, Jae Hyuk Kim, Kyeong Ok Lim, Seong-Ik Hwang, Heung-Joong Kim. Morphological assessment of the anterior loop of the mandibular canal in Koreans. *Anat Cell Biol* 2015;48:75-80
- [3] Gumusok M., Kayadugun A. Ucok O. anterior loop of the mental nerve and its radiologic imaging: a review. *Marmara dental journal* 2013; 2:81:83
- [4] Won SY, Kim DH, Yang HM, Park JT, Kwak HH, Hu KS, Kim HJ. Clinical and anatomical approach using Sihler's staining technique (whole mount nerve stain). *Anat Cell Biol* 2011;44:1-7.
- [5] Dario LJ. Implant placement above a bifurcated mandibular canal: A case report. *Implant Dent* 2002;11: 258-261.
- [6] Driscoll CF. Bifid mandibular canal. *Oral Surg Oral Med Oral Pathol* 1990;70:807-811
- [7] Genú P., Vasconcelos R., Oliveira B., Vasconcelos B., Delgado N.. Analysis of anatomical landmarks of the mandibular interforaminal region using CBCT in a Brazilian population. *Braz J Oral Sci.* 2014 ; 13: 4
- [8] Neves FS, Vasconcelos TV, Oenning AC, de-Azevedo-Vaz SL, Almeida SM, Freitas DQ. Oblique or orthoradial CBCT slices for preoperative implant planning: which one is more accurate?. *Braz J Oral Sci.* 2014; 13 (2): 104-8.
- [9] Greenstein G, Tarnow D. The mental foramen and nerve: clinical and anatomical factors related to dental implant placement: a literature review. *J Periodontol* 2006;77:1933-43.
- [10] Kuzmanovic DV, Payne AG, Kieser JA, Dias GJ. Anterior loop of the mental nerve: a morphological and radiographic study. *Clin Oral Implants Res* 2003;14:464-71.
- [11] Arzouman MJ, Otis L, Kipnis V, Levine D. Observations of the anterior loop of the inferior alveolar canal. *Int J Oral Maxillofac Implants* 1993;8:295-300.
- [12] Bavitz JB, Harn SD, Hansen CA, Lang M. An anatomical study of mental neurovascular bundle-implant relationships. *Int J Oral Maxillofac Implants* 1993;8:563-7.
- [13] Neiva RF, Gapski R, Wang HL. Morphometric analysis of implant-related anatomy in Caucasian skulls. *J Periodontol.* 2004;75(8):1061-7.
- [14] Kaya Y, Sencimen M, Sahin S, Okcu KM, Dogan N, Bahcecitapar M. Retrospective radiographic evaluation of the anterior loop of the mental nerve: comparison between panoramic radiography and spiral computerized tomography. *Int J Oral Maxillofac Implants* 2008;23:919-25.
- [15] Li X, Jin ZK, Zhao H, Yang K, Duan JM, Wang WJ. The prevalence, length and position of the anterior loop of the inferior alveolar nerve in Chinese, assessed by spiral computed tomography. *Surg Radiol Anat* 2013;35:823-30.
- [16] Mardinger O, Chaushu G, Arensburg B, Taicher S, Kaffe I. Anatomic and radiologic course of the mandibular incisive canal. *Surg Radiol Anat* 2000;22:157-61.
- [17] Uchida Y, Yamashita Y, Goto M, Hanihara T. Measurement of anterior loop length for the mandibular canal and diameter of the mandibular incisive canal to avoid nerve damage when installing endosseous implants in the interforaminal region. *J Oral Maxillofac Surg* 2007;65:1772-9.
- [18] Apostolakis D, Brown JE. The anterior loop of the inferior alveolar nerve: prevalence measurements of its length and recommendation for interforaminal implant installation based on cone beam CT imaging. *Clin Oral Implants Res* 2012;23:1022-1030
- [19] Uchida Y, Noguchi N, Goto M, Yamashita Y, Hanihara T, Takamori H, Sato I., Kawai T., Yosue T. measurement of anterior loop length of mandibular canal and diameter of the mandibular incisive canal to avoid nerve damage when installing endosseous implant in the inter foraminal region :a second attempt introducing cone beam computed tomography . *J Oral Maxillofac Surg.* 2009 ;67: 744-50.
- [20] Misch CE, Crawford EA. Predictable mandibular nerve location – a clinical zone of safety. *Int J Oral Implantol* 1990;7:37-40.
- [21] Rosenquist B. Is there an anterior loop of the inferior alveolar nerve? *Int J Periodontics RestorativeDent.* 1996;16(1):40-5
- [22] Solar P, Frey G, Ulm C, Gruber H, Matejka M. A Classification of the intra osseous paths of the mental nerve. *Int. J. oral max. Fac. Implant.* 1994;9(3): 339-44.
- [23] Jacobs R, Mraiwa N, Van Steenberghe D, Sanderink G, Quirynen M. Appearance of the mandibular incisive

- canal on panoramic radiographs. *Surg Radiol Anat.* 2004;26(4):329- 33.
- [24] Ngeow WC, Dionysius DD, Ishak H, Nambiar P. A radiographic study on the visualization of the anterior loop in dentate subjects of different age groups. *Oral Sci.* 2009;51(2):231
- [25] Ritter L., Neugebauer J., Mischlowki RA., Dreiseidler T., Rothamel D., Richter U. Evaluation of the course of inferior alveolar nerve in the mental foramen by cone beam computed tomography. *Int J Oral Maxillofac Implants* 2010;27:1014-1021
- [26] Rosa MB., Sotto- Miaor BS., Machado VC., Francischone CE. Retrospective study of the anterior loop of the inferior alveolar nerve and the incisive canal using cone beam computed tomography. *Int J Oral Maxillofac Implants* 2013;28:388-92
- [27] Chen JC, Lin LM, Geist JR, Chen JY, Chen CH, Chen YK. A retrospective comparison of the location and diameter of the inferior alveolar canal at the mental foramen and length of the anterior loop between American and Taiwanese cohorts using CBCT. *Surg Radiol Anat* 2013;35:11-8.
- [28] Lu CI, Won J, Al-Ardah A, Santana R, Rice D, Lozada J. Assessment of the Anterior Loop of the Mental Nerve Using Cone Beam CT-Scan. *J Oral Implantol.* 2014 Feb 19.
- [29] Watanabe H, Mohammad Abdul M, Kurabayashi T, Aoki H. Mandible size and morphology determined with CT on a premise of dental implant operation. *Surg Radiol Anat* 2010;32:343-9.

