

# Preventive Role of L-Ascorbate in Hepatocarcinogenesis

Bhuniya Sudipta<sup>1</sup>, Dipak Bhuniya<sup>2</sup>

Department of Physiology, Sukumar Sengupta Mahavidyalaya, Midnapore, West Bengal, India

**Abstract:** Tumour cells shows an abnormal antioxidant status compared to normal cells. Antioxidants prevent Carcinogenesis if administered prior to or concomitant with carcinogen. Vanadium (V) dissolving in water at a dose of 0.05ppm administered orally daily along with ad libitum and L-Ascorbate dissolving in water (0.25mg in 100ml water) also administered orally twice a week controls the cell damage in Diethyl Nitrosamine (100mg per kg body weight) induced liver carcinogenesis in male Wistar male rats. An increase in hyperplastic nodules and decrease in total liver parenchyma in DEN induced hepatocarcinogenesis. Hyperplastic nodules and foci surrounding hepatic areas were found. Particularly L-Ascorbate acts as potent antioxidant in carcinogen control group at the end of 16<sup>th</sup> weeks of experiment when supplemented with vanadium by modulating the enzymatic action and thereby suppress tumor growth in hepatocarcinogenesis.

**Keywords:** carcinogenesis, vanadium, L-Ascorbate

## 1. Introduction

Human beings are always exposing to various carcinogens in their daily life at a very low concentration by active or passive process through environment. Liver is an important key organ in human body to run all metabolic process of the body. Recent report reveals that cancer is a major health problem and the second most common cause of death exceeded only by heart diseases in world and nearly one of every four death due to liver cancer. It has been steadily increasing since 1980s in developed and developing countries in world. To restrict such viable incidence the Present investigation to get the insight into preventing role of vanadium along with L-Ascorbate in Hepatocarcinogenesis is very rare and important.

Vanadium has a profound effect on cellular response and particularly in gene expression (Bosch et al, 1990) and biochemical metabolism. It has got function in biphasic manner on Cell growth by both inhibition and induction depending on its concentration in media (Smith, 1983). According to Sabbini et al (1983), Vanadate ions ( $10^{-7}$ - $10^{-3}$ M) inhibit deoxynucleotidyl transferase and activate DNA polymerase  $\alpha$ . But at higher dose inhibit DNA polymerase-1. L-Ascorbate is also a potent antioxidant that has power to boost immune function and interacting with metal ion creates hydrogenperoxide that protect the damage of DNA and mitochondria of cancer cell.

## 2. Methodology

Forty Wistar rats of 16 weeks having weight about  $130 \pm 10$  gm were divided into four groups. Ten animals remain in each group. The animals were maintained with balanced diet. Initiation of cancer in liver developed by administration of single intraperitoneal injection of Diethylnitrosamine at a dose of 100mg/kg body weight in 0.9% normal saline. Vanadium (v) and L-Ascorbate were dissolved in the drinking water at the rate of 0.05p.p.m and 0.25mg% respectively.

Groups were as follows:

**Group A-** Normal untreated control rats

**Group B-** Single dose of DEN injection on 4<sup>th</sup> week and sacrificed on 16<sup>th</sup> week.

**Group C-** Rats were administered with 0.05p.p.m of Vanadium in drinking water along with the Dose of DEN as given to group B rats.

**Groups D-** Rats were administered with 0.05 p.p.m of Vanadium and 0.25 mg% L-Ascorbate in drinking water along with the dose of DEN as given to Group-B rats.

All rats were maintained for 16 weeks and sacrificed at 16<sup>th</sup> weeks.

Livers were excised, quickly weighed, fixed in 10% formalin and processed for histological studies. The tissues were dehydrated through 70 %, 90% and 100% alcohol and embedded in low melting point paraffin.

## Morphological Study

Ten animals from each group were sacrificed at each week starting 4 weeks following DEN injection continued up to 16 weeks and opened viscera. Any gross alteration of liver by vascularisation or appearance tumor was noted and separated according to size variation.

## 3. General Observation

During the entire period of experiment no treatment related alterations in the daily intake of food and drinking water was observed among different groups of rats. It suggests that vanadium and L-ascorbate co-administration did not show any toxic effect that might have affected food and drink intake in treated rats.

## Normal body growth and liver weight

Body growth of rats was not affected during the experimental period and no significant difference was observed in the final body weight in any of experimental group and control. The final liver weight as well as relative liver weight was also unaltered in different treated rat in

compare to the subjects of control group as shown in Table – A.

#### Hepatic histopathology

As depicted in **Figure 1** the normal liver sections shows contain liver cell parenchyma with granulated cytoplasm and small uniform nuclei radially arranged around the central vein in hepatocytes. In contrast gross structural alterations were found in DEN treated rats (**Figure 2**). In these section phenotypically altered hepatocyte populations in the form of altered liver cell foci and nodules in varying extent throughout the hepatic parenchyma. Hepatocytes become enlarged, vasculated and binucleated. A substantial irregularity in shape of nucleous and chromatin pattern was also observed and the cytoplasm become extensively vacuolated, clear cells and basophilic focus are mostly found these sections. Supplementation with Vanadium (**Figure 3**) was reflected in almost normal cytoarchitecture of hepatocytes that contains compact cytoplasm with only clear cell fosi, eosinophilic focus as well as basophilic focus was also present. Supplementation of Vanadium and L-ascorbate shows normal cytoarchitecture of hepatocytes with compact cytoplasm with small uniform nuclei are observed (**Figure 4, 5**). There was no cytoarchitectural difference observed in hepatocytes observed in comparison to normal control group.

## 4. Result

**Table A:** Effect of Vanadium and L-ascorbate on body weight and liver weight

Group	No. of Rats	Final Body Weight	Liver Weight	Relative Liver Weight
A	10	300±4.1	9.2±0.2	3.6±0.6
B	10	234±0.2 <sup>a</sup>	8.6±0.6	4.0±0.2 <sup>c</sup>
C	10	276±4.3 <sup>b</sup>	8.8±0.01	3.02± 0.04 <sup>d</sup>
D	10	297±1.2	9.0±0.01	3.4±0.1

The values are expressed as Mean ± SEM.

<sup>a</sup>P<0.001 when compared to group A by student's t test

<sup>b</sup>P<0.01 when compared to group B by student's t test

<sup>c</sup>P<0.01 when compared to group A by student's t test

<sup>d</sup>P<0.01 when compared to group B by student's t test

**Table B:** Effect of Vanadium and L-ascorbate supplementation on the development of hepatocyte nodules induced by DEN in rats

Group	No. of Rats/ total no of hepatic nodules	No. of Nodules	Size of Nodules	
			≤ 1mm	>1 - ≤3 mm
A	-	-	-	-
B	10/10	89	41	48
C	6/10	46	37	09
D	-	-	-	-

**Table C:** Effect of Vanadium and L-ascorbate supplementation on the development of altered liver cell foci induced by DEN

Group	Treatment	No. of rats with foci /total rats	Foci incidents (%)	No. of foci / cm <sup>2</sup> *	Focal area (mm <sup>2</sup> )*	% area of liver parenchyma occupied by foci*
B	DEN control	10/10	100	14±0.4	0.24±0.2	2.51±0.21
C	DEN + Vanadium control	6/10	60	12±0.4 <sup>a</sup>	0.20±0.03	2.16±0.16 <sup>c</sup>
D	DEN+ Vanadium + Ascorbate	2/10	20	2.0±0.01 <sup>d</sup>	0.01±0.05	1.02±0.03 <sup>d</sup>

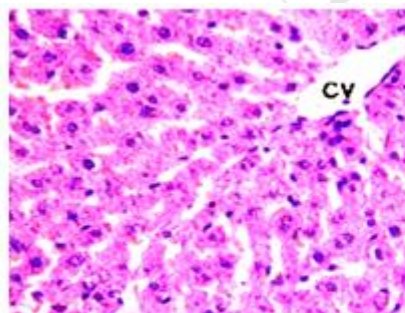
\*The values are expressed as Mean ± SEM

<sup>a</sup>p<0.005 when compared to Group B student's t-test

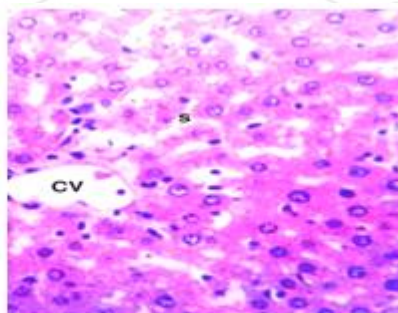
<sup>b</sup>p<0.001 when compared to Group B student's t-test

<sup>c</sup>P<0.001 when compared to Group B student's t-test

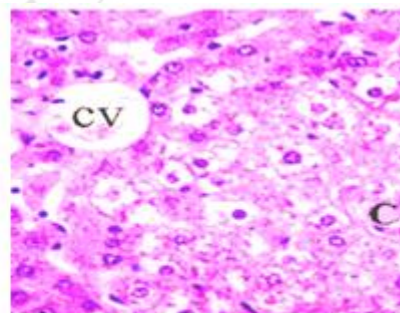
<sup>d</sup>P<0.001 when compared to Group B student's t-test



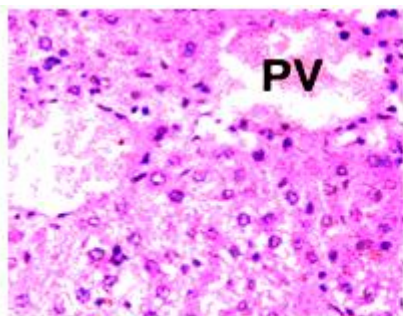
**Figure 1:** Normal



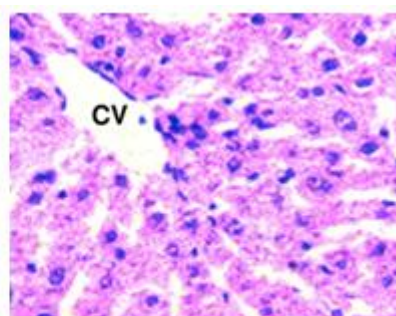
**Figure 2:** DEN Treated Rat



**Figure 3:** Effect of vanadium on DEN treated rat



**Figure 4:** Effect of vanadium and L-Ascorbate on DEN treated rat



**Figure 5:** Effect of vanadium and L-Ascorbate on DEN treated rat

## 5. Discussion

In the present morphometric evaluation the chemopreventive role of Vanadium and L-Ascorbate has been demonstrated. Our present investigation on the synergistic action of 0.5 p.p.m. Vanadium and 0.25mg L-Ascorbate on DEN induced hepato carcinogenesis showed a marked reduction of incidence, Multiplicity and size of visible hyperplastic nodules that precede the appearance of malignant tumour. It is assumed that these preneoplastic lesions are the possible precursor of liver cancer in rats and human (Farber and Cameron, 1980; Farber, 1990). The inhibitory response of both vanadium and L-ascorbate as observed in the present investigation is not likely to be mediated through improvement of nutritional status that also corroborates the observation of Thompson et al (1995). Hepatocarcinogens changes the cytoarchitecture of hepatic oval cell to ductular Cell with neoplastic nodules (Farber, 1980). Interesting findings in the present investigation that Vanadium exhibited inhibitory effect on both size and number of nodules without altering final (Thompson et al., 1995) that shown in **Fig-2**.

Present study showed the changes of body weight among the animals of groups before and after treatment with DEN, Vanadium and L-ascorbate. The final body weight of the rats treated with DEN only (Group-B) were found to be lower in comparison to animals of group-A (**Table-A**).

Supplementation of Vanadium and Ascorbate showed an increase of final body weight probably by modifying the metabolic activation as well as modulating chromosomal aberration in hepatic tissues that protect or prevent hepatocarcinogenesis. Carcinogens increase peroxidation of lipid and poly unsaturated fatty acid. Vitamin-C acts as free radical scavenger, trapping radicals to protect biomembranes from peroxide damage. It can donate electrons to free radicals like hydroxyl and superoxide radicals and speed up their activity. Vanadium along with L-Ascorbate decomposes the peroxides and there by protect liver (Sabbioni et al, 1993; Shi and Dalal, 1993) possibly modify the glutathione peroxidase-glutathione reductase system.

## References

- [1] Thompson, H J., Chasteen N D., Meeker L D: Dietary vanadyl(IV) sulfate inhibits chemically –induced mammary carcinogenesis. *Carcinogenesis* 5:51-61, 1995.
- [2] Bishayee A, Roy S., Chatterjee M : Characterisation of selective induction and alternation of Xenobiotic biotransforming enzymes by vanadium during diethylnitrosamine-induced chemical rat liver carcinogenesis. *Oncology Research* 11:41-53, 1999.
- [3] Sabbioni E., Pozzi G., Devos S., Casella L., Fischbach M. The intensity of vanadium (V)-induced Cytotoxicity and morphological transformation in BALB/373 cells is dependent on glutathione-mediated bio-reduction to vanadium(IV). *Carcinogenesis* 14:2565-2568, 1993.
- [4] Wattenberg L W, Lipkin M., Boone CW., Kelloff G J. Chemoprevention of cancer by naturally occurring and synthetic compounds in: *Cancer Research Journal* 19-39
- [5] Kappus H and Sites, H. (1981) Toxic drug effects associated with oxygen metabolism: Redox cycling and lipid peroxidation. *Cellular and Molecular Life Sciences* ,37:1233-1241. doi:10.1007/BF01948335.
- [6] Macara, I G., Kustin ,K. and Catley jr. (1980) Glutathione reduces cytoplasmic vandate .Mechanism and physiological implications. *Biochimica and Biophysica Acta*, 629,95-106, doi:10.1016/0304-4165(80)90268-8.
- [7] Attar A M.: Hepatoprotective influence of vitamin-C on Thioacetamide induce liver cirrhosis in Wistar rats. *Journal of pharmacology and Toxicology*, Vol-6, no.3, 218-233, 2011.
- [8] Willis G G, The influences of Ascorbic acid upon the Liver , *Canadian Medical Association Journal*, 76 :1044, 1957.
- [9] Padayatty S J., Katz A., Saab S., Wang, Kwon P Eck O. Lee J H., Chen S., Corpe C., Dutta A., Dutta S K., and Levine M: Vitamin C as an Antioxidant: Evaluation of its role in disease prevention, *Journal of the American college of Nutrition*, 22(1)18-35, 2003.