

Histological and Immunohistochemical (ANXA1) Analysis of Bisphosphonate (Zoledronate) Effect on Submandibular and Parotid Glands in Neonatal Rats

Essa Hasan Essa, B. D. S.¹, Nada M.H. Al-Ghaban, B.D.S., M.Sc., Ph.D²

¹MSc student in Oral Histology, College of Dentistry, Kuffa University, Iraq

²Assistant Professor Oral Histology & Biology, College of Dentistry, Baghdad University, Iraq

Abstract: **Background:** Zoledronate, a third generation bisphosphonate, is used for the therapy of bone metastases because of multiple myeloma or solid mass and for hyper-calcaemia of malignancy. Zoledronate is chiefly studied in bone but few are known about its effects on the salivary gland, so the aim of this study is to assess the Annexin-A1 expression and to evaluate the histological effect of zoledronate on submandibular and parotid salivary glands tissue in neonatal rats. **Material and method:** Forty newborn Wistar albino rats of both sexes with average weight (40-60gm) were randomly divided into four groups A,B,C and D (10 rats for each group). A and B were the control groups of 14 and 28 days were sacrificed respectively after injection with a single dose (0.1mg/kg) of sterile saline solution I.V. through the tail vein at age of two weeks. C and D were the experimental groups of 14 and 28 days were sacrificed respectively after injection with a single dose (0.1mg/kg) of zoledronic acid solution I.V. through the tail vein at age of two weeks. H & E staining was used for assessment of histological examination of the collected submandibular and parotid gland samples. Then anti-ANXA1 antibody was used for immunohistochemical investigation of Annexin-A1 expression. **Results:** Histologically, there was a relative increment in the secretory granules in the serous cells of the experimental groups over that of the control groups. Immunohistologically, there was a strong positive expression of ANXA1 in the ductal and myoepithelial cells of parotid and submandibular glands with high significant differences between experimental and control groups especially in 28 days after injection. **Conclusion:** Zoledronate may affect the secretory mechanism of parotid and submandibular glands due to either slowing exocytosis or incrementing the protein synthesis. The positive localization of Annexin-A1 in the ductal epithelium of salivary organs may be due to functional exchange of ions and proteins.

Keywords: Bisphosphonate, zoledronate, Annexin-A1, parotid gland, submandibular gland

1. Introduction

In individuals there are three pairs of major salivary glands: parotid, sub-mandibular and sub-lingual glands. Saliva is discharged inside the mouth via a series of ducts in the ductal system, and possesses different jobs via owning digestive, anti-bacterial, lubricant, buffering, and water balance function. Impairment of salivary glands results in dry mouth (xerostomia) and subsequently guides to progressive dental decays in addition to oral mucosal illness (1).

In rodents, the sub-mandibular and sub-lingual glands make one organ named the submandibular sublingual complex (SSC), situated in the ventral cervical position. The parotid is totally serous, located under the ear and proceeds over the ventro-lateral plane of the neck to the shoulder (2).

Bisphosphonate is a drug used to manage the osteoclast-mediated bone loss caused by osteoporosis, Paget disease, bone metastatic due to malignancies, multiple myeloma, and hypercalcemia due to malignancy. Furthermore, bisphosphonates are usually prescribed to prevent and treat a variety of other skeletal diseases, like osteogenesis imperfecta (3).

Among BPs, zoledronic acid (ZOL) has the more strength activity of anti bone lost and shows varied direct anticancer functions in vitro. Some chemical and biological properties of ZOL showing the potential for in vivo growth impairment and the mechanisms in charge of anti cancer effects are

starting to be clarified. ZOL impairs farnisyl pyrophosphates synthase, a code enzyme in the mevalonate pathway (4)

Adverse effects of ZOL on oral soft tissues were reported by Oliveira et al (5) via the morphological changes and biochemical alterations in the salivary organ tissue.

Annexin A1 is a glucocorticoid promoted protein, which is in charge for controlling many anti-inflammatory effects of glucocorticoids also used in glucocorticoid negative feedback impairment. Annexin A1 is secreted by the sub-mandibular salivary gland and is found in human saliva (6).

On the basis of the defensive role of ANXA1 and to considering the importance of salivary gland secretion as the first line of oral defence, we decided to evaluate the effects of bisphosphonate on the histology and on the expression of ANXA1 proteins using immunohistochemistry in rat major salivary glands.

2. Materials and Methods

Materials

- Zoledronic acid (Zometa 4mg vial, Novartis pharma AG, Basle, Switzerland).
- 0.9% Sodium Chloride.
- Anesthetic solution: Ketamine Hydrochloride
- Ketamin 50mg/ml
- Formalin 10%, Ethanol alcohol 96%, Xylol, Paraffin wax.
- Sterile distilled water.

Volume 6 Issue 2, February 2017

www.ijsr.net

Licensed Under Creative Commons Attribution CC BY

- Hematoxylen and eosin (H&E)
- Polyclonal antibody Annexin A1 from Abcam company UK (ab196830)
- Detection kit system, Abcam company UK (ab80436).

Methods

The present study includes 40 newborn Wistar albino rats of both male and female sexes with average weight (40-60) gm. The animals were randomly divided into four groups: the control group of 14 days sacrificed after injection (group A), the control group of 28 days sacrificed after injection (group B), the zoledronic acid -treated group of 14 days sacrificed after injection (group C) and the zoledronic acid -treated group of 28 days sacrificed after injection (group D). Twenty rats, 10 from group A and 10 from group B were injected with a single dose 0.1mg/kg of sterile saline solution intravenously through the tail vein at age of two weeks. The other twenty rats, 10 from group C and 10 from group D were injected with a single dose of 0.1mg/kg of zoledronic acid intravenously directly through the tail vein at age of two weeks^(7, 8). The weight of the animals was evaluated pre-injection and at the sacrificing day (post injection). The animals were sacrificed by given them high dose of general anesthesia. After dissection, the salivary glands are exposed, excised and collected in 10% formalin then blocked and processed to section. H & E staining was used for reassessment of histological examination of the collected samples.

The procedure of IHC assay for polyclonal antibody Annexin A1 was carried out in accordance with manufacturer instructions from Abcam company, UK. The scoring of positive cells was done under light microscope; using objective lens power x40. The staining intensity anti-ANXA1 was assessed using the following evaluation; weak, moderate or strong. The sum of the staining intensity was used for total immunoreactivity. Immunoreactivity was scored on a scale of 0 to 4 as follow:
1-2-10% of positive cells.
2-11-25% positive cells.
3-26-50% positive cells.
4-Representing more than 50% positively stained cells.

Dividing the total number of stained cells by the total number of cells present and multiplying this value by 100 provided the approximate percentage of positively stained cells⁽⁹⁾.

3. Results

Histological result

The light microscopic observation reveals almost the same histological pictures in submandibular glands in both control and experimental groups after 14 days of injection by presences of mixed serous and mucous acini and striated ducts (Figure 1 and 2). Histological figure of parotid gland of both control and experimental groups after 14 days of injections also illustrated the same histological findings by presence of pure serous acini with numerous intercalated ducts and excretory ducts (Figure 3 and 4). Regarding the histological results 28 days after injection also revealed same findings in both control and experimental groups in

parotid and submandibular glands except that in the locations of ofzymogen granules in the serous acini of both control and experimental groups. The zymogen granules were located at the apex of the serous cells in control groups with no difference in their location (Figure 5). Whereas, in experimental groups the zymogen granules were diffused throughout the cytoplasm of the serous cells (figure. 6).

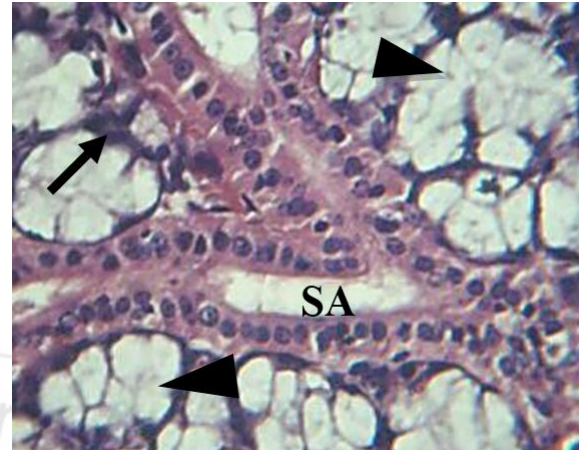


Figure 1: View of submandibular gland of control group A, shows mucous acinus (arrowheads) which capped by serous demiluns (arrow) and striated duct (SA). H&E. x100.

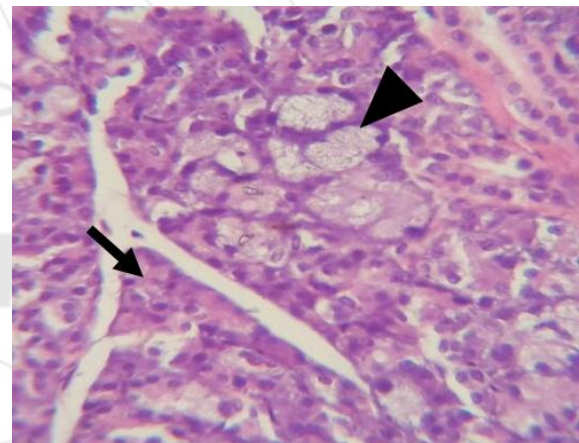


Figure 2: View of submandibular gland experimental group C, shows Serous (arrow) and mucous (arrowhead) acini. H&E X40.

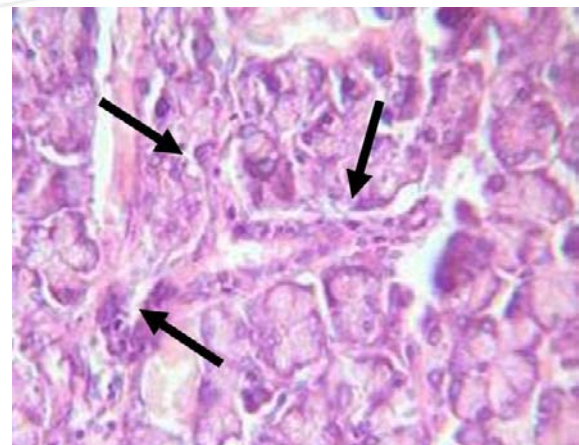


Figure 3: View of parotid gland of control group A shows a pure serous gland with branches of intercalated duct (Arrows) H&E. x40.

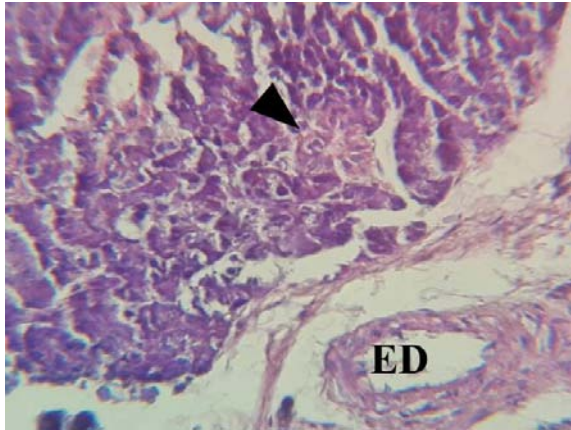


Figure 4: View of 14 day experimental group C parotid gland shows striated ducts (arrowhead) and excretory duct (ED).H&E.x40.

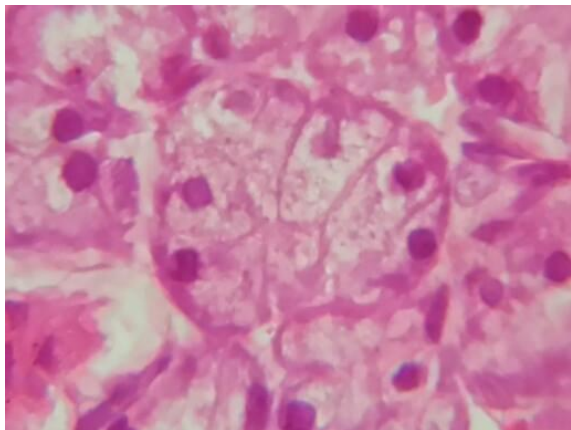


Figure 5: Error! No text of specified style in document.

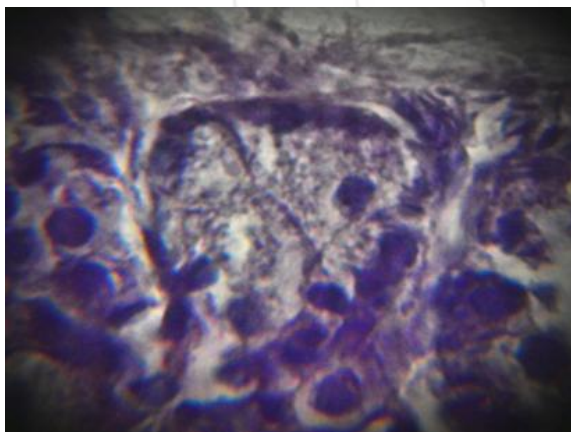


Figure 6: Error! No text of specified style in document.

Immunohistochemical result:

The immunohistochemical findings reveal positive cytoplasmic localization of ANXA1 in the salivary gland cells of both control and experimental groups. Strong positive cytoplasmic expression of ANXA1 was found in the ductal and myoepithelial cells of both parotid and submandibular glands, whereas the serous cells of both glands show negative expression after 14 days post injection (Figure 7 and 8). The immunohistochemical result 28 days after injection showed almost the same findings of 14 days after injection except that weak positive cytoplasmic expression was seen in mucous cells of submandibular

gland and in serous cells of parotid gland of experimental group (Figure 9, 10, 11, 12).

Statistical analysis revealed that the experimental group (C and D) in both glands illustrated highly significant value in comparisons to control group (A and B) (Table.1).

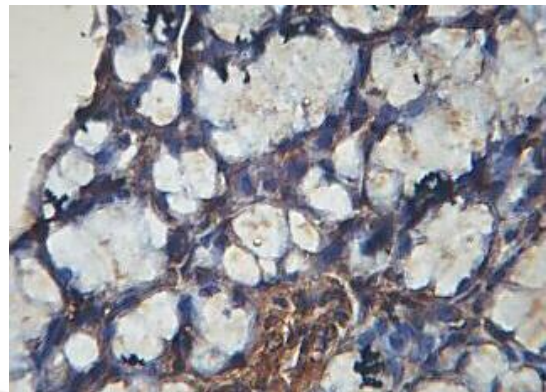


Figure 7: View of submandibular gland control group A, shows positive expression in myoepithelial and striated duct cells. DAB stain with hematoxylin counter stain X40.

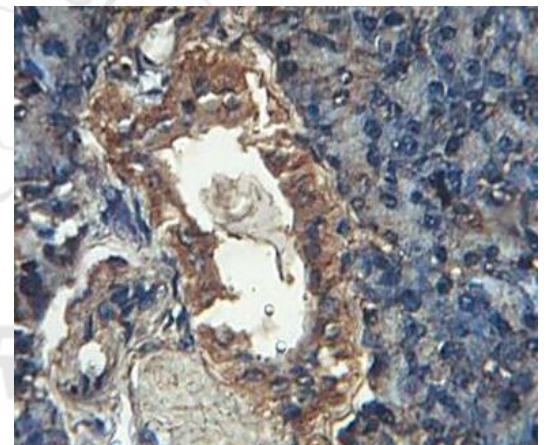


Figure 8: View of parotid control group B, shows positive expression in excretory duct cells and myoepithelial cells. DAB stain with hematoxylin counter stain X40.

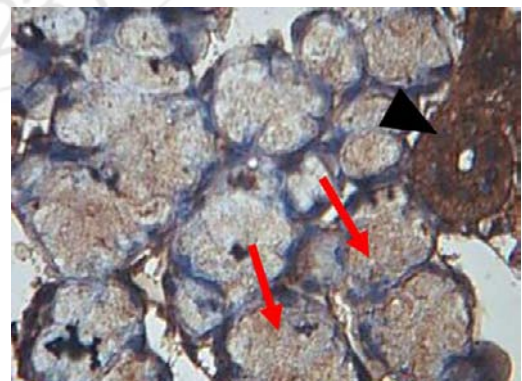


Figure 9: View of submandibular gland of 28 day experimental group shows strong positive ANXA1 antibody expression in striated duct cells (arrowhead), positive expression in mucous cells (red arrows). DAB stain with hematoxylin counter stain X40.

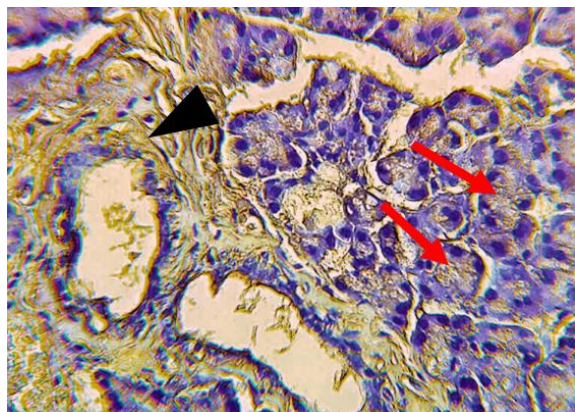


Figure 10: View of parotid gland of 28 day experimental group shows strong positive expression in excretory duct cells (arrowhead), weak cytoplasmic expression in serous cells (red arrows). DAB stain with hematoxylin counter stain X40

duct cells (arrowhead) and in myoepithelial cells (red arrows) and negative expression in serous cells DAB stain with hematoxylin counter stain X40.

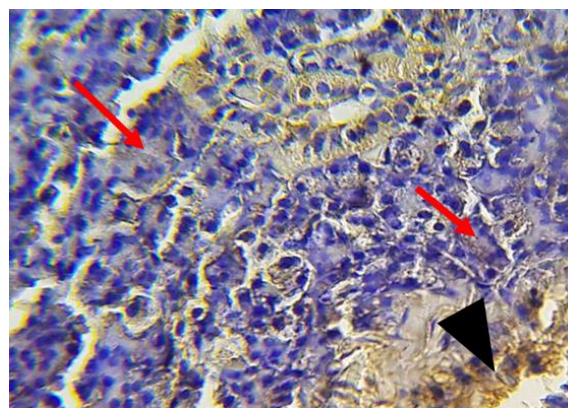


Figure 12: View of parotid gland of 28 day control group shows the positive ANXA1 antibody expression in the gland's duct cells (arrowhead) and in myoepithelial cells (red arrows). DAB stain with hematoxylin counter stain X40.

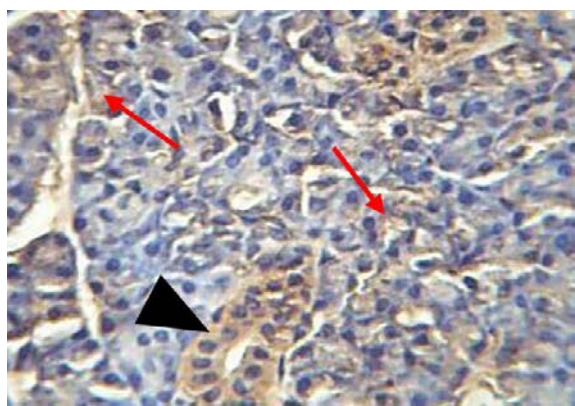


Figure 11: View of submandibular of 28 day control group shows the positive ANXA1 antibody expression in striated

Table -1: T-test for ANXA1 expression between groups in the same duration for both glands

Glands	Groups	Descriptive statistics					Groups' difference	
		N	Mean	S.D.	Min.	Max.	t-test	p-value
Parotid	A	10	9.167	0.361	8.699	9.767	-36.066	0.000 (HS)
	C	10	24.239	1.271	22.176	25.739		
SM	A	10	22.769	1.734	19.500	25.362	-32.030	0.000 (HS)
	C	10	47.353	2.236	47.595	55.085		
Parotid	B	10	9.153	0.359	8.564	9.756	-32.226	0.000 (HS)
	D	10	29.259	1.940	26.239	32.247		
SM	B	10	21.982	1.609	19.552	24.128	-27.037	0.000 (HS)
	D	10	51.430	2.493	41.754	50.234		

4. Discussion

The result of this study shows an increase in body weight in zoledronic acid- treated rats and this attributed to the ability of bisphosphonate to elevate total-body bone size, mass, and density due to inhibition of osteoblast and osteocyte apoptosis. This result agrees with previous study on bisphosphonate done by ⁽¹⁰⁾.

The light microscopic observation of this study reveals the presence of zymogen granules in the serous acini of both control and experimental groups. The zymogen granules were located at the apex of the serous cells as in 14 days and 28 days control groups with no difference in their location. Whereas, in 14 days and 28 days experimental groups, the

zymogen granules were diffused throughout the cytoplasm of the serous cells.

This pattern gives expectation that the zymogen granules increase in number in the serous cells of experimental groups' which agreed with Oliveira, 2014⁽⁵⁾, who explain that the secretory granules were aggregated in all parts of the cytoplasm of the secretory cells of serous acini from experimental specimens due to the interference of bisphosphonate in the secretory process of these cells by retarding exocytosis in a manner similar to that affecting the osteoclast.

The immunohistochemical findings revealed positive localization of ANXA1 in the salivary gland of both control and experimental groups. This finding was in agreement

with ^(11, 12); they reported the detection of small amount of ANXA1 in the submandibular and parotid glands.

Also strong positive expression of ANXA1 was found in the ductal and myoepithelial cells of both parotid and submandibular glands, whereas, the serous acini show weak or negative expression. These findings agree with previous immunohistochemical study performed by ⁽¹³⁾; they reported that in salivary glands the ANXA1 was positively expressed in the duct epithelium, whereas acinar cells were negative. They explained the expression of ANXA1 in the ductal epithelium of salivary organs is due to a functional duty in the exchange of ions and proteins.

In addition, weak positive immune-staining was found in many mucous cells of the submandibular gland especially in 28 days experimental group, and this finding was in agreement with ⁽¹²⁾.

As a conclusion, Zolendronate may affect the secretory mechanism of parotid and submandibular glands due to either slowing exocytosis or incrementing the protein synthesis. The positive localization of ANXA1 in the ductal cells of salivary glands may be due to functional exchange of ions and proteins. Increase expression of ANXA1 in acinar cells of salivary glands in zolendronate treated group may be due inflammatory effect of zoledronate.

References

- [1] Reynolds SD, Reynolds PR, Snyder JC, Whyte F, Paavola KJ, Stripp BR. CCSP regulates cross talk between secretory cells and both ciliated cells and macrophages of the conducting airway. *Am J Physiol Lung Cell Mol Physiol* . 2007; 293: L114–L123.
- [2] Lorber M. Branching and course of the larger ducts and accompanying structures within the rat submandibular salivary gland. *Am J Anat*. 1991;190: 133–156.
- [3] Drake M, Clarke B, Khosla S. Bisphosphonates: Mechanism of Action and Role in Clinical Practice. *Mayo Clin Proc*. 2008; 83(9): 1032–1045.
- [4] Yuasa T, Kimura S, Ashihara E, Habuchi T, Maekawa T. Zoledronic acid a multiplicity of anti-cancer action. *Curr Med Chem*. 2007; 14(20):2126-35.
- [5] Oliveira TC, Bradaschia-Correa V, Castro JR, Simoes A, Arana-Chavez VE. Ultrastructural and biochemical analysis of the effects of alendronate on salivary glands of young rats. *Archives of oral biology*. 2014; 59: 1307-1311.
- [6] Renshaw D, Korbonits M, Flower R, Perretti M, Fowkes R. Salivary annexin 1 has a diurnal rhythm but does not share an awakening response with cortisol at 30 min. *Endocrine Abstracts*. 2010; 21: 355.
- [7] Chen T, Berenson J, Vescio R, Swift R, Gilchick A, Goodin S, LoRusso P, Ma P. Pharmacokinetics and pharmacodynamics of zoledronic acid in cancer patients with bone metastases. *J Clin Pharmacol*. 2002; 42: 1228–1236.
- [8] Ibrahim A, Scher N, Williams G, Sridhara R, Li N, Chen G, Leighton J, Booth B, Gobburu J, Rahman A, Hsieh Y, Wood R, Vause D, Pazdur R. Approval summary for zoledronic acid for treatment of multiple

myeloma and cancer bone metastases. *Clin Cancer Res*. 2003; 9: 2394–2399.

- [9] Gao Y, Chen Y, Xu D, Wang J, Yu G. Differential expression of ANXA1 in human being gastrointestinal tissues and cancers. *BMC Cancer*. 2014, 14:520.
- [10] Strapple J. Efficacy of Bisphosphonates in Increasing Bone Mineral Density and Decreasing the Incidence of Fractures in Children with Osteogenesis Imperfecta. *School of Physician Assistant Studies* .2010: 195.
- [11] De BK, Misono KS, Lukas TJ, Mroczkowski B, Cohen S. A calcium-dependent 35-kilodalton substrate for epidermal growth factor receptor/kinase isolated from normal tissue. *J Biol Chem*. 1986; 261: 13784–13792 .
- [12] Cecchini M, Merigo F, Cristofolletti M, Osculati F, Sbarbati A. Immunohistochemical localization of Clara cell secretory proteins (CC10-CC26) and Annexin-1 protein in rat major salivary glands. *J Anat*. 2009; 214(5): 752–758.
- [13] Dreier R, Schmid KW, Gerke V, Riehemann K. Differential expression of annexins I, II and IV in human tissues: an immunohistochemical study. *Histochem Cell Biol*. 1998; 110: 137–148 .