

# Molluscum Contagiosum on the Nipple: An Unusual Site

Abhishek Chowdhury<sup>1</sup>, Utpal Goswami<sup>2</sup>

<sup>1</sup>Assistant Professor, Department of Pathology, IIMSAR & Dr. BC Roy hospital, Haldia

<sup>2</sup>Assistant Professor, Department of Pathology, IIMSAR & Dr. BC Roy hospital, Haldia

**Abstract:** *Molluscum contagiosum* is a common cutaneous infection caused by a double-stranded DNA poxvirus. Skin lesions classically present as small, pearly papules with central umbilication. Lesions can be found anywhere in the body, frequent sites being the face, trunk, and extremities of children, or genitals of young adults as a sexually transmitted infection. *Molluscum contagiosum* on the nipple is very rare and to the best of our knowledge, only five cases of nipple and areola of which two of nipple, have been reported so far. We report here this unusual case of molluscum contagiosum on the right nipple in a 23 year old female.

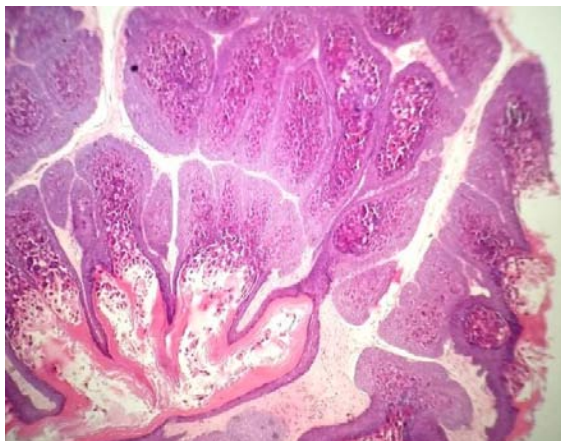
**Keywords:** Molluscum contagiosum, nipple, poxvirus, molluscum bodies, Henderson-Patterson bodies

## 1. Introduction

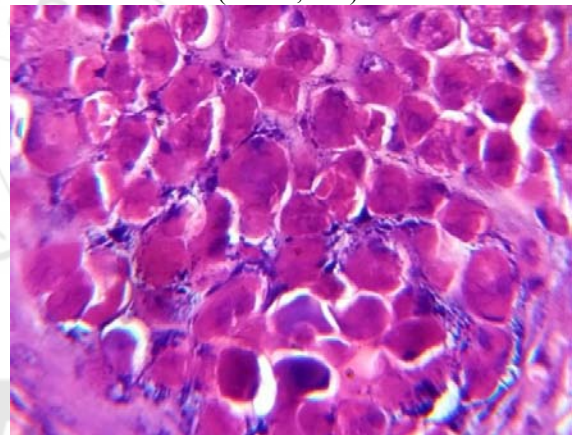
Molluscum contagiosum is cutaneous infectious disease caused by molluscum contagiosum virus which is a double stranded pox virus. The virus is transmitted by direct bodily contact, through minor abrasions, or indirectly via fomites. Among young adults, it is usually a sexually transmitted disease. Though relatively common in other parts, nipple as a site has been reported very rarely. We present here a case report of molluscum contagiosum of nipple in a 23 year old woman.

## 2. Case Report

A 23 yr old female presented to the breast outdoor clinic of our institution with a small pearly papule like lesion on the right nipple. Initially the papule was small which gradually increased to attain present size. The lesion was initially painless but recently turned mild painful. On examination, a papulonodular swelling was note. A clinical diagnosis of abscess was made. The lesion after excision was sent to histopathology department. Microscopy showed a lobulated proliferating epithelium in the dermis.(Figure 1 and figure 2) The epithelial cells contained cells with ovoid granular eosinophilic bodies (molluscum bodies), pushing the nucleus to the periphery. A diagnosis of molluscum contagiosum was made.



**Figure 1:** Lobulated proliferating epithelium in the dermis (H & E; 40x)



**Figure 2:** Molluscum bodies- ovoid granular eosinophilic bodies (H & E; 400x)

## 3. Discussion

Molluscum contagiosum is a viral infection of skin and mucus membranes that is caused by infection with the molluscum contagiosum virus, which causes characteristic pearly lesions on the surface of skin. Molluscum contagiosum can be acquired from skin to skin contact which may be during play, in a swimming pool, or through sexual contact.<sup>[1]</sup> It is primarily found in three distinct patient populations: children, sexually active adults, and immunocompromised individuals.<sup>[2]</sup> Incubation period varies between 14 and 50 days.<sup>[3]</sup> Inflammatory changes are infrequent. The lesions of molluscum contagiosum have a characteristic appearance. They are small (2-8mm), pearly, dome-shaped, skin colored papules with central umbilication. They can be solitary. However, they more commonly present in clusters, which have an average of 11-20 lesions.<sup>[4]</sup> Immunocompromised patients or those with atopic dermatitis may develop multiple, diffusely distributed lesions of molluscum contagiosum. The areola and nipple are unusual locations to develop molluscum contagiosum. Literature review showed only five previous cases of molluscum contagiosum nipple or areola.<sup>[5]</sup> The clinical diagnosis of molluscum contagiosum is usually

straightforward and histological examination is often unnecessary. However, when lesions lack the characteristic morphology or when the location is unusual, the diagnosis can be more challenging.<sup>[5]</sup>

Differential diagnosis includes basal cell carcinoma, benign adnexal tumor, condyloma accuminatum, cutaneous fungal infections (coccidioidomycosis, cryptococcosis, or histoplasmosis.), glandular (adenomatous) hyperplasia, keratoacanthoma, leiomyoma, Paget's disease, papilloma, popular granuloma annulare, syringoma and verruca vulgaris.<sup>[4,6,7]</sup>

The definitive diagnosis of molluscum contagiosum is made by visualizing molluscum bodies (Henderson-Patterson bodies), the pathognomonic feature of molluscum contagiosum virus.<sup>[7]</sup> Molluscum bodies are large, ovoid, homogenous, dense bodies found in the cytoplasm of infected keratinocytes. They often are sufficiently large to displace the nucleus to the cell periphery.<sup>[6]</sup>

#### 4. Conclusion

Molluscum contagiosum is viral infection that is rare in the nipple. Clinical diagnosis, though easy in typical locations, is difficult when nipple is the location. Thus, biopsy and histopathology is important in recognition and management.

#### References

- [1] Connell CO, Oranje A, Van Gysel D, Silverberg NB. Congenital molluscum contagiosum: Report of four cases and review of literature. *Pediatr Dermatol* 2008; 25:553-6.
- [2] Bandino JP, Wohltmann WE, Hivnor CM. What is your diagnosis? Giant molluscum contagiosum. *Cutis*. 2011 Oct; 88:164,170-172.
- [3] Xiaowei Xu, Lori A. Erickson, David E. Elder. Diseases caused by viruses. In: Elder David E, Elenitsas Rosalie, Johnson Bennett L, Murphy George F, editors. *Lever's Histopathology of the Skin*. 9<sup>th</sup> ed. Lipincott Williams & Wilkins.
- [4] Brown J, Janniger CK, Schwartz RA, Silverberg NB. Childhood molluscum contagiosum. *Int J Dermatol*. 2006 Feb; 45(2):93-99. Review.
- [5] Hoyt Brian S, Tschen Jaime A, Cohen Philip R. Molluscum contagiosum of the areola and nipple: case report and literature review. *Dermatol Online J*. 2013, 19(7)
- [6] Kumar N, Okiro P, Wasike R. Cytological diagnosis of molluscum contagiosum with an unusual clinical presentation at an unusual site. *J Dermatol Case Rep*. 2010; 4(4):63-65.
- [7] Hanson D, Diven DG. Molluscum contagiosum. *Dermatol Online J*. 2003; 9:2.

#### Author Profile

**Dr. Abhishek Chowdhury**, MD Pathology, Asst Prof, Deptt of Pathology, IIMSAR, Haldia

**Dr. Utpal Goswami**, MD Pathology, Asst Prof, Deptt of Pathology, IIMSAR, Haldia