

Ageing Effects on Menisco-Femoral Ligament

Ghalawat N¹, Rathee S. K.²

Department of Anatomy, Pt. B. D. Sharma, PGIMS, Rohtak

Abstract: *The menisco-femoral ligament is one of the most important accessory ligament of the knee joint having both functional and clinical importance. This ligament acts in synergy with the cruciate ligament. In the case of rupture of posterior cruciate ligament, function is performed by posterior menisco-femoral ligament. It is important to have the knowledge of this ligament in arthroscopic surgeries. On MRI examination this ligament can be mistaken for osteochondral and meniscal fragment. Present study was aimed to study the morphometry of this ligament. The study was conducted on 50 human cadaveric knee joints in which the length and the midpoint thickness of this ligament were measured using Vernier caliper with accuracy of 0.01mm in two age groups. The length and thickness of this ligament was found to be greater in the younger age group in comparison to the older age group with statistical significance ($p < 0.05$). So it could be concluded that the length and thickness of this ligament decreased with the increasing age. This indicates that the posterior menisco-femoral ligament is a regressive structure which degenerates with the increasing age.*

Keywords: knee joint, menisco-femoral ligament, cruciate ligament.

1. Introduction

Menico-femoral ligament as the name suggests is an extension of the posterior horn of lateral meniscus towards lateral aspect of medial femoral condyle close to the attachment of posterior cruciate ligament. Radioevitch proposed menisco-femoral ligament as third cruciate ligament (Radioevitch et al. 1931). In French, Germany and Russian literature, this ligament is known as Robert's ligament (Kaplan et al. 1957). Menisco-femoral ligament are the two ligaments that connect posterior horn of lateral meniscus to the intercondylar area of femur. One of these passes anterior to posterior cruciate ligament and is known as ligament of Humphry or anterior menisco-femoral ligament. The other passes posterior to the posterior cruciate ligament and is known as the ligament of Wrisberg or posterior menisco-femoral ligament (Gupte et al. 2002). Anterior menisco-femoral ligament is closely related to the anterior surface of the posterior cruciate ligament. The attachment of the anterior menisco-femoral ligament cannot be seen from front. When tibia is rotated medially on the femur the posterior horn of lateral meniscus can be seen and attachment of anterior menisco-femoral ligament can be visualized posterior. The other ligament passes posterior to posterior cruciate ligament and is known as ligament of Wrisberg or posterior menisco-femoral ligament. This ligament is a distinct structure continuous with posterior horn of the lateral meniscus. As fatty tissue is abundant in this area, it is necessary to trace any band of fibrous tissue to make sure that ligament is in fact the posterior menisco-femoral ligament (Yamamoto et al. 1991; Felle et al. 1995).

Amis et al reported that menisco-femoral ligaments act in synergy with the posterior cruciate ligament when it is intact and act in similar manner to the posterior cruciate ligament when it gets ruptured. The oblique orientation of menisco-femoral ligaments suggested that they may be involved in limiting tibial internal rotation but a selective cutting study in progress at the authors laboratory has not reported any significant effect (Amis et al. 2002). Menisco-femoral ligament in addition to their known function in assisting the posterior cruciate ligament to resist tibio femoral posterior drawer, they also have a significant role in reducing contact

stresses in the lateral compartment. Their retention in posterior cruciate ligament and meniscal surgery is therefore to be advised (Amadi et al. 2008).

Menisco-femoral ligament have mechanical role in the knee, acting as secondary restraints to tibial posterior drawer. Posterior oblique fibre of posterior cruciate ligament could be misdiagnosed as a posterior menisco-femoral ligament (Gupte et al. 2003).

2. Material and Methods

The present study was conducted on 50 knee joints in two age groups ranging from 20-40 years and 41-60 years in the department of Anatomy at Pt. B.D.Sharma Post Graduate Institute of Medical Sciences Rohtak.

Exclusion criteria

Following cases were excluded from study:

1. Cadavers in which any traumatic injury to the knee.
2. Cadavers in which knee joint were distorted.
3. Cadavers with any surgical scar marks on the knee.

The anterior menisco-femoral ligament is posterior to anterior cruciate ligament and anterior to the posterior cruciate ligament so it could be visualized only when the knee joint is exposed from anterior aspect. The posterior menisco-femoral ligament is posterior to the posterior cruciate ligament and hence could be visualized best when knee joint is exposed from posterior aspect.

Steps of dissection as proposed by Poynton et al⁸.

Anterior approach to expose the anterior menisco-femoral ligament

First a longitudinal incision was given on the medial border of patella (fig.1a) and then skin was reflected. After removal of skin and subcutaneous tissue a longitudinal incision was made in the capsule on each side of the joint and these incisions were connected transversely at the upper tibial margin. The capsular flap including the patella and its ligamentous attachments were reflected superiorly. A constant fat pad at the femoral insertion of the anterior cruciate ligament was removed. The knee was then flexed to

expose the anterior cruciate ligament which was divided transversely. This revealed the posterior cruciate ligament.

The limb was turned to prone position. A midline incision (fig 2a) was given on the back of the knee and popliteal vessels and nerve were dissected and retracted medially to expose the posterior joint capsule. A longitudinal incision was given in the capsule over each femoral condyle. These incisions were joined in shape of an inverted U (fig 2b). The capsular flap was reflected inferiorly and carefully separated from underlying structure before being removed completely from its distal attachment. The posterior menisco-femoral ligament was seen posterior to the posterior cruciate ligament (fig 2c).

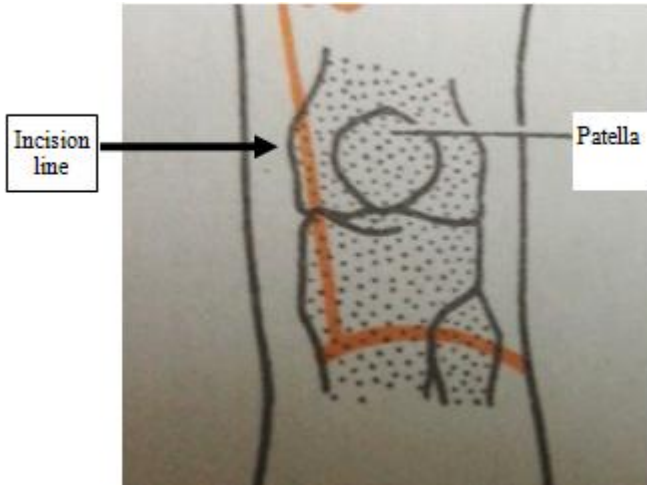


Figure 1 (a): Showing incision line on anterior aspect⁹.

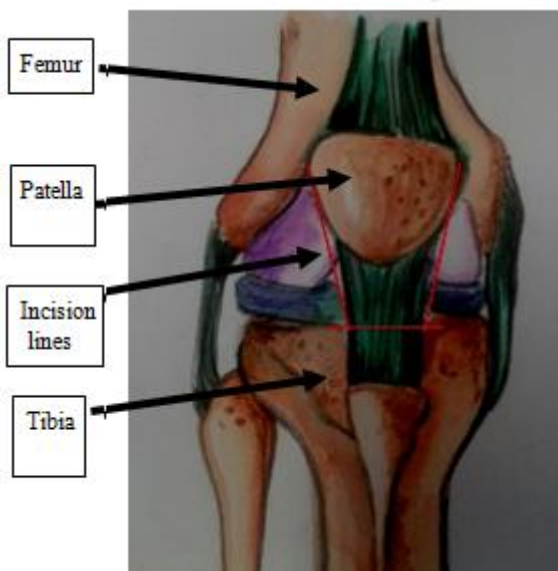


Figure 1 (b): Showing incision lines in capsule of knee joint.

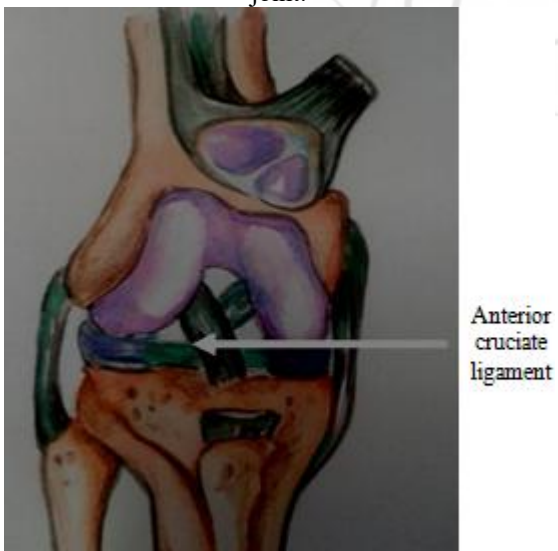

Figure 1 (c): Showing anterior cruciate ligament.

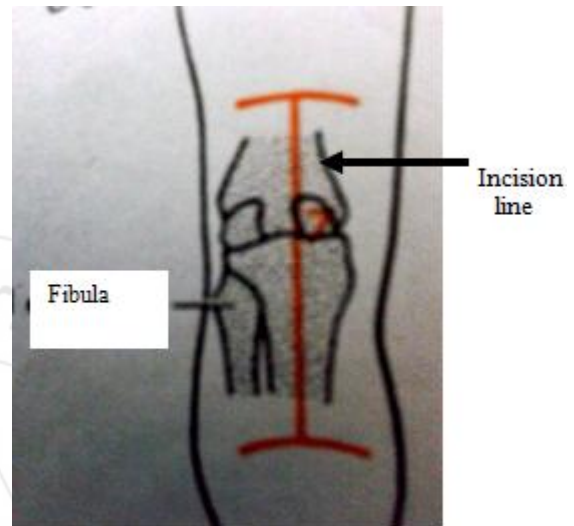


Figure 2 (a): Showing incision given on posterior aspect of knee joint⁴⁹.

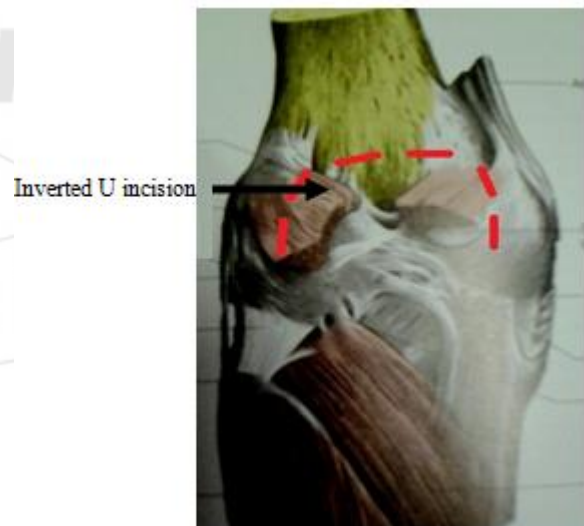

Figure 2 (b): Showing posterior approach.⁵⁰

Posterior approach to expose the posterior menisco-femoral ligament

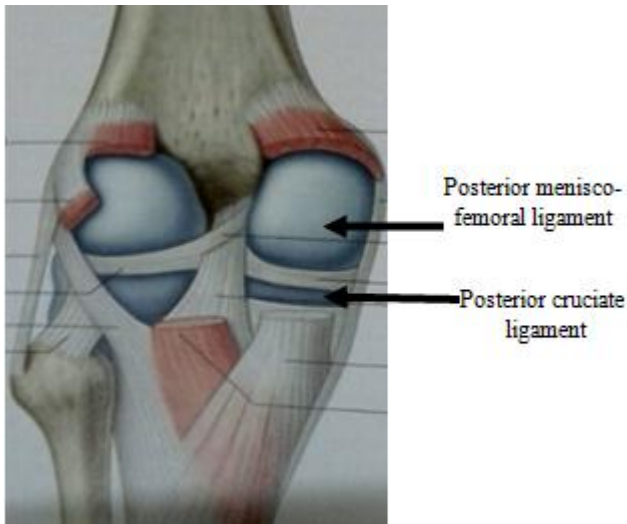


Figure 2 (C): Showing PMFL⁵⁰

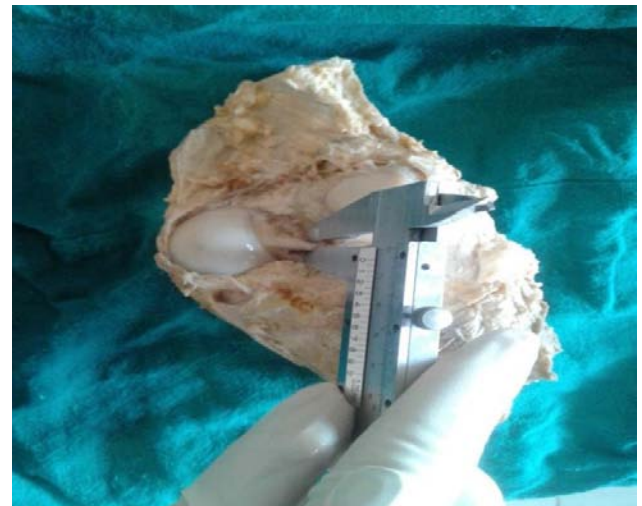
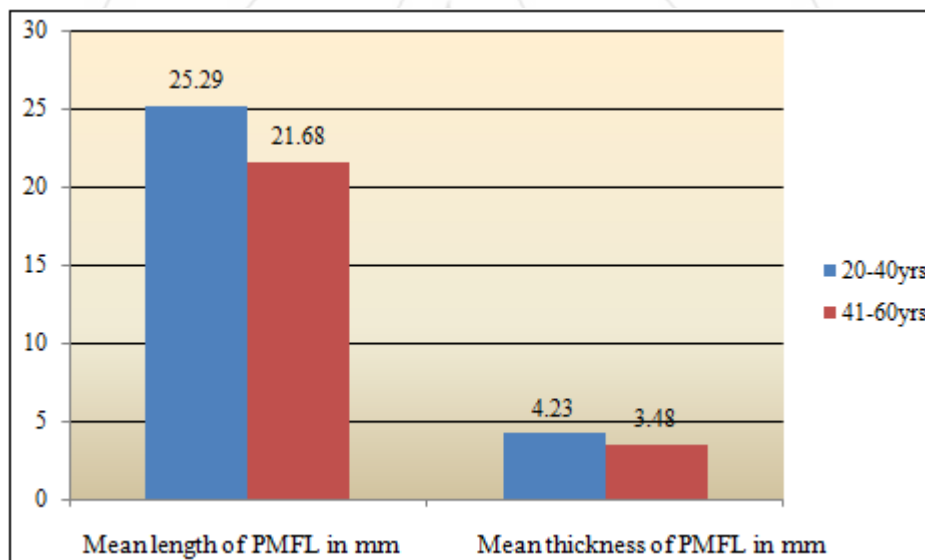


Figure 2: Showing the measurement of the mid-point thickness of posterior menisco-femoral ligament.

3. Results

Finding made out of the studies are as follows:-

1. Dimensions of posterior menisco-femoral ligament (PMFL)



Graph 1: Showing the mean length and mean thickness of posterior menisco-femoral ligament in two age groups studied

Table 1: Mean length and mean thickness of posterior menisco-femoral ligament (PMFL) in two age groups.

Length and thickness of posterior menisco-femoral ligament (PMFL)	Age group 20-40 years	Age group 41-60 years	p value
Mean thickness of PMFL at midpoint (mm)	4.23±0.8	3.48±0.74	<0.05

Mean thickness of posterior menisco-femoral ligament was 4.23±0.8 mm in 20-40 years age group while it was 3.48±0.74 mm in 41-60 years age group showing that the thickness of posterior menisco-femoral ligament decreased with age and p value was found to be statistically significant (< 0.05).

4. Discussion

Knee joint is one of the most complex joint of our body. It has an important role in carrying body weight and in walking, running and jumping. Large numbers of ligaments are present in relation with knee joint. Menisco-femoral ligament is one of the most important accessory ligaments of the knee. It extends from the posterior horn of lateral meniscus to the lateral aspect of medial femoral condyle close to the femoral attachment of the posterior cruciate ligament.

Knowledge of menisco-femoral ligament in lower animals is also important to know if menisco-femoral ligament is developing more or disappearing i.e. evolutionary point of view. Lee-Minor et al. (1990) reported the posterior

menisco-femoral ligament to be present always in animals and sometimes absent in men. He proposed that in man posterior menisco-femoral ligament is a regressive structure in nature which is in support to our study. In present study mean length and mean thickness of menisco-femoral ligament was measured in two age groups of north Indian population showing that the mean length and mean thickness decreased with the increasing age and p value was found to be statistically significant (0.05).

Gupte et al. (2002) conducted his cadaveric study on the population of London. He also reported regarding the degeneration of the menisco-femoral ligament in the older population. This also in support of our present study.

5. Conclusions

In present study it was found that the length and thickness of posterior menisco-femoral ligament decreased with the increasing age. So it can be concluded that posterior menisco-femoral ligament is a regressive structure.

References

- [1] Radoïévitch S. Les ligaments des ménisques interarticulaires du genou. Annales d'anatomie pathologique. 1931; 8: 400-13.
- [2] Kaplan EB. Discoid lateral meniscus of the knee joint: Nature, mechanism and operative treatment. The knee joint. J Bone Joint Surg. 1957; 39-A: 77-87.
- [3] Gupte CM, Smith A, Jamieson N, Bull AMJ, Amis AA. Meniscofemoral ligaments structural and material properties. 2002; 35: 1623-29.
- [4] Yamamoto M, Hirohata K. Anatomical study on the menisco-femoral ligaments of the knee. Kobe J Med Sci. 1991; 37: 209-26.
- [5] Felle P, Wan AC. The menisco-femoral ligaments. Clin Anat. 1995; 8(5): 323-6.
- [6] Amis AA, Bull AMJ, Jamieson N, Smith A, Gupte CM. Menisco-femoral ligaments structural and material properties. J Biomech. 2002; 35: 1623-9.
- [7] Amadi HO, Gupte CM, Lie DT, McDermott ID, Bull AM. A biomechanical study of the menisco-femoral ligaments and their contribution to contact pressure reduction in the knee. Knee Surg Sports Traumatol Arthrosc. 2008; 16(11): 1004-8.
- [8] Gupte CM, Bull AMJ, Thomas RD, Amis AA. The meniscofemoral ligaments: secondary restraints to the posterior drawer. Analysis of anteroposterior and rotatory laxity in the intact and posterior-cruciate-deficient knee. J Bone Joint Surg Br. 2003; 85: 765-73.
- [9] Poynton AR, Javadpour SM, Finegan PJ, Brien M. The menisco-femoral ligament of the knee. J Bone Joint Surg. 1997; 79B(2): 327-30.
- [10] Romanes GJ. Cunningham's manual of practical anatomy. 15th ed. Oxford medical publication. 2011. p.130-151. William PL.
- [11] Gray's Anatomy. 39thed. Churchill Livingstone: Edinburg; 1995. p.1479-84.
- [12] Lee- Minor JM. Comparative morphology of the lateral meniscus of the knee in primates. J Anat. 1990; 170: 161-71.

- [13] Gupte CM, Smith A, McDermott ID, Bull AMJ, Thomas RD, Amis AA. Menisco-femoral ligaments revisited: incidence, age, correlation and clinical implications. J Bone Joint Surg (Br). 2002; 84: 846-56