

Preoperative Endovascular Embolization of Juvenile Nasopharyngeal Angiofibroma

Sirakov S.¹, Sirakov A.²

UH "St. Ivan Rilski"–Sofia City

The juvenile nasopharyngeal angiofibroma (JNA) comprises only 0.5% of head and neck neoplasms. This is a rare tumor, pathoanatomical characterized as benign vascular tumor with frequent localization in pterygopalatine fossa in adolescent males. Despite the absence of malignant nature, the juvenile nasopharyngeal angiofibroma is known to have locally invasive dissemination and progressive growth, which although rarely is associated with involvement of the intracranial space, with or without massive hemorrhage. The angiofibroma blood supply from the carotid system understandably draws the attention to the endovascular procedure focusing on its positive contribution to the treatment of such lesions. Besides being a "gold standard" in determining the feeding vessels, angiography serves as a main procedure in tumor treatment - embolization prior the surgical excision.

Keywords: preoperative, endovascular, embolisation, nasopharyngeal, juvenile angiofibroma

1. Introduction

The juvenile nasopharyngeal angiofibroma (JNA) comprises only 0.5% of head and neck neoplasms (Herman, 1999; Tewfik, 1999). This is a rare tumor, pathoanatomical characterized as benign vascular tumor with frequent localization in pterygopalatine fossa in adolescent males. Despite the absence of malignant nature, the juvenile nasopharyngeal angiofibroma is known to have locally invasive dissemination and progressive growth, which although rarely is associated with involvement of the intracranial space, with or without massive hemorrhage.

From an epidemiological standpoint, this hypervascular tumor manifests strong predilection towards men during the childhood and teenage years (14-15 years old), despite the reported range of 10-25 years of age (Ardehali, 2010.).

The most commonly used classification scheme of JNA (Radkowski, 1996) separates the tumor of 3 main stages and several subtypes, depending on its extension and the involvement of surrounding structures.

- a) **I**
 - **Ia:** limited to the nasal cavity / nasopharynx
 - **Ib:** extension into at least one or more paranasal sinuses
- b) **II**
 - **IIa:** minimal extension through sphenopalatine foramen and pterygomaxillary fossa
 - **IIb:** full occupation of pterygomaxillary fossa and engagement of the maxillary cells in front or expanding in the orbit by engaging the tissues placed beneath
 - **IIc:** extension beyond the pterygomaxillary fossa and the infratemporal fossa (Radkowski 1996)
- c) **III:** intracranial extension

Although rare, intracranial tumor spreading consists 20-36% of these cases (Close, 1989; Wiatrak, 1993) and is usually performed through the front cranio cerebral fossa or in the pituitary para sellar area. Despite the great mortality associated with the intracranial expansion, there is dura penetration is observed very rarely.

The maxillary artery is the most common source, which is supposed to create the JNA tumors. Other known vessels are the ascending pharyngeal artery, internal, external and common carotid artery. Although rarely, the presence of collateral feeding blood flow can be observed.

The clinical manifestation ranges from unilateral nasal obstruction, frequent epistaxis, impaired nasal drainage, and a typical engagement of the surrounding nasopharyngeal structures – hearing worsening or hearing loss, engaging the Eustachian tube, rhinorrhea, hard palate deformation, hyposmia or anosmia. The physical finding often is a smooth lobulated reddish tumor mass.

The angiofibroma blood supply from the carotid system understandably draws the attention to the endovascular procedure focusing on its positive contribution to the treatment of such lesions. Besides being a "gold standard" in determining the feeding vessels, angiography serves as a main procedure in tumor treatment – embolization prior the surgical excision. Also, the balloon occlusion test of the carotid system helps to build an exact operational strategy (Danesi, 2008).

The preoperative embolization should be performed within 24-72 hours prior to the section by using the NBCA, ethylene-vinyl alcohol copolymer (Onyx), microspheres and particles. The embolization aims a total occlusion of the feeding arteries, which in turn leads to significant reduction in intraoperative blood loss, as well as reduction of the tumor volume (Moulin, 1995; Li, 1998; Liu, 2002). Complications vary between 6-9% (Andrade, 2007) as the most of them are adverse carotid embolization, blindness as a result of the ophthalmic artery embolization, massive necrosis of skin and soft tissues, facial nerve paralysis.

2. Clinical Case

A male adolescent at the age of 12 was administered at the clinic regarding breathing difficulties and frequent nose bleeds, and bilateral headache since 6 months. After a consultation with an otorhinolaryngology specialist, a CT and MR with contrast media of head and neck were

conducted, that revealed a vascularlesion of 3-5 cm in the skull base area engaging the pterigom axilarfossa, expansion in the nasopharynx with clear evidence of intracranial extension –Radkowskist age III.

The patient was administered general anesthesia and a catheterization by Seldinger technique was performed. The

selective transfe moral catheterization of the internal and external carotid system revealed a large hyper vascular tumor with angiographic evidence of primary blood supply from branches of the left maxillary artery along with data for discrete blood supply from the ascending pharyngeal artery.

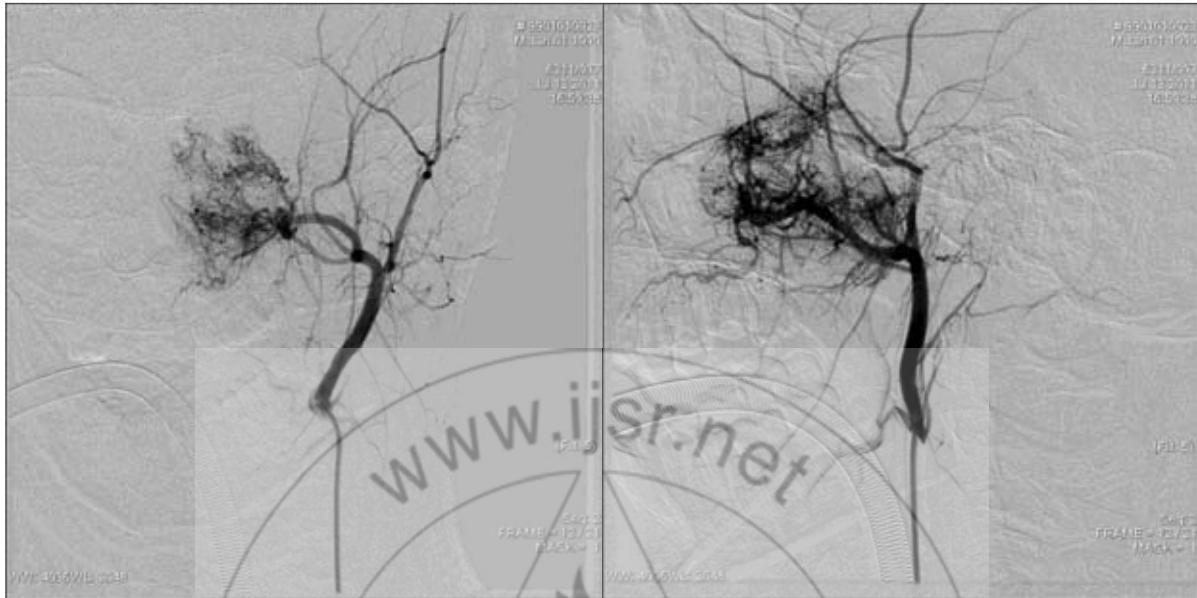


Figure 1: Selective angiography of the left external carotid artery imaging the Tu vasculature

Control injections of contrast media in the internal lateral carotidartery and the ipsilateral vertebral artery were made in order to exclude pathological communications with feeding vessels.

After initiating the procedure the patient was administered 2500 units of heparin to increase the activated partial thrombo plastintime.

Using a micro catheter and micro introducer a selective catheterization of the feeding maxillary artery branches was performed and they were embolized with Onyx.



Figure 2: Selective angiography of a maxillaris on the left

The post-embolization angiography revealed a total occlusion and no residual vessels feeding the formation

while introducing the contrast media in the left external carotid artery.

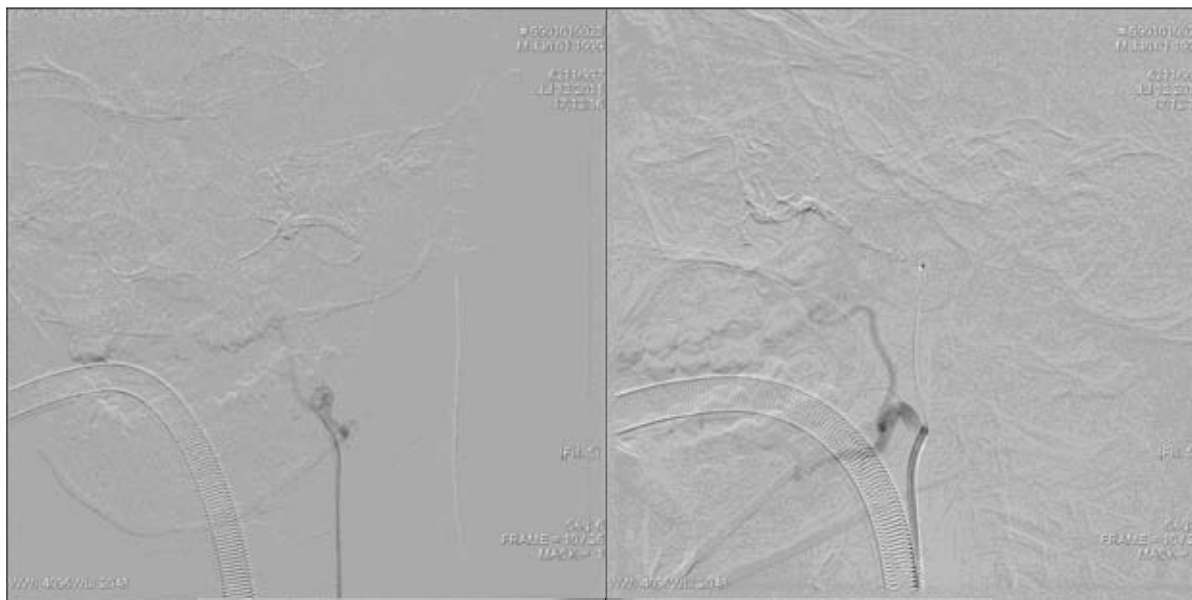


Figure 3: Post-embolization angiography, imaging a total occlusion of a. maxillaris.

The patients' vital signs were stable during all procedure stages and after the manipulation he was monitored within 24 hours in ICU. After 72 hours the patient was performed an operative tumor mass resection. The intraoperative bleeding during the tumor extraction was minimized as a result of the total angiofibroma devascularization.

3. Conclusion

The preoperative endovascular embolization of juvenile nasopharyngeal angiofibroma is preferred from most authors being a safe, reliable and feasible method for devascularization in more than 70% of the cases (Glad, 2007), and as a result a significant reduction in the intraoperative bleeding volume is observed and thus substantially reducing the rate of complications during surgery. Our experience showed that the preoperative Onyx administration may offer an effective and even higher devascularization rate compared to other embolic agents.

References

- [1] Tang IP, Shashinder S, GopalaKrishnan G, Narayanan P. Juvenile nasopharyngeal angiofibroma in a tertiary centre: Ten-year experience. Singapore Med J. 2009 Mar; 50 (3): 261-4.
- [2] Gates GA, Rice DH, Koopmann CF, Schuller DE. Flutemide induced regression of angiofibromas. Laryngoscope. 1992; 102: 641-4
- [3] Atalar M, Solak O, Müderris S. Juvenile nasopharyngeal angiofibroma: Radiologic evaluation and pre-operative embolization. KBB-Forum. 2006; 5: 58-61
- [4] Cansiz H, Güvenç MG, Sekercioğlu N. Surgical approaches to juvenile nasopharyngeal angiofibroma. J Craniomaxillofac Surg. 2006; 34: 3-8
- [5] Önerci TM, Yücel OT, Öğretmenoğlu O. Endoscopic surgery in treatment of juvenile nasopharyngeal angiofibroma. Int J Pediatr Otorhinolaryngol 2003; 67: 1219-25
- [6] Bradoo RA, Joshi AA, Pahtan FA, Kalel KP. The push-

- pull technique in the management of giant JNAs. Bombay Hospital Journal, Vol. 50, No. 2, 2008
- [7] Pile-Spellman J. Endovascular therapeutic neuro radiology. In: Taveras JM. Neuroradiology. 3rd ed. Williams & Wilkins. Baltimore 1996.
- [8] Davis KR. Embolization of epistaxis and juvenile nasopharyngeal angiofibromas. AJR 1987; 148: 209-218. [PMID: 3024474]
- [9] Koç C, Özdem C, Arıkan OK, Beriat K. Clinical value of pre-operative polyvinyl alcohol embolization in juvenile nasopharyngeal angiofibroma. Turk Arch Otolaryngol 2001; 39: 267-272
- [10] Sirakov S., Kamenov B., Penkov M., Marinov M. Complex arteriovenous malformation – a case report. Rentgenologia & Radiologia, 2014, LIII: 61-64
- [11] Sirakov S., Penkov M., Sirakov A., Minkin K., Ninov K. Preoperative Embolization of Hemangioblastomas. International Journal of Science and Research (IJSR), Volume 6 Issue 1, January 2017, ISSN (Online): 2319-7064,