

Endovascular Embolization of a Spinal Arteriovenous Fistula

S. Sirakov¹, H. Hristov², A. Sirakov³, K. Ninov⁴

Abstract: Spinal arteriovenous fistulas are rare formations with severe clinical symptoms and consequences, if left untreated. Over the past few decades, considerable progress has been made for the clarifying and correct interpretation of these lesions by conducting selective angiographies. Good knowledge of anatomical characteristics and pathophysiology of spinal arteriovenous fistulas has led to the development and implementation of endovascular treatment of this pathology. The development and evolution of diagnostic procedures, interventional treatment and surgery have contributed to the more effective treatment of spinal arteriovenous fistulas. We present a clinical case from our experience in endovascular treatment of spinal arteriovenous malformations.

Keywords: endovascular, embolisation, spinal fistula, arteriovenous malformation

1. Case Report

The case refers to a 46-year old patient with progressive weakness of the lower limbs having developed for the last 24 months and presenting with inability to walk independently in the last 90 days. On the conducted nuclear magnetic resonance imaging, an arteriovenous fistula was visualized, as the presence of intradurally dilated venous

vessels was most pronounced in the thoracic spine. A part of the abnormal venous vessels was possible to be traced in the cervical and lumbar segments. Pronounced myelopathy at Th7-Th8 level and a similar one in the caudal direction, reaching and involving the medullar cone, were also observed.

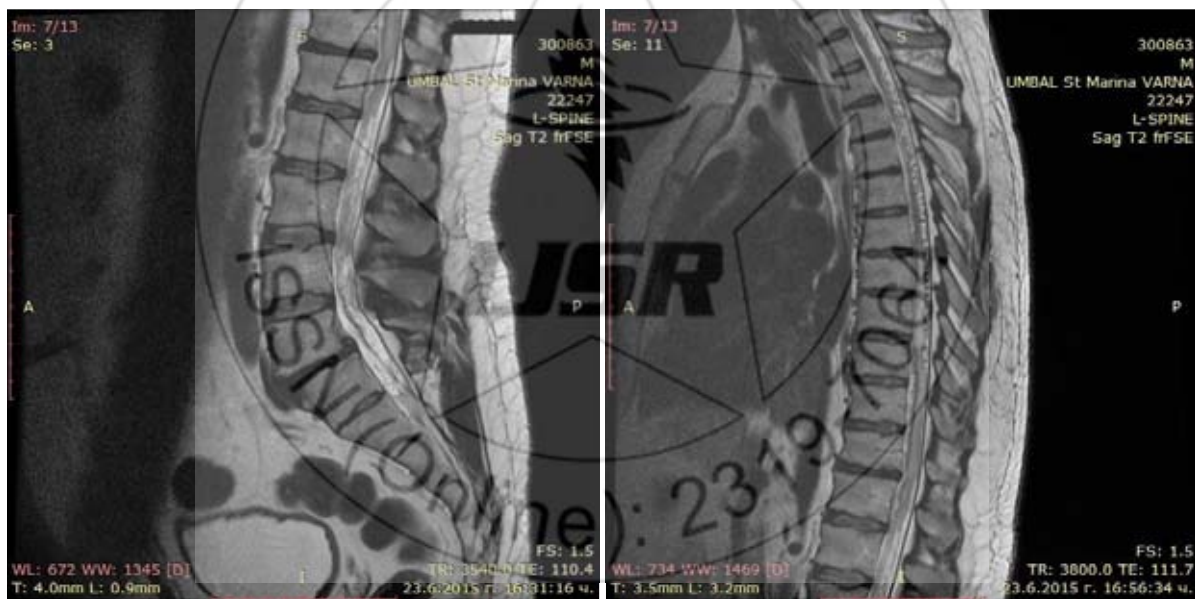

Figure 1: Images of the vascular structures, running a long distance intradurally and compressing the dural sac (with presented myelopathy in the thoracic and lumbar segments)

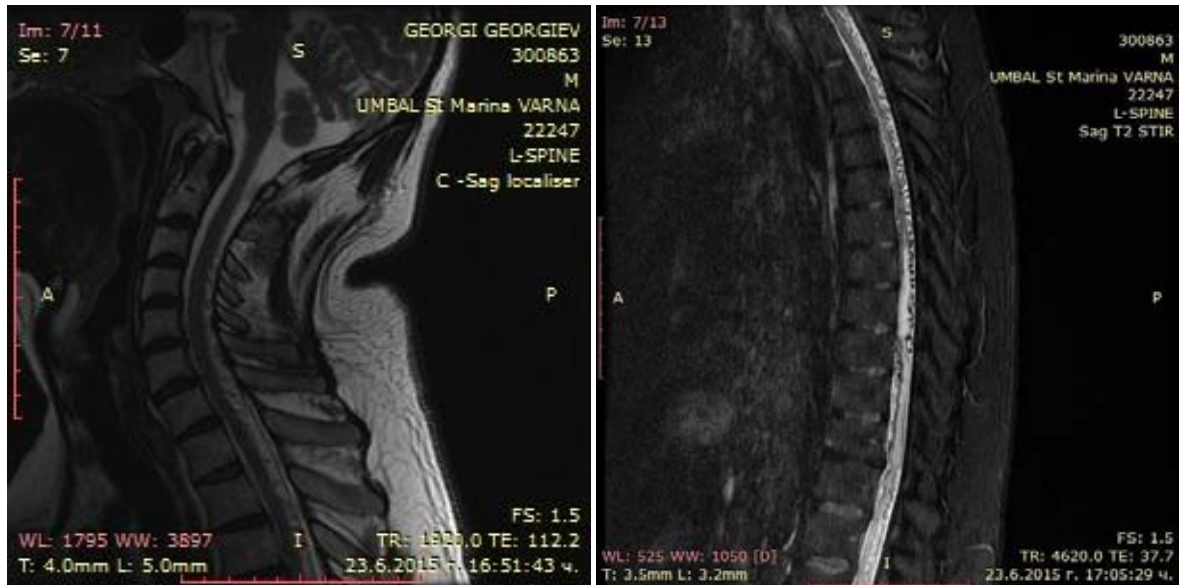

Figure 2: Images of the intradurally dilated venous vessels, traced in the cervical spine as well

The patient was referred for a conventional digital subtraction angiography. Both vertebral arteries and the anterior spinal arteries at Th4-L4 levels bilaterally were visualized. On the conducted selective angiography, a pathologic arteriovenous shunt at Th6-Th7 level on the left and a similar one with smaller flow at Th6-Th7 level on the

right were visualized. The pathological shunts filled with the contrast medium a severely dilated and tortuously folded vein, located intradurally and running into cranial and caudal direction.




Figure 3: Images of the pathological shunts at Th6-Th7 level on the right and Th6-Th7 level on the left

After consulting a multidisciplinary team of neurosurgeons and radiologists, we decided to conduct a surgery with the aim to interrupt the pathological shunts bilaterally.

Intra-operatively, the pathological shunt at Th6-Th7 level on the right was visualized and interrupted completely through surgical means (placing a clip), but the pathological shunt at the same level on the left, visualized on the conventional angiography, was not found.

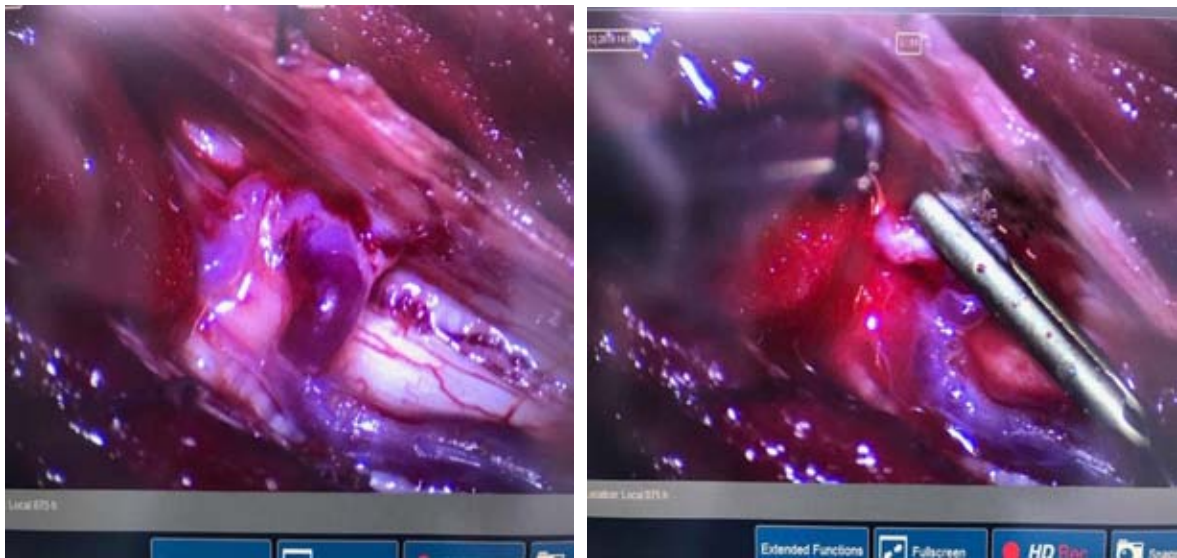


Figure 4: Intra-operative interruption of the pathological shunt at Th6-Th7 level on the right

On the subsequent control angiography, conducted 45 days after the surgery, no recanalization of the surgically removed shunt at Th6-Th7 level on the right was visualized, but the shunt at the same level on the left, described preoperatively, was still persistent. Due to the location of the shunt and its anatomical specificity, making impossible its localization during surgery, we decided to perform an endovascular embolization of the persistent shunt.

The endovascular embolization was conducted without general anesthesia. The right femoral artery was catheterized

by Seldinger. A selective catheterization of the left anterior spinal artery was realized at Th6-Th7 level. By introducing Apollo microcatheter or SilverSpeed microguidewire, the level of the pathological shunt was reached. By administering the long-lasting, non-adhesive embolic agent Onyx, we realized a total embolization of the residual arteriovenous fistula. On the conducted control angiography, no filling of the described dilated vein, located intradurally, was visualized. The patient suffered no complications and complaints after the embolization period.



Figure 5: Embolization of the pathological shunt at Th6-Th7 level on the left

Following the performed combined surgical and endovascular therapy, improvement of the patient's neurological symptoms was registered.

Discussion

We report a case of a relatively rare vascular pathology of the spinal cord, where again it was confirmed that the better understanding of anatomical characteristics and pathophysiology of a certain vascular malformation leads to

more effective treatment option. In our case, we preferred surgical treatment, which is the gold standard for spinal arteriovenous malformations (I type), but in the presence of a residual pathological shunt, inaccessible for the classic surgery, endovascular treatment was conducted to achieve radical results. In certain vascular malformations, the multidisciplinary treatment approach results in a more effective treatment.

References

- [1] Krings T, Geibprasert S. Spinal dural arteriovenous fistulas. *AJNR Am J Neuroradiol* 2009;30:639–48
- [2] Krings T, Mull M, Gilsbach JM, et al. Spinal vascular malformations. *Eur Radiol* 2005;15:267–78
- [3] Barnwell SL, Dowd CF, Davis RL, et al. Cryptic vascular malformations of the spinal cord: diagnosis by magnetic resonance imaging and outcome of surgery. *J Neurosurg* 1990;72:403–07
- [4] Rosenblum B, Oldfield EH, Doppman JL, et al. Spinal arteriovenous malformations: a comparison of dural arteriovenous fistulas and intradural AVM's in 81 patients. *J Neurosurg* 1987;67:795–802
- [5] Mourier KL, Gobin YP, George B, et al. Intradural perimedullary arteriovenous fistulae: results of surgical and endovascular treatment in a series of 35 cases. *Neurosurgery* 1993;32:885–91; discussion 891
- [6] Biondi A, Merland JJ, Hodes JE, et al. Aneurysms of spinal arteries associated with intramedullary arteriovenous malformations. I. Angiographic and clinical aspects. *AJNR Am J Neuroradiol* 1992;13:913–22
- [7] Di Chiro G, Doppman JL. Endocranial drainage of spinal cord veins. *Radiology* 1970;95:555–60
- [8] Hurst RW, Kenyon LC, Lavi E, et al. Spinal dural arteriovenous fistula: the pathology of venous hypertensive myelopathy. *Neurology* 1995;45:1309–13
- [9] Jellema K, Tijssen CC, van Gijn J. Spinal dural arteriovenous fistulas: a congestive myelopathy that initially mimics a peripheral nerve disorder. *Brain* 2006;129:3150–64
- [10] Merland JJ, Riche MC, Chiras J. Intraspinous extramedullary arteriovenous fistulae draining into the medullary veins. *J Neuroradiol* 1980;7:271–320
- [11] Djindjian M, Djindjian R, Hurth M, et al. Steal phenomena in spinal arteriovenous malformations. *J Neuroradiol* 1978;5:187–201
- [12] el Mahdi MA, Rudwan MA, Khaffaji SM, et al. A giant spinal aneurysm with cord and root compression. *J Neurol Neurosurg Psychiatry* 1989;52:532–35
- [13] Spetzler RF, Detwiler PW, Riina HA, et al. Modified classification of spinal cord vascular lesions. *J Neurosurg* 2002;96:145–56
- [14] Gueguen B, Merland JJ, Riche MC, et al. Vascular malformations of the spinal cord: intrathecal perimedullary arteriovenous fistulas fed by medullary arteries. *Neurology* 1987;37:969–79
- [15] Nakstad PH, Hald JK, Bakke SJ. Multiple spinal arteriovenous fistulas in *AJNR Am J Neuroradiol* 32:798–808 May 2011 www.ajnr.org 807 Klippel-Trenaunay-Weber syndrome treated with platinum fibre coils. *Neuroradiology* 1993;35:163–65
- [16] Ricolfi F, Gobin PY, Aymard A, et al. Giant perimedullary arteriovenous fistulas of the spine: clinical and radiologic features and endovascular treatment. *AJNR Am J Neuroradiol* 1997;18:677–87
- [17] Rodesch G, Hurth M, Alvarez H, et al. Angio-architecture of spinal cord arteriovenous shunts at presentation: clinical correlations in adults and children—the Bicetre experience on 155 consecutive patients seen between 1981–1999. *Acta Neurochir (Wien)* 2004;146:217–26; discussion 226–27. *Epub* 2004 Feb 23
- [18] Arnaud O, Bille F, Pouget J, et al. Epidural arteriovenous fistula with perimedullary venous drainage: case report. *Neuroradiology* 1994;36:490–91
- [19] Clarke MJ, Patrick TA, White JB, et al. Spinal extradural arteriovenous malformations with parenchymal drainage: venous drainage variability and implications in clinical manifestations. *Neurosurg Focus* 2009;26:E5
- [20] Weingrad DN, Doppman JL, Chretien PB, et al. Paraplegia due to posttraumatic pelvic arteriovenous fistula treated by surgery and embolization: case report. *J Neurosurg* 1979;50:805–10
- [21] Kawabori M, Hida K, Yano S, et al. Cervical epidural arteriovenous fistula with radiculopathy mimicking cervical spondylosis. *Neurol Med Chir (Tokyo)* 2009;49:108–13
- [22] Willinsky R, terBrugge K, Lasjaunias P, et al. The variable presentations of craniocervical and cervical dural arteriovenous malformations. *Surg Neurol* 1990;34:118–23
- [23] Szajner M, Weill A, Pötin M, et al. Endovascular treatment of a cervical paraspinal arteriovenous malformation via arterial and venous approaches. *AJNR Am J Neuroradiol* 1999;20:1097–99
- [24] Willinsky R, terBrugge K, Montanera W, et al. Spinal epidural arteriovenous fistulas: arterial and venous approaches to embolization. *AJNR Am J Neuroradiol* 1993;14:812–17
- [25] Djindjian M, Djindjian R, Rey A, et al. Intradural extramedullary spinal arterio-venous malformations fed by the anterior spinal artery. *Surg Neurol* 1977;8:85–93
- [26] Djindjian R, Hurth M, Houdart R. Medullary angiomas, segmentary or generalized vascular dysplasias and phacomatoses [in French]. *Rev Neurol (Paris)* 1969;121:109–11
- [27] Djindjian R, Hurth M, Houdart R. Spinal angiomas, segmentary vascular dysplasia and phacomatosis [in French]. *Rev Neurol (Paris)* 1971;124:121–42
- [28] Houdart E, Gobin YP, Casasco A, et al. A proposed angiographic classification of intracranial arteriovenous fistulae and malformations. *Neuroradiology* 1993;35:381–85
- [29] Ricolfi F, Manelfe C, Meder JF, et al. Intracranial dural arteriovenous fistulae with perimedullary venous drainage: anatomical, clinical and therapeutic considerations. *Neuroradiology* 1999;41:803–12
- [30] Melki JP, Riche MC, Reizine D, et al. Simultaneous bifemoral retrograde arteriography under pressure: first stage in angiographic exploration of the spine and spinal cord [in English, French]. *J Neuroradiol* 1986;13:62–70
- [31] Gobin YP, Rogopoulos A, Aymard A, et al. Endovascular treatment of intracranial dural arteriovenous fistulas with spinal perimedullary venous drainage. *J Neurosurg* 1992;77:718–23
- [32] Aminoff MJ, Logue V. The prognosis of patients with spinal vascular malformations. *Brain* 1974;97:211–18
- [33] Hurth M, Houdart R, Djindjian R, et al. Arteriovenous malformations of the spinal cord: clinical, anatomical and therapeutic consideration: a series of 150 cases. *Prog Neurol Surg* 1978;9:238–66

- [34] Bostrom A, Krings T, Hans FJ, et al. Spinal glomus-type arteriovenous malformations: microsurgical treatment in 20 cases. *J Neurosurg Spine* 2009; 10:423–29
- [35] Connolly ES Jr, Zubay GP, McCormick PC, et al. The posterior approach to a series of glomus (type II) intramedullary spinal cord arteriovenous malformations. *Neurosurgery* 1998;42:774–85, discussion 785–86
- [36] Tai PA, Tu YK, Liu HM. Surgical treatment of spinal arteriovenous malformations: vascular anatomy and surgical outcome. *J Formos Med Assoc* 2001;100:389–96
- [37] Zozulya YP, Slin'ko EI, Al-Qashqish II. Spinal arteriovenous malformations: new classification and surgical treatment. *Neurosurg Focus* 2006;20:E7
- [38] Djindjian R, Cophignon J, Rey A, et al. Superselective arteriographic embolization by the femoral route in neuroradiology: study of 50 cases. II. Embolization in vertebromedullary pathology. *Neuroradiology* 1973;6:132–42
- [39] Doppman JL, Di Chiro G, Ommaya A. Obliteration of spinal-cord arteriovenous malformation by percutaneous embolisation. *Lancet* 1968;1:477
- [40] Biondi A, Merland JJ, Reizine D, et al. Embolization with particles in thoracic intramedullary arteriovenous malformations: long-term angiographic and clinical results. *Radiology* 1990;177:651–58
- [41] Rodesch G, Hurth M, Alvarez H, et al. Embolization of spinal cord arteriovenous shunts: morphological and clinical follow-up and results—review of 69 consecutive cases. *Neurosurgery* 2003;53:40–49; discussion 49–50
- [42] Corkill RA, Mitsos AP, Molyneux AJ. Embolization of spinal intramedullary arteriovenous malformations using the liquid embolic agent, Onyx: a single-center experience in a series of 17 patients. *J Neurosurg Spine* 2007;7:478–85
- [43] Konan AV, Raymond J, Roy D. Transarterial embolization of aneurysms associated with spinal cord arteriovenous malformations: report of four cases. *J Neurosurg* 1999;90:148–54
- [44] Hida K, Iwasaki Y, Goto K, et al. Results of the surgical treatment of perimedullary arteriovenous fistulas with special reference to embolization. *J Neurosurg* 1999;90:198–205
- [45] Riche MC, Melki JP, Merland JJ. Embolization of spinal cord vascular malformations via the anterior spinal artery. *AJNR Am J Neuroradiol* 1983;4:378–81
- [46] Oran I, Parildar M, Derbent A. Treatment of slow-flow (type I) perimedullary spinal arteriovenous fistulas with special reference to embolization. *AJNR Am J Neuroradiol* 2005;26:2582–86
- [47] Cho KT, Lee DY, Chung CK, et al. Treatment of spinal cord perimedullary arteriovenous fistula: embolization versus surgery. *Neurosurgery* 2005;56: 232–41, discussion 232–41
- [48] S. Sirakov, Ch. Bachvarov, M. Penkov, A. Sirakov, B. Kamenov, Y. Todorov Direct embolization of complex carotid-cavernous fistula. *Roentgenologia radiologia* , 2016 , LV: 35-38