

Single- Stage Transdiaphragmatic Surgical Approach to Liver & Lung Hydatid Cysts – A Retrospective Evaluation

Dr. Santosh Kumar Pandey¹, Dr. Subhash Minda²

^{1,2}Department of Cardiothoracic and Vascular sciences, IPGME&R and SSKM Hospital, Kolkata, West Bengal, India, zip code 700020

Abstract: ***Introduction:** Hydatid cysts remain a clinical problem in our country. Synchronous pulmonary & hepatic hydatid disease may occur in 4% to 25% of cases. **Aim:** To evaluate the efficacy and safety of single stage transdiaphragmatic posterolateral thoracotomy approach for synchronous pulmonary and hepatic cyst. **Methodology:** Retrospective selection of patients underwent single stage procedure was done. In our institution over a period of 3 years (2012-2015), 39 cases of concomitant lung & liver hydatid were noted. Both pulmonary & hepatic hydatid was addressed in single sitting through transdiaphragmatic approach. Pulmonary cysts were excised first via a posterolateral thoracotomy and hepatic hydatid cyst was evacuated after phrenotomy. **Result:** All patients were approached through single stage transdiaphragmatic posterolateral thoracotomy. Post-operative complications included empyema in 2, bronchopleural fistula in 1, excessive biliary discharge in 2. There was no hospital death. **Conclusion:** A single stage transdiaphragmatic posterolateral thoracotomy for extraction of pulmonary & liver hydatid cyst is an effective & safe surgical technique with few complications.*

Keywords: Hydatid cyst, Transdiaphragmatic approach, Synchronous pulmonary and hepatic hydatid cyst

1. Introduction

Hydatid cysts are infestations caused by larval forms of *Echinococcus granulosus*. It can affect different organs. Liver is the most common organ to be affected and next common is the lung. Synchronous lesion of lung and liver is also not rare (4% to 25%). Most effective treatment for synchronous lesion is surgery. Surgical management can be a two stage procedure, dealing liver and lung separately at two occasions or single stage with two different incisions, thoracotomy and laparotomy. Literature have mentioned single stage procedure to be feasible and safe. Most common complication is infection in form of empyema and bleeding. This study has retrospectively evaluated single stage transdiaphragmatic approach for lung and liver hydatid in 39 cases done in our institute.

Aims:

To evaluate the efficacy and safety of single stage transdiaphragmatic posterolateral thoracotomy approach for synchronous pulmonary and hepatic cyst.

2. Materials and Methods

The study evaluated 39 cases of concomitant lung and liver hydatid cyst between 2012 to 2015. All were operated through single stage transdiaphragmatic approach. The patients were evaluated in terms of age, sex, clinical findings, location of cyst in liver and lung, post operative complications and total stay in ICU and hospital. The diagnosis was made through various combinations of chest radiography, computed tomography (CT) of the chest and abdomen & abdominal USG. (Fig 1,2,3).

Locations of pulmonary and hepatic cysts is mentioned in table 1.

Table 1: Location of cysts

Location of Cysts with Pulmonary Cyst

Location (Right lung)	No. of Cyst
Upper lobe	6
Middle lobe	4
Lower lobe	29
Total	39

Location of Cysts with Hepatic Cysts

Right lobe	33
Left lobe	06
Total	39

3. Surgical Technique

All patients were intubated with double lumen endotracheal tube. Epidural catheter inserted in all patients. 37 patients underwent right posterolateral thoracotomy and 2 patients were approached through b/l posterolateral thoracotomy. First the pulmonary cyst is addressed then phrenotomy is done for approaching hepatic cyst. (fig 4, 5) Utmost attention is given to prevent spillage of cystic fluid. Cystostomy and capitonnage done in every pulmonary cyst and lobectomy needed in single patient. Omentoplasty required in 12 patients in hepatic cyst.

4. Result

The study included 39 patients of which 21 were male and 18 female. All patients range from 8 to 62 years. Most frequent presenting symptoms were abdominal pain, cough, dyspnea & chest pain. All patients underwent single stage posterolateral thoracotomy through transdiaphragmatic approach. (Table 2). Most frequent complication were empyema and biliary leak, bronchopleural fistula was reported in 4% and recurrence in 2% of the patients. All patients were discharged within 6 to 10 days with 2 to 4 days ICU stay. There was no mortality in this study. (Table 3)

Table 2: Characteristics of the patients

Characteristics of patients	
Variable	No. of Patients
Male/female	21/18
Age range (years)	8 - 60
Operations	
Right posterolateral thoracotomy	37
B/L posterolateral thoracotomy	02
Cystotomy and Capitonnage(Lung)	38
Lobectomy	01
Cystotomy and Capitonnage (Liver)	39
Omentoplasty (Liver)	12

Postoperative complications

Variable No. of Patients Empyema 4 (9%) Excessive biliary discharge 4 (9%) Bronchopleural fistula 2 (4%) Recurrent hepatic hydatid cyst 1 (2%) Intensive care unit stay (days) 2-4 Hospital stay (days) 6-10

5. Discussion

Hydatid disease is a parasitic infection. The Liver(50-70%), followed by Lung (20-30%) is the most common site of infection in adults. Synchronous pulmonary & hepatic hydatid disease may occur in 4-25 % of cases. Investigate the possibility of additional cysts in patients with either a pulmonary or hepatic cyst. When hydatid cysts are present in both, combined resection via a right posterolateral thoracotomy followed by phrenotomy is desirable. Treatment of pulmonary hydatid cyst is essentially surgical. We used albendazole only for intact cysts and as prophylaxis before surgery on complicated cysts. The basis of current surgical treatment of pulmonary hydatid cyst is to eradicate the parasite, to prevent intraoperative rupture & subsequent dissemination, managing the residual cavity with maximum preservation of lung parenchyma^(2,3). Because of great variability in pathology of pulmonary hydatid cysts, surgical treatment must be tailored to each case.⁽³⁾ Aribas and colleagues⁽⁶⁾ also removed hepatic cysts transdiaphragmatically in 49 of 141 patients with a pulmonary hydatid cyst. Our complication rates were comparable to those in previous reports.^(4,5)

6. Conclusion

We conclude that concomitant pulmonary and subdiaphragmatic hepatic hydatid cysts can be treated effectively and safely in a single-stage operation via a right posterolateral thoracotomy and phrenotomy.

References

- [1] Erdogan A, Ayten A, Kabukcu H, Demircan A. One-stage transthoracic operation for the treatment of right lung and liver hydatid cysts. *World J Surg* 2005;29:1680-6.
- [2] Peleg H, Best LA, Gaitini D. Simultaneous operation for hydatid cysts of right lung and liver. *J Thorac Cardiovasc Surg* 1985;90:783-7.

- [3] Symbas NP, Aletras H. Hydatid disease of the lung. In: Shields TW, Locicero J, Ponn RB, Rusch VW, editors. *General thoracic surgery*. 6th ed. New York: Lippincott Williams & Wilkins, 2004:1298-308
- [4] Yagci G, Ustunsoz B, Kaymakcioglu N, Bozlar U, Gorgulu S, Simsek A, et al. Results of surgical, laparoscopic, and percutaneous treatment for hydatid disease of the liver: 10 years experience with 355 patients. *World J Surg* 2005;29:1670-9.
- [5] Saidi F, Rezvan-Nobahar M. Intraoperative bronchial aspiration of ruptured pulmonary hydatid cysts. *Ann Thorac Surg* 1990;50:631-6.
- [6] Aribas OK, Kanat F, Turk E, Kalayci MU. Comparison between pulmonary and hepatopulmonary hydatidosis. *Eur J Cardiothorac Surg* 2002;21:489-96.

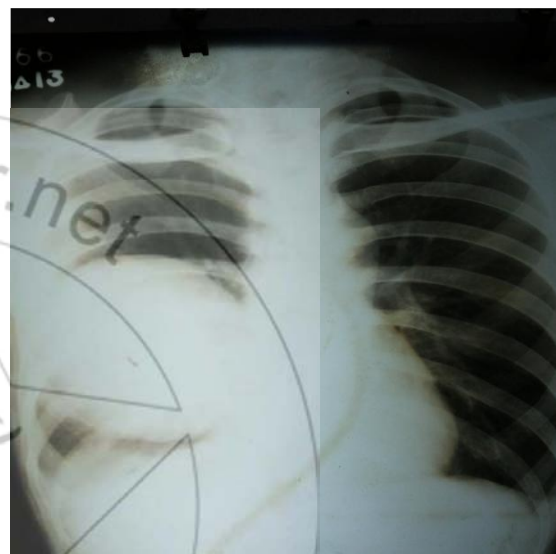


Figure 1: X-Ray showing lung hydatid cyst

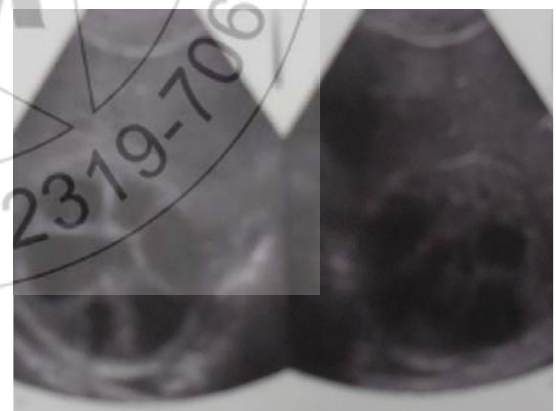


Figure 2: USG showing hydatid cyst in liver

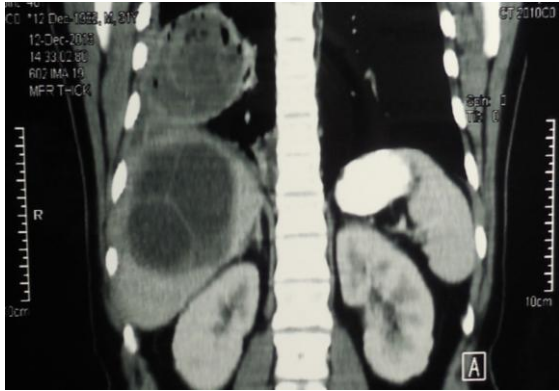


Figure 3: CT showing lung and liver hydatid

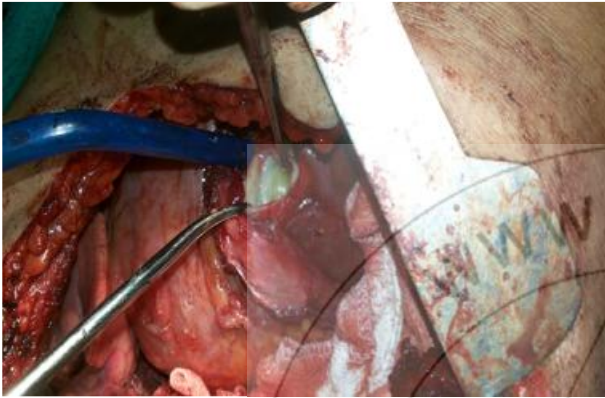


Figure 4: Operating photograph showing opened liver hydatid cyst

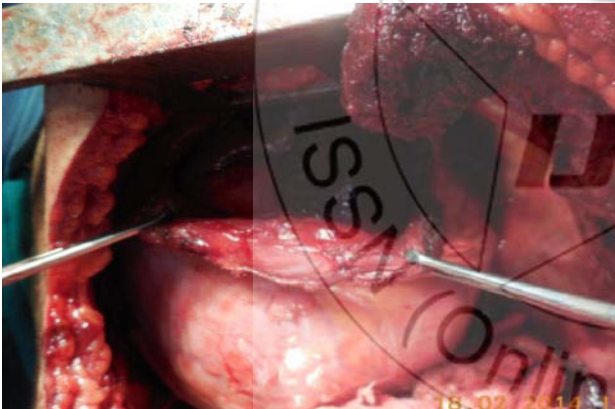


Figure 5: Phrenotomy showing intact liver cyst