

# Imaging Evaluation of Mediastinal Tumours with Pathological Correlation

Dr. Girish Ghodadara<sup>1</sup>, Dr. Purvi Desai<sup>2</sup>, Dr. Rahul Sharma<sup>3</sup>

<sup>1</sup>Resident Doctor

<sup>2</sup>Associate Professor

Resident Doctor

**Abstract:** Mediastinum is a site for neoplastic and non-neoplastic lesions and many of them present as mediastinal mass. The location and composition of these lesions are critical in arriving at a clinical diagnosis. This study of different mediastinal masses is aimed to find out frequency of malignancy, their compartmental distribution and characteristics through computed tomography. **Materials & Methods:** A prospective study was conducted at New civil hospital, Surat during the period 2015-2016 with a total of 60 patients with suspected mediastinal masses. The major variables were age, clinical symptoms, mass location, imaging studies, and tissue pathology. All patients were subjected to investigations like chest X-ray, CT scan along with guided fine needle aspiration/biopsy for definite tissue diagnosis. **Result:** Sixty patients enrolled in this study were analysed and their imaging findings compared. 39 cases (65%) were malignant and 21 cases (35%) were benign. Majority of the lesions were seen in the anterior compartment, followed by posterior compartment. Bronchogenic carcinoma and lymphoma were the common malignant tumours seen in the anterior and middle compartments of the mediastinum, whereas neurogenic tumors mostly benign, were the common tumours in the posterior compartment. **Conclusion:** CT scan is an effective tool in evaluating mediastinal masses. Moreover, sampling the mass is important in obtaining pathological diagnosis. Surgery, radiotherapy and chemotherapy either as single or in combination are the main modalities of treatment. Accurate preoperative pathological diagnosis, invasion and infiltration of the tumour were the key to successful treatment.

**Keywords:** Mediastinal Neoplasm, Mediastinal Compartment, Chest Xray, Computed Tomography (CT Scan), Thymoma

## 1. Introduction

The mediastinum is essentially the centre of the thoracic cavity. Mediastinum is demarcated by the pleural cavities laterally, the thoracic inlet superiorly and the diaphragm inferiorly. It is further divided into anterior (prevascular), middle (visceral) and posterior mediastinum (paravertebral) and anatomical boundaries are clearly defined by CT scan. Mediastinal masses are quite heterogeneous. Tumours both benign and malignant (primary and metastatic) are seen arising from all the three compartments. Division of mediastinum into compartments is useful to narrow down the differential diagnosis of mediastinal masses, assist in getting histopathology (biopsy) and help in deciding type of treatment required. Hence, there is a need for establishing an early specific diagnosis.

There is an increase in the frequency and prevalence of primary mediastinal tumours. The type of primary mediastinal mass seen varies with the age of the patients, like neurogenic tumours in children, while thymic tumours, lymphomas, and carcinomas in adults. One half to two thirds of the mediastinal masses in children are asymptomatic in contrast to adults in whom one third to one half of the masses appear as symptomatic. Usual symptoms at presentation are cough, chest pain, fever/chills and dyspnoea. Localising symptoms are secondary to tumour invasion (respiratory compromise; paralysis of the limbs, diaphragm and vocal cords; Horner syndrome; superior vena cava syndrome), while systemic symptoms are typically due to the release of excess hormones, antibodies or cytokines. Myasthenia gravis is associated with 30% to 50% of patients with Thymoma and is more frequently seen in women.

Computed tomography is the most important imaging modality in the evaluation of mediastinal mass. Characterization on CT scan is based on specific attenuation of air, fat, water and calcium. High resolution multiplanar reformation images display the detailed anatomical relationship of the tumour with the adjacent structures. Magnetic Resonance imaging has high contrast resolution and multiplanar capability, thereby providing additional information as to location of tumour and extent of intraspinal involvement and is a preferred modality in evaluating neurogenic tumours. Diffusion weighted MRI is another special application that unveils minute metabolic and biophysical differences between tissues. The mean apparent diffusion coefficient for the malignant mediastinal entities could be significantly lower than that for the benign diseases. To achieve the histopathology and the type of mediastinal mass, different approaches have been adopted based on the location of the mass. The tissue diagnosis is particularly important in case of anterior mediastinal masses because it guides us to the proper treatment. However, complete resection can result in the definitive diagnosis and treatment in case of posterior compartment masses. Radiology guided needle biopsy and endoscopic needle biopsy, anterior mediastinotomy, mediastinoscopy, video-assisted thoracic surgery (VATS) and certain open approaches like sternotomy and thoracotomy are among the available techniques for obtaining tissue diagnosis. Accurate pre-treatment diagnosis and evaluation of extent of infiltration of adjacent structures like blood vessels and trachea are the key to successful treatment.

The present study is aimed to evaluate the mediastinal tumours using multidetector Computed Tomography (CT)

Volume 5 Issue 12, December 2016

[www.ijsr.net](http://www.ijsr.net)

Licensed Under Creative Commons Attribution CC BY

Scan, to differentiate between benign and malignant mass lesions and for establishing histological typing.

## 2. Materials and Methods

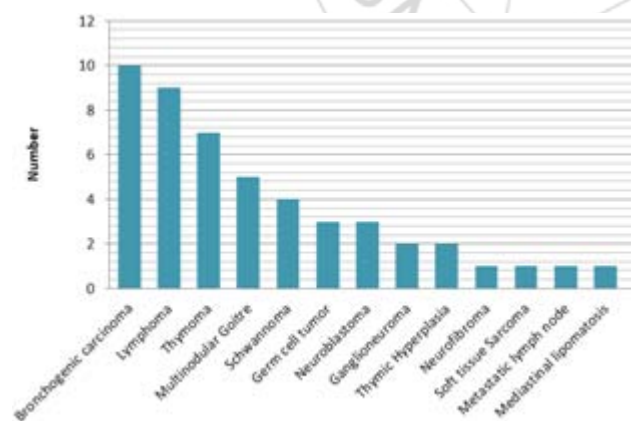
This prospective study was conducted on 60 patients with mediastinal masses seen at New civil hospital, Surat during the period 2015-2015. Patients of all ages and both sexes are included. Chest x-ray and Computed Tomography scan and guided Fine Needle Aspiration Cytology/Biopsy were performed on all patients. Detailed clinical examination was done. The patient's data were reviewed in terms of age, clinical symptoms, sex, mass location, CT characteristics and tissue pathology. The FNAC was performed using a 23-gauge needle. Tran thoracic Tru-cut biopsy were taken in 12 patients and specimens were fixed and stained by Haematoxylin and Eosin stain.

## 3. Results

Out of 60 cases studied, 36 cases (60%) were males, 24 (40%) females. 25% (n=15) of the patients were children. Median age is 44 years. Among the three compartments, majority of cases (n=28, 47%) were seen in anterior mediastinum followed by middle (n=14, 23%) and posterior mediastinum (n=15, 25%). Mass involving both anterior and middle mediastinum was seen in 3 cases (5%).

Malignant tumours were more commonly seen in the anterior compartment (35%, n=21). Benign tumours are more in the posterior compartment (17%, n=10).

The most common presenting symptoms were dyspnoea (51%) and chest pain (38%) followed by cough and fever. Other symptoms are neck swelling, dysphagia, and dilated veins over the chest. Patients with malignant tumours are more symptomatic than those with benign tumours.



### Pathology of Mediastinal Tumours

Computed tomography followed by trans-thoracic needle aspiration was applied for tissue diagnosis. Out of 50 cases, 38(76%) patients' definite tissue diagnosis was obtained by doing FNAC who underwent repeat histopathological study. 12 cases were diagnosed by doing trans-thoracic needle biopsy.

Among the malignant tumours, bronchogenic carcinoma was the most common (n=10). Lymphoma (n=9), thymoma

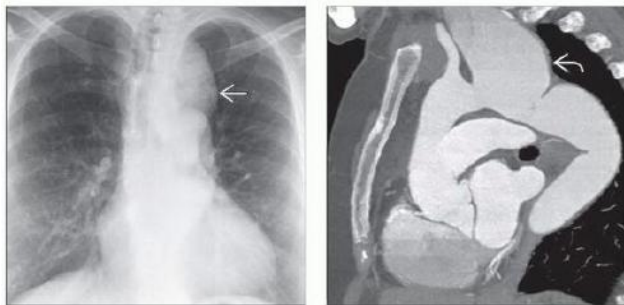
(n=7), germ cell tumour (n=3), malignant neural tumour (n=3), soft tissue sarcoma (n=1), and metastatic carcinoma (n=1) are the other malignant mediastinal tumours. The histological types seen among 24 cases (48%) involving anterior mediastinum, were lymphoma (n=6), thymoma (n=4), thymic hyperplasia (n=2), multinodular goiter (n=5), bronchogenic carcinoma (n=4), germ cell tumour (n=2) and metastatic lymph nodal mass (n=1). The breakup of middle mediastinal masses (n=11, 22%) include carcinoma lung (n=6), lymphoma (n=3), and thymoma (n=2). One case of germ cell tumour, one case of mediastinal lipomatosis, and one case of thymoma are found to be involving both anterior and middle mediastinum. Posterior mediastinal masses comprised 24% (n=12) of the total mediastinal masses and included 10 neural tumours and one case (2%) of soft tissue sarcoma and one case of paravertebral abscess. The breakup of 10 neural tumours showed Schwannoma (n=4), neuroblastoma (n=3), ganglioneuroma (n=2) and neurofibroma (n=1).

In this study, CT scan showed mediastinal invasion in 68% of cases predominantly invading tracheobronchial tree and mediastinal great vessels, due to bronchogenic carcinoma, lymphoma and germ cell tumours. Majority of tumours are heterogeneous (55%) in nature due to necrosis, cystic change or haemorrhage, seen in bronchogenic carcinoma, lymphoma, germ cell tumour, peripheral nerve sheath tumour and thymoma. Homogenous tumours were seen in 4% (n=3) cases of lymphoma. They show mild-to-moderate contrast enhancement and compressing the airway and cardiovascular structures. CT scan showed minimally enhancing tumours in 32% (n=16), moderate enhancement in 3%(n=2), non-enhancing tumours in 10% of cases. Multinodular goitres are encapsulated and lobulated mass with inhomogeneous density with cystic areas and calcifications. They show markedly contrast- enhancement. Thymomas show mild-to-moderate contrast enhancement with occasionally focal haemorrhage, necrosis, cyst formation. Thymic hyperplasia appear as diffuse symmetric enlargement of the gland, smooth contour and normal vessels, whereas vascular invasion and pressure symptoms are seen in thymomas. At CT scan, neuroblastomas are heterogeneous and non-encapsulated lesions with haemorrhage, necrosis, calcification and cystic degeneration.

## 4. Discussion

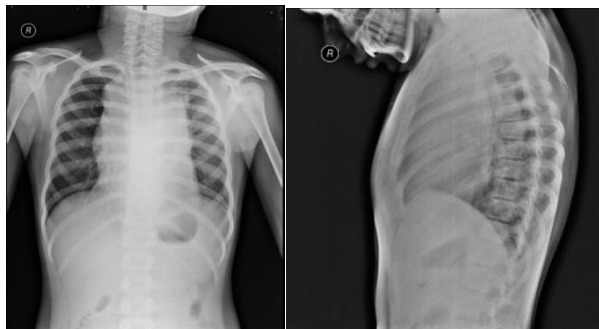
Mediastinal masses are either solid or cystic in nature with benign or malignant behaviour and involving every compartment of the mediastinum. The prevalence of such tumours varies with respect to the mediastinal compartments. In this study, majority of masses were in the anterior mediastinum, followed by posterior and middle mediastinum, which is similar to the other studies. Malignant tumours are more common in the anterior compartment whereas neurogenic tumours are more common in the posterior mediastinum and majority were benign and seen in children. In this study, malignant tumours are more frequently seen compared to benign tumours. One case (n =1, 2%) of sarcoma was found in the posterior mediastinum. Other studies also reported sarcomas in 2% to 8% of primary mediastinal. Common symptoms were dyspnoea, chest pain, fever, and cough resulting from

compression or direct invasion of vital structures. Malignant tumours are more symptomatic than benign tumours. The presence of dilated veins over the chest (SVC syndrome) is suggestive of malignant pathology. Majority of primary tumours were of malignant nature with bronchogenic carcinoma as the most frequently seen tumour and higher than reported this decade. Incidence of lymphoma and neurogenic tumours are same as reported in other studies. One case of mediastinal lipomatosis was seen as mediastinal mass involving middle compartment.



(Left) PA chest radiograph demonstrates a left superior mediastinal mass. The lesion projects above the left clavicle, indicating its middle-posterior mediastinal location. (Right) Sagittal CECT of the same patient shows aneurysmal dilation of the left subclavian artery at its origin from the aortic arch. Approximately 10% of mediastinal masses identified on chest radiography represent vascular lesions.

The approach to mediastinal tumours has evolved over the last two decades. After the initial chest x-ray, CT scan is the most accepted standard imaging and accurate modality in the evaluation of the mediastinal mass. Magnetic Resonance Imaging (MRI) is used selectively for possible vascular or spinal cord involvement, especially for posterior mediastinal tumours of neurogenic origin. In addition to the accurate assessment of the nature of the mass (solid versus cystic), CT scan defines the relationship with the surrounding structures and extent of invasion. Open surgical biopsies were formerly the diagnostic procedures of choice. Now minimally invasive techniques such as needle biopsies are used for tissue diagnosis to execute therapy in a multidisciplinary setting.



Mediastinal widening in 13 yr old boy diagnosed having Non Hodgkin lymphoma encasing all major vessels of thoracic inlet

## 5. Conclusion

Adequate knowledge of mediastinal compartments and special masses of every compartment will help us in the differential diagnosis. Multi-detector computed tomography is the modality most commonly used for evaluation and diagnosis of mediastinal masses. The clinical spectrum of mediastinal masses can range from being asymptomatic to producing compressive symptoms. Although many of these masses have similar imaging appearances, clinical history, anatomical position and certain details seen at CT scan allow correct diagnosis in many cases. Moreover, sampling the mass is important in establishing pathological diagnosis. Fine needle aspiration cytology is considered as adequate evaluation for getting histological diagnosis. However, core biopsies are preferable whenever lymphoma or Thymoma is suspected. The histology of tumours has a close association with prognosis and treatment. Benign tumours have excellent prognosis with surgical resection. Malignant tumours of either primary or metastatic nature require evidence based multidisciplinary therapy setup and carry varying prognosis.

## References

- [1] Puderbach M, Hintze C, Ley S, et al. MR imaging of chest: a practical approach at 1.5T. *Eur J Radiol* 2007;64(3):345-355.
- [2] Gumustas S, Inan N, Sarisoy HT, et al. Malignant versus benign mediastinal lesions: quantitative assessment with diffusion weighted MR imaging. *Eur Radiol* 2011;21(11):2255-2260.
- [3] Karki S, Chalise S. Analysis of mediastinal lesions: a study of 27 cases. *J Pathol Nepal* 2011;1:114-117.
- [4] Powers CN, Silverman JF, Geisinger KR, et al. Fine-needle aspiration biopsy of the mediastinum: a multi institutional analysis. *Am J Clin Pathol* 1996;105(2):168-173.
- [5] Hoftman OA, Gillespie DJ, Aughenbaugh GL, et al. Primary mediastinal neoplasm (other than thymoma). *Mayo Clin Proc* 1993;68(9):880- 891.
- [6] Davis RD, Oldham HN, Sabiston DC. Primary cysts and neoplasms of the mediastinum: recent changes in clinical presentation, methods of diagnosis, management, and results. *Ann Thorac Surg* 1987;44(3):229-237.
- [7] Cohen AJ, Thompson L, Edwards FH, et al. Primary cysts and tumours of the mediastinum. *Ann Thorac Surg* 1991;51(3):378-386.
- [8] Jareb M, Us-Krasovec M. Trans thoracic needle biopsy of mediastinal and hilar lesions. *Cancer* 1977;40(3):1354-1357.
- [9] Temes R, Chavez T, Mapel D, et al. Primary mediastinal malignancies: findings in 219 patients. *West J Med* 1999;170(3):161-166.
- [10] Wongsangiem M, Tangthangtham A. Primary tumours of the mediastinum: 190 cases analysis (1975- 1995). *J Med Assoc Thai* 1996;79(11):689-697.