

Maintenance Requirements of Screw- Retained Implant Prosthesis versus Telescopic Overdenture: A Randomized Controlled Trial

Wafaa Ibrahim¹, Amal Kaddah², Amr ElKhadem³

¹PhD Student, Department of prosthodontics, Faculty of Oral and Dental Medicine, Cairo University, Cairo, Egypt

²Professor, Department of Prosthodontics, Faculty of Oral and Dental Medicine, Cairo University, Cairo, Egypt

³Assistant Professor, Department of Prosthodontics, Faculty of Oral and Dental Medicine, Cairo University, Cairo, Egypt

Abstract: ***Statement of problem:** There is little information about the maintenance requirements of implant restorations. **Purpose:** To compare the prosthodontic maintenance requirements of screw-retained implant prosthesis versus that of telescopic overdentures after an observation period of 18 months. **Materials and methods:** 26 completely edentulous patients were enrolled in the study. Patients were divided into two equal groups receiving either screw-retained restorations or telescopic overdentures which were supported on four maxillary and four mandibular implants. A follow up protocol at the day of loading, 6months, 12 months and 18 months was scheduled to assess maintenance requirements. During the follow-up period, prosthodontic complications for the screw-retained restorations and telescopic overdentures were registered and calculated. **Results:** The total incidence of prosthetic complications recorded was 10 events in the removable group and 14 events in the fixed group. Regarding the removable group the most common complications were screw loosening of the abutment and prosthetic teeth fracture. While screw loosening of the abutments and prosthesis, fractured acrylic resin, fracture of teeth and remake of the prosthesis occurred in the fixed group. The results of the study revealed that there was no significant difference between the two groups. **Conclusion:** Prosthodontic maintenance with implant prosthesis should be considered when planning and estimating the costs of the prosthetic components of implant rehabilitation.*

Keywords: Maintenance, overdenture, implant, fixed, telescopic

1. Introduction

Recently, implant-supported dental prosthesis have been used successfully over conventional dentures as an alternative for replacement of missing teeth [1].

Depending on the original condition and mainly on the number of implants placed, patients can be restored either with fixed or removable implant supported prosthesis [2].

When evaluating treatment with implants we should consider both the clinician and the patient assessment. Regarding the clinicians the most important factors are the implant survival, durability and the complications rate of the prosthesis. To determine the survival of an implant prosthesis it is better to mention "time to retreatment" [3], which is the time until any needed interference by the clinician, thus describing complications during the maintenance period and not only implant failure. Regarding the patients the most important factors are social, psychological and financial factors [4].

There are two types of complications in implant prosthesis: biologic and technical complications.

Biologic complications refer to disturbances in implant function that affect the supporting peri-implant tissues. These consist of early and late implant failures and adverse reactions in the peri-implant hard and soft tissues. Technical complications refer to mechanical damage of the implant, implant components, and suprastructures [5].

Prosthetic complications after the insertion of the final prosthesis may or may not lead to implant loss but can result in an increased need for repair and maintenance [6].

Nevertheless, both fixed and removable implant supported prosthesis need a high amount of maintenance. Up to now maintenance requirements of both complete screw-retained fixed restorations and telescopic overdentures have been studied separately.

The aim of the present study was to compare the maintenance requirements of implant-Supported telescopic overdentures versus fixed screw- retained implant prosthesis after 18 month follow-up.

2. Materials and Methods

26 patients (15 males and 11 females), with an age range of 40-70 years were recruited from the Removable Prosthodontic Department, Faculty of Oral and Dental Medicine, Egypt.

Inclusion criteria:

- 1) Completely edentulous patients with Angle Class I maxilla-mandibular relationship.
- 2) Age between 40 and 70.
- 3) Maxillary and mandibular ridges with no history of recent extraction.
- 4) Adequate bone volume to house four implants in each arch.
- 5) Adequate zone of keratinized attached mucosa >5mm over the crest of the upper and lower ridges.

- Adequate inter-arch space (22 mm), (by using the "try in" as a measure before any intervention taking place)

Exclusion criteria:

- History of radiotherapy in head and neck region.
- Hard tissue augmentation / grafting.
- Absence of any medical disorder that could complicate the surgical phase or affect osseointegration as osteoporosis, uncontrolled diabetes and hypertension.
- Heavy smokers (more than 20 cigarette/ day).
- Patients with para-functional habits (as clenching or bruxism).

Surgical Procedures

A radiopaque radiographic stent was prepared by mixing autopolymerized resin (Acrostone dental company, Egypt.) with barium sulphate powder (Elnasr pharmaceutical chemicals co, Egypt.) in a ratio 4:1. The stents with putty silicone index were placed in the patient's mouth during CBCT scanning (i-CAT 17-19, Imaging Sciences International, Hatfield, PA, USA.). The resultant image was obtained as DICOM (digital imaging and communications in medicine) data which was imported to mimics 10.01 software where virtual planning of the implants was performed. Four implants were planned with two virtual models, with diameter of 3.75 mm and length of 12 mm for anterior and 10 mm for posterior implants. The required implant sites are in the place of the lateral incisor and the second premolar. Once the position of the implants was accepted, the virtual surgical guides (Figure 1) were planned on the software with four holes corresponding to the position of the implants.

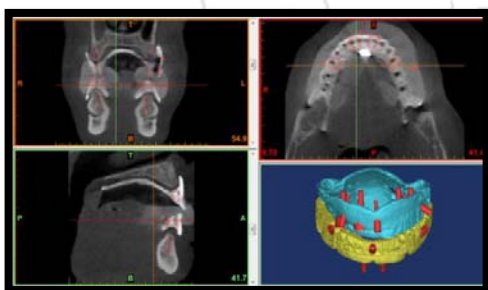


Figure 1: Virtual planning of maxillary & mandibular implants

The stent was fabricated using rapid prototyping machine at the Central Metallurgical Research and Developing Institute (CMRDI). The technique used was selective laser sintering where the stent is built layer by layer using polyetheretherketone (PEEK) material. The surgical stents (Figure 2) were checked inside the patient's mouth for fitness and stability. Three screws were used in the fixation of each stent, one in the mid line and two at the area of the first molar bilaterally. Osteotomy was carried out using three sequential drills at increased diameter of 2.2, 2.8 and 3.5 mm. respectively. After all implants were installed, the fixation screws and the stents were removed. The covering screw was then screwed over the implant fixture. Prophylactic antibiotic was prescribed for all patients; 1 capsule every eight hour of 500 gm amoxicilline (Misr Co. pharmaceutical industries, October Pharma S.A.E. Egypt)

for the next 5 days. Analgesic drug (Ibuprofen 600mg, Knoll AG, Ludwigshafen, Germany) was prescribed once daily or when needed.

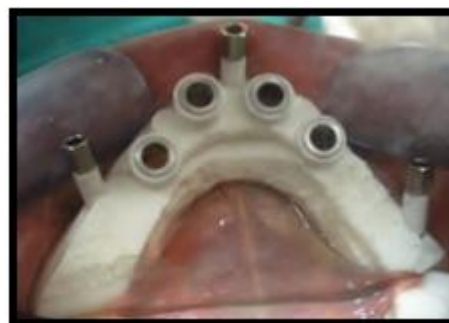

Figure 2: Mandibular surgical guides

Prosthetic Procedures

After a healing period of four months the patients were recalled. After administration of local anesthesia the implants were exposed with the use of lancet and the position of the implants was determined with the help of the surgical stent. The covering screws are unscrewed with the use of screw driver. The permanent transmucosal titanium abutments (Transmucosal Octa abutment, DENTIS-Korea) were fastened over the implant fixtures and torqued to 35 Ncm using torque ratchet. Secondary impression was performed with rubber base (Putty and light consistency addition silicone, elite HD+, Zhermack, Italy) using open tray impression technique. Master casts were verified for accuracy using an acrylic verification jig. The verification jig was tried intraoral and if it was not passively seated it was sectioned and reassembled using duralay resin (Duralay. Low shrink self-cure acrylic resin. Reliance Dental Manufacturing Company-Chicago- USA) then a new cast was constructed. Occlusion blocks were constructed for new bite registration record. Artificial setup of teeth was performed and try-in was done. A putty index was done for the facial and occlusal surfaces of the teeth.

Regarding the screw retained restorations, plastic burnout cylinders (Dentis s-clean subocta system, burnout plastic octa cylinder, Korea) were screwed to the implant analogues and were connected together using duralay resin. Over the duralay frame structure, a wax pattern was constructed and then sprued, invested, and cast into chrome cobalt alloy. An opaquer was applied to the framework (Figure 3) and then light cured. The prosthetic teeth (Viso-lign Light Cured Vennering Composite Resin-Germany) were then positioned in place using the putty index and luted to the framework using light cure. Gingival composite material was applied and light cured. Finally the prosthesis was finished and polished. Occlusal adjustments were done using articulating paper. Then the prosthetic screws were tightened to 25 Ncm with a torque wrench (Figure 4). The access hole were partially closed with pink wax (Cavex® Set Up Modelling Wax, Holland BV) and then completely blocked with light cured composite resin restoration (Super-Cor™, SpofaDental, Czech Republic).

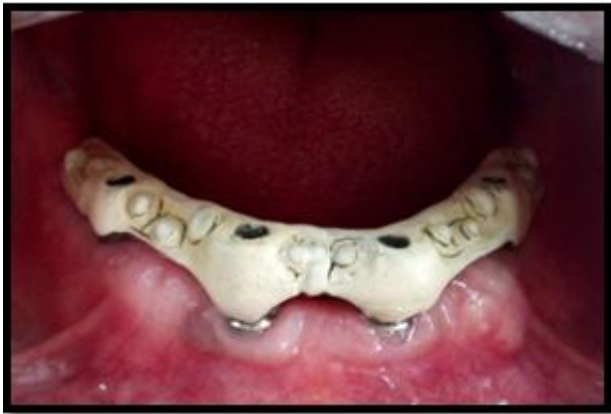

Figure 3: Intra-oral view of the metal framework after application of the opaque

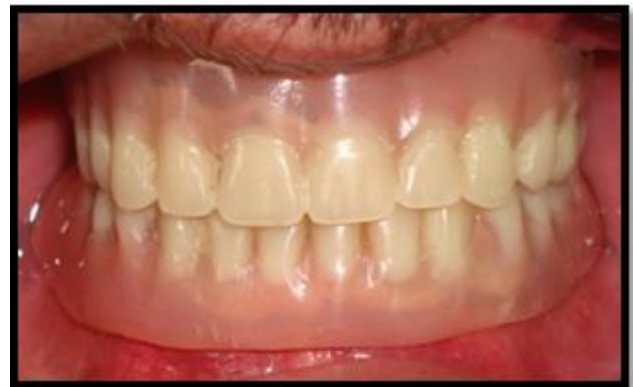

Figure 6: Intraoral view of the maxillary and mandibular dentures

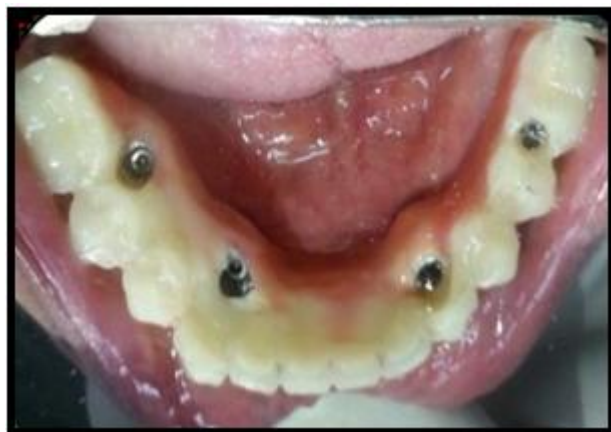

Figure 4: Intraoral view of the final restorations in place

In the telescopic overdentures plastic burnout cylinders were placed on the implant analogues. Wax pattern was trimmed using a surveyor in order to set the 4 abutments parallel to each other. Plastic abutments were casted into chrome cobalt alloy. Try in of the abutments was done intra-orally (Figure 5). Wax patterns were constructed for the frameworks of the overdentures. After casting, the frameworks were tried intra-orally. The overdentures were processed, finished and polished and checked intraorally (Figure 6)

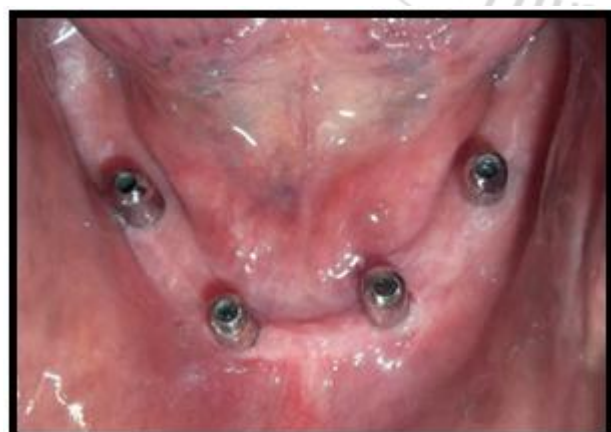

Figure 5: Try in of the abutments done intra-orally

Follow-up

During the 18 months follow-up period, prosthodontic complications for the telescopic overdentures and the screw-retained restorations were registered and calculated according to the following events. Telescopic overdentures were checked for screw loosening of the telescopic abutment, fracture of the screw of the telescopic abutment, fractured acrylic resin, renewal of the secondary coping, prosthetic teeth fracture and overdenture relined or remade. Screw retained restorations: screw loosening of the abutment, screw loosening of the prosthesis, fracture of the screw of the abutment, fracture of the screw of the prosthesis, abutment fracture, framework fracture, fractured acrylic resin, loss of cover of access hole, prosthetic teeth fracture and remake of the prosthesis.

Statistical analysis of the data

Data were fed to the computer and analyzed using IBM SPSS software package version 20.0. Qualitative data were described using number and percent. The significance level was verified at $P \leq 0.05$. If p-value was less than 0.05 the results were considered to be statistically significant. The relative risk between the two groups was calculated. In addition 95% confidence intervals were reported. The used tests were Chi-square test for categorical variables, to compare between different groups and Fisher's Exact for correction of chi-square when more than 20% of the cells have expected count less than 5.

3. Results

Regarding the removable group screw loosening occurred in 7 events affecting 2 abutments in 3 events and 1 abutment in 4 events, thus screw loosening of the abutment occurred in a total of 10 abutments. Prosthetic teeth fracture took place in 3 events affecting 1 tooth in one event and 2 teeth in one event. No other prosthetic complications were recorded during the follow-up period.

While in the fixed group screw loosening occurred in 2 events affecting 1 abutment at each event. Screw loosening of the prosthesis happened 2 times. Fractured acrylic resin took place once. Fracture of teeth (Figure 7) was recorded in 7 events affecting 1 tooth in 5 events and 2 teeth in 2 events. Out of 26 fixed prosthesis, 2 prosthesis were remade due to

fracture which cannot be repaired. Screw fracture and framework fracture did not occur in both groups during the follow-up period.

The total incidence of prosthetic complications recorded was 10 events in the removable group and 14 events in the fixed group (table 1). The relative risk is 0.7143 but the difference is below the statistical significance.

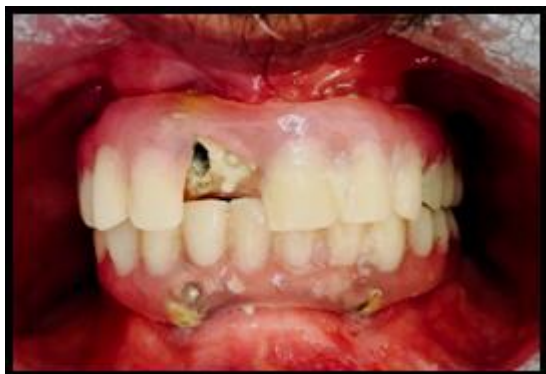

Figure 7: Fracture of acrylic teeth

Table 1: Comparison between the two studied groups according to the total prosthetic complications

χ^2 : Chi square test, FE: Fisher Exact test, CI: confidence interval
 Statistical significance at p-value ≤ 0.05

	<i>Removable group</i>	<i>Fixed group</i>	<i>Relative risk</i>	χ^2	^{FE} <i>p</i>	<i>95% CI</i>	<i>Significance level</i>
Positive (bad) outcome	10	14	0.7143	1.214	0.136	0.3910 to 1.3048	P = 0.2737
Negative (good) outcome	16	12					

4. Discussion

The present study was established to compare the maintenance requirements of screw-retained restorations and telescopic overdentures.

A flapless surgical technique which has several advantages including preservation of circulation, soft tissue architecture, and hard tissue volume at the surgery site, decreased surgical time and improved patient comfort [7]. An adequate interarch space of at least 22 mm must be available to accommodate the prosthesis. This space can be evaluated in the jaw relation stage. In addition patients with class I relationship were included to avoid overloading the implants [8]. Patients with uncontrolled diabetes were excluded from the present study as it leads to delayed healing around implants and impaired immunity and hence higher early failure [9]. Irradiated patients were excluded. Subjects treated with radiation therapy to the head present with decrease in the production of saliva, local vascularity and cellular production, and an increased risk of osteoradionecrosis. Consequently, irradiation may play an important role in the prognosis of patients treated with dental implants [10]. Heavy smoking was from the exclusion criteria in the present study. A study found that of the 590 implants placed in smokers, 11.3% failed compared with only 4.8% for non-smokers [11]. Smoking was reported to be as one of the major risk factors that could affect the success rate of implant osseointegration [12]. Patients with parafunctional habits like bruxism and clenching were excluded from the study. It has been found that bruxism causes excessive (occlusal) load of dental implants and their suprastructures, eventually resulting in bone loss around the implants or even in implant failure [13].

Selective laser sintering (SLS) rapid prototyping technology was used and the material used was polyetheretherketone

(PEEK). PEEK has several advantages like being of high strength, autoclaveable to ensure an antiseptic surgical procedure, and has a high degree of accuracy [14].

A follow-up of 18 month was chosen in the present study. Studies have shown that prosthodontic complications occur both during the first year after treatment and in the long term, while it was reported that the frequency of complications decreases over time [15]. Taking this opinion into consideration, the evaluation time can be expressive for overall maintenance requirements.

There was no significant difference in the incidence of prosthetic complications in the current study between both groups. This is in agreement with a study comparing mandibular overdentures supported by two implants and retained with ball or resilient telescopic crown attachments during a 5-year period. More postinsertion complications were recorded in the ball group (87 interventions, 61.1%) than in the telescopic crown group (53 interventions, 37.9%). The authors claim that significant differences in maintenance requirements were noticed in the second and third years of the follow-up period, without a significant difference in the data at the end of the study for both types of attachments. The most common intervention in the telescopic crown group was rebasing/ relining of the denture. Outer telescopic (matrix) activation was significantly less common in the telescopic crown group compared to matrix activation in the ball attachment group [16].

The primarily seen increased need for maintenance with ball attachment may be due to the presence of an increased rotational axis [17]. Consequently the hinging overdenture may be frequently rebased to attain a stable position in posterior jaw areas, where resorption may occur [18]. As a result of patient adaptation to the rotational movement of the

denture and/or when posterior mandibular atrophy has already reduced the ongoing resorption, the incidence of postinsertion maintenance also decreases in ball retained overdentures. The more rigid stabilization by telescopic crowns showed a homogenous incidence of maintenance efforts over the entire observation period [19].

In our present study, although there was no significant difference in overall complications, telescopic overdentures presented with less complications (n=10) than the screw-retained prosthesis (n=14). This was in similarity to a previous study [20] comparing overdentures retained by bar or magnetic attachment with that of screw-retained restorations. The overdentures presented with fewer complications than fixed prostheses over 5 years period. On the contrary other studies [21, 22] showed that overdentures with other types of attachments showed more complications than the screw-retained prosthesis.

A study compared the maintenance requirements of overdentures retained by ball attachments with that of screw-retained prosthesis. Patients required more appointments in the removable group both in the first year and beyond with 23% requiring more than 5 appointments per year, in comparison to 5% of the patients in the fixed group. Regarding the prosthesis, the incidence of remakes, relines and general adjustments was higher in the removable group [22].

The fact that prosthodontic requirements is less in the telescopic overdentures compared to other types of attachments can be explained by the rigid anchorage and the metal-reinforced denture framework requiring less prosthodontic maintenance than resilient denture stabilization with ball or bar attachment and dentures without frameworks [23].

In the current study the most common prosthodontic complication in the telescopic group was abutment screw loosening (n=7) and occurred in the fixed group (n=2) with no significant difference. Studying the prosthodontic requirements of telescopic crowns over an observation period of 10 years, out of a total of 46 telescopic crowns (16 cemented and 30 screw-retained), loosening of the occlusal screw occurred in 5 implants (16.6%) [24].

Screw loosening of the abutment occurred in both groups in the present study. Several factors may cause screw complications: insufficient preload on the screws, overtightening of the screws leading to stripping and/or screw deformation, and/or occlusal overload from parafunction, occlusal interferences, or extremely long cantilevers [25]. On the other hand it was stated in another study [26] that abutment screw loosening was a rare event with an incidence of 1.2% within 5 years. This was explained by the author that the use of Morse taper connection of implant and abutment can decrease the rate of screw loosening.

There was no need of relining to any of the telescopic overdentures while in another study [24] relining of the overdentures occurred with high incidence of 21.7%. This can be due to using 2 implants in this study which would

exhibit more posterior movement and consequently more bone resorption.

The most common complication in the fixed group was veneer fracture recording 7 events and 3 events in the removable group but the difference was below the level of significance. This is comparable with a systematic review [27] which pointed out that fixed implant prosthesis presented with a varying rate of different complications, with veneer fracture being the most frequent. Veneer fractures may be caused by material failure, design issues as lack of passive fit or inadequate prosthetic space or excessive cantilevers, and/or technical errors [28]. Fracture of the acrylic resin occurred once in the fixed group only which can be attributed to thin margins of the restoration.

In the present study, no fractured screws were observed in both groups. This trend most probably reflects advanced screw properties, geometry and coatings, along with the routine use of torque drivers.

Remake of the prosthesis occurred twice in the fixed group only due to fracture of the prosthesis. Fracture of the prosthesis can be due to faulty design of the metal framework which was corrected by the addition of retentive undercuts in the form of beads on the surface of the framework.

5. Conclusion

Prosthodontic maintenance with implant prosthesis should be considered when planning and estimating the costs of the prosthetic components of implant rehabilitation.

References

- [1] Aglietta M, Siciliano VI, Zwahlen M. A systematic review of the survival and complication rates of implant supported fixed dental prostheses with cantilever extensions after an observation period of at least 5 years. *Clin Oral Implants Res* 2009;20:441-51.
- [2] Krennmair G, Süt D, Seemann R, Piehslinger E. Removable four implant-supported mandibular overdentures rigidly retained with telescopic crowns or milled bars: A 3-year prospective study. *Clin Oral Implants Res* 2012;23:481-88.
- [3] Carr AB. Successful long-term treatment outcomes in the field of osseointegrated implants: prosthodontic determinants. *Int J Prosthodont* 1998;11:502-12.
- [4] Guckes AD, Scurria MS, Shugars DA. A conceptual framework for understanding outcomes of oral implant therapy. *J Prosthet Dent* 1996; 75:633-9.
- [5] Berglundh T, Persson L, Klinge B. A systematic review of the incidence of biological and technical complications in implant dentistry reported in prospective longitudinal studies of at least 5 years. *J Clin Periodontol* 2002;29:197-212.
- [6] Papaspyridakos, P., Chen, C. J., Chuang, S. K., Weber, H. P., & Gallucci, G. O. A systematic review of biologic and technical complications with fixed implant rehabilitations for edentulous patients. *The International journal of oral & maxillofacial implants* 2011; 2:102-110

- [7] Sclar A. Guidelines for flapless surgery. *Journal of oral and maxillofacial surgery.*2007;65:20-32.
- [8] Jensen OT., Adams MW.,Cottam JR., Parel SM., Phillips WR. The All-on-4 shelf: maxilla. *J Oral Maxillofacial Surgery.*2010;68:2520-7
- [9] Dubey RK., Gupta DK, Singh AK. Dental implant survival in diabetic patients; review and recommendations. *National journal of maxillofacial surgery.*2013;4:1:42-6.
- [10] Chambrone L., Mandia J., Shibli JA., Romito G., AbrahaoM. Dental Implants Installed in Irradiated Jaws. A Systematic Review. *Journal of dental research.*2013;92(12 suppl):119S-130S.
- [11] Bain CA, Moy PK. The association between the failure of dental implants and cigarette smoking.*Int J Oral Maxillofac Implants.* 1993;8:609-15.
- [12] Rodriguez-Argueta OF, Figueiredo R, Valmaseda-Castellon E, Gay-Escoda C. Postoperative complications in smoking patients treated with implants: a retrospective study. *Journal of oral and maxillofacial surgery: official journal of the American Association of Oral and Maxillofacial Surgeons.* 2011;69:2152-7.
- [13] Lobbezoo F., Brouwers JE., Cune MS., Naeije M. Dental implants in patients with bruxing habits. *Journal of oral rehabilitation.*2006;33:152-9.
- [14] Mazzoli A. Selective laser sintering in biomedical engineering.*Medical & Biological Engineering & Computing.* 2013;51:245-56.
- [15] Johansson G, Palmqvist S. Complications, supplementary treatment, and maintenance in edentulous arches with implant-supported fixed prostheses. *Int J Prosthodont.* 1990;3:89-92.
- [16] Krennmair G, Seemann R, Weinländer M, Piehslinger E. Comparison of ball and telescopic crown attachments in implant-retained mandibular overdentures: a 5-year prospective study. *International Journal of Oral & Maxillofacial Implants.*2011;26:598-606
- [17] Kimoto S, Pan S, Drolet N, Feine JS. Rotational movements of mandibular two-implant overdentures.*Clin Oral Implants Res.* 2009;20:838-43.
- [18] Kordatzis K, Wright PS, Meijer HJ. Posterior mandibular residual ridge resorption in patients with conventional dentures and implant overdentures.*Int J Oral Maxillofac Implants.* 2003;18:447-52.
- [19] Hoffmann O, Beaumont C, Tatakis DN, Zafiroopoulos GG. Telescopic crowns as attachments for implant supported restorations: A case series. *J Oral Implantol.* 2006;32:291-9.
- [20] Hemmings KW, Schmitt A, Zarb GA. Complications and maintenance requirements for fixed prostheses and overdentures in the edentulous mandible: a 5-year report. *Implant Dentistry.* 1994;1;3:265-75.
- [21] Brennan M, Houston F, O'Sullivan M, O'Connell B. Demographics of implant placement and complications of a patient subgroup in a dental hospital population. *Journal of the Irish Dental Association.* 2009;56:85-92.
- [22] Tinsley D, Watson CJ, Russell JL. A comparison of hydroxylapatite coated implant retained fixed and removable mandibular prostheses over 4 to 6 years. *Clinical Oral Implants Research.* 2001;12:159-66.
- [23] Strub J. Prosthodontic Complications with Implant Overdentures: A Systematic Literature Review. *The International Journal of Prosthodontics.* 2010:195-203.
- [24] Heckmann SM, Schrott A, Graef F, Wichmann MG, Weber HP. Mandibular two-implant telescopic overdentures. *Clinical oral implants research.* 2004;15:560-9.
- [25] McGlumphy EA, Mendel DA, Holloway JA. Implant screw mechanics. *Dent Clin North Am.* 1998;42:71-89.
- [26] Frisch E, Ziebolz D, Ratka-Krüger P, Rinke S. Double Crown-Retained Maxillary Overdentures: 5-Year Follow-Up. *Clinical implant dentistry and related research.* 2015;17:22-31.
- [27] Torbjörn A. Fransson B. Biomechanical aspects of prosthetic treatment of structurally compromised teeth. *International Journal of Prosthodontics.* 2004;17: 135-41.
- [28] Goodacre CJ, Bernal G, Rungcharassaeng K, Kan JY. Clinical complications with implants and implant prostheses. *J Prosthet Dent* 2003;90:121-32.

Author Profile



Wafaa Ibrahim Ibrahim, received the B.D.S. in Oral and Dental medicine from Cairo University, faculty of dentistry 1998. During 2000-2008, she worked in Ministry of Health. During 2009-2011 she received Ms. Degree in Removable Prosthodontics from Faculty of Dentistry, Alexandria University. During 2013 till now she is a PhD student in Faculty of Oral and Dental Medicine, Cairo University. From 2012 till 2016, she was an assistant lecturer in Removable Prosthodontic Department, Faculty of Dentistry. Pharos University Alexandria, Egypt.