

A Clinical Study of Evaluation of Optic Atrophy

Dr. M. Parni Kumar¹, Dr. G. Manjula²

¹M.S, HOD, Professor of Ophthalmology

²M.S, D.O, Associate Professor of Ophthalmology, Guntur Medical College, Guntur

Abstract: To assess the different types of optic atrophy in patients attending the general ophthalmic OPD department, GGH, Guntur from November 2011 to October 2013.

Objectives: The objectives of study are to contemplate the different types of optic atrophy

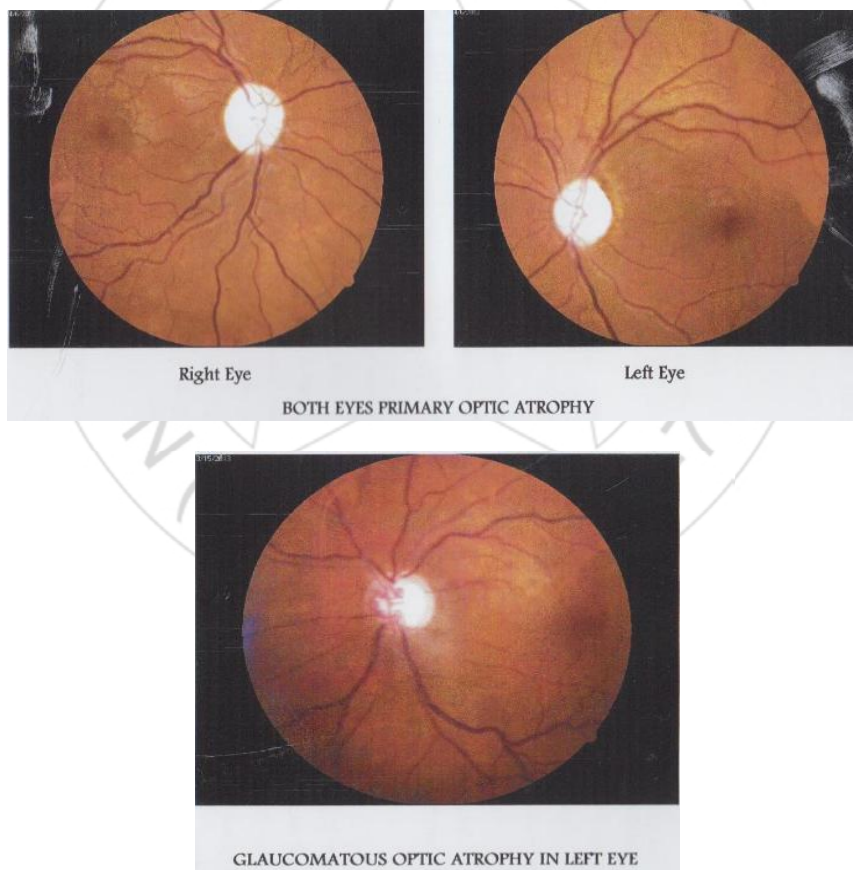
Keywords: Fundus photography, optic atrophy.

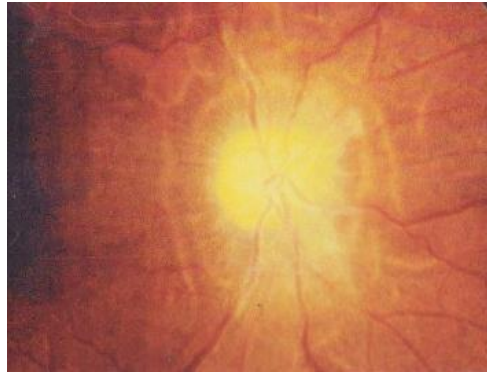
1. Materials and Methods

Prospective study of 100 cases of optic atrophy attending GGH, Guntur from period of November 2011 to October 2013 with detailed history of patient. The study included ophthalmic checkup including slit lamp examination, perimetry and intra ocular measurement, Optic disc

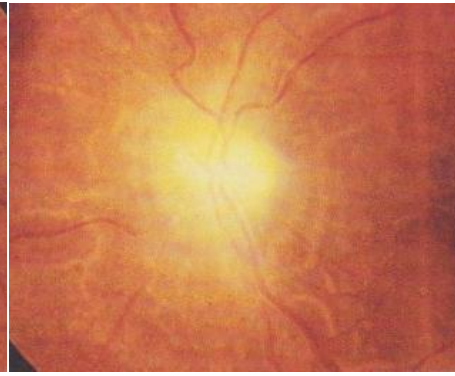
examination with direct ophthalmoscopy and slit lamp examination with +78D, +90D and fundus photograph. Medical examination with investigating blood counts, ESR analysis, x-ray skull, paranasal sinuses screening was done.

2. Fundus Photographs





RE secondary optic atrophy



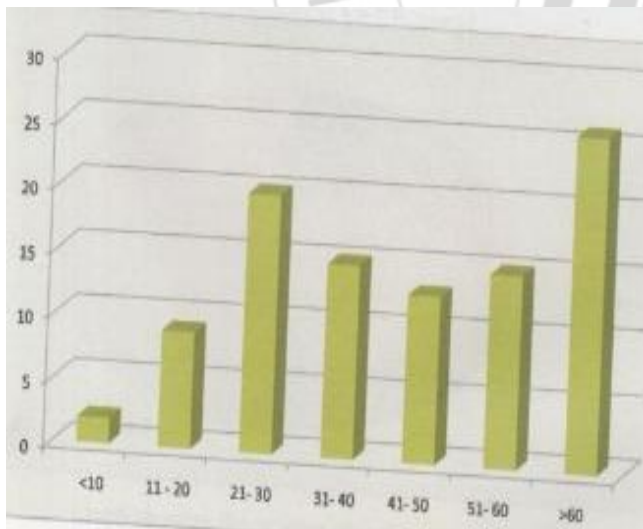
LE secondary optic atrophy

3. Discussion

This study was under taken in the department of ophthalmology GGH, Guntur, during November 2011 to october2013, 100 cases of optic atrophy were evaluated. Optic atrophy is one of the causes of irreversible blindness, this may lead to early detection of glaucoma, may prevent blindness and genetic counseling regarding consanguineous marriage in retinitis pigmentosa. Prevalence of optic atrophy was more in elderly age group in this study.

Table showing age specific prevalence of Optic atrophy:

Age in years	No. of cases	percentage
<10	2	2%
11-20	9	9%
21-30	20	20%
31-40	15	15%
41-50	13	13%
51-60	15	15%
>60	26	26%

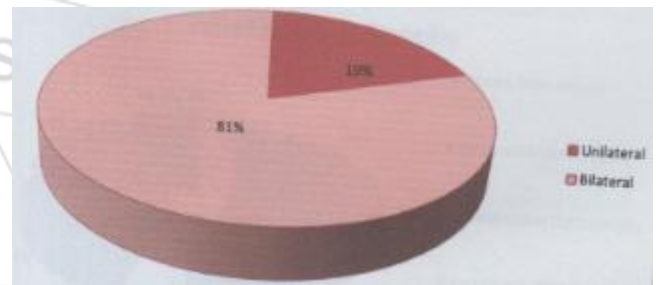


Graph showing age specific prevalence of Optic atrophy

This is concordance with published in international journal of clinical practice (T.S Oluleye et al) In this study bilateral optic atrophy was found in 81% of cases and unilateral optic atrophy was found in 19%. This is comparable to the above study which shows 81% bilaterality.

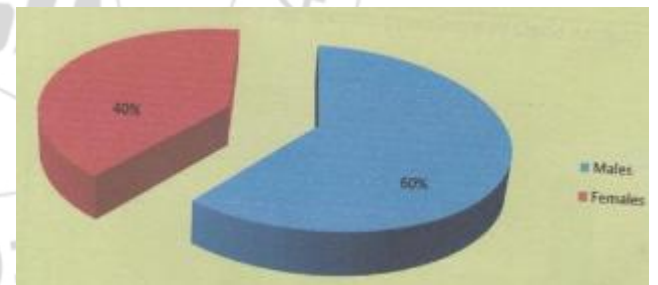
Table showing no. of unilateral and bilateral cases in the study:

Laterality	No. of cases	percentage
Unilateral	19	19%
Bilateral	81	81%



Graph showing no. of unilateral and bilateral cases in the study

In our study male and female ratio was found to be 2:1 and this is in correlation with above study.



Graph showing sex ratio

According to H.D.Daston et al in their study ' A study of optic atrophy' the causes of optic atrophy were as follows

- 1) Optic atrophy following injury
- 2) Optic atrophy following inflammation
- 3) Optic atrophy following Glaucoma
- 4) Optic atrophy Intracranial tumour
- 5) Optic atrophy following ingestion of toxins

In the above study they found that glaucomatous optic atrophy was the commonest followed by vascular toxic and syphilitic.

Based on the ophthalmoscopic findings we grouped the cases in our study as follows

- 1) Primary optic atrophy
- 2) Consecutive optic atrophy
- 3) Glaucomatous optic atrophy

- 4) Traumatic optic atrophy
- 5) Optic atrophy due to intra cranial space occupying lesion
- 6) Post neuritic optic atrophy

<i>Types of Optic Atrophy</i>	<i>No. of cases</i>	<i>percentage</i>
Primary optic atrophy	55	55%
Consecutive optic atrophy	21	21%
Glaucomatous optic atrophy	16	16%
Traumatic optic atrophy	2	2%
Optic atrophy due to intra cranial space occupying lesion	2	2%
Post neuritic optic atrophy	4	4%

Out of the causes we found that primary optic atrophy was the most common type with 40%cases followed by consecutive optic atrophy with 21% cases. In patients with optic atrophy visual rehabilitation was advised especially in children, special education like Braille and low vision device.

4. Conclusion

In the series of optic atrophy

- 1) 55 cases of primary optic atrophy
- 2) 21 cases of consecutive optic atrophy
- 3) 16 cases of glaucomatous optic atrophy
- 4) 2 cases due to trauma
- 5) 2 cases due to intra cranial space occupying lesion
- 6) 4 cases due to post neuritic

References

- [1] Duke Elder. W. S: Text Book Of Ophthalmology, Vol, III, Diseases Of The Inner Eye: Henry Kimpton. (1940).
- [2] Cooper S.N. 1956 Proc All India Ophthalmic Society 16,4.
- [3] Cordes FE (1952) Atrophy in infancy Childhood and Adolscence(Survey in 81 cases) AM J Ophth. 35 1272.
- [4] Francois J And Nethans A. Collett (1955) Vascular Supply of Optic Pathway(Studies of Microarteriography of Optic Nerve.Br j Ophth 39: 220.
- [5] Moore, J(1937): A Etiological Study of Series of Optic Neuropathy; AM J 20:1099.
- [6] Paton L (1922): Tabes and Optic Atrophy Br J Ophth 6:289.
- [7] Helmick E (1957): Tabetic Optic Atrophy A. M. A. Arch of 57:282.