

Seminoma in Undescended Intra Abdominal Testis: A Case Report

Dr Arshad Hasan¹, Dr Lakshmi Sinha², Dr Prashant Kumar Singh³, Dr Shashikant Kumar⁴,
Dr Manoj Kumar⁵, Dr Nishit Ranjan⁶

¹Senior Resident, Department of General Surgery, Aiiims, Patna Bihar

²Senior Resident, Department of General Surgery, Aiiims Patna Bihar

³Assistant Professor, Department of General Surgery, Aiiims Patna Bihar

⁴Senior Resident, Department of Pathology, Aiiims Patna Bihar

⁵HOD&Associate Professor, Department of General Surgery, Aiiims Patna Bihar

⁶Senior Resident, Department of General Surgery, Aiiims Patna Bihar

Abstract: Undescended testis is a congenital abnormality with estimated risk of 4% at birth¹. The majority of undescended testis are palpable in inguinal canal but about 5% are intraabdominal². Intra Abdominal testis has the highest risk for carcinogenesis of testicular cancer among undescended testis³. Nowadays, the existence of undescended testis in the adult population is rare due to elective orchidopexy in early year of life so malignant transformation of intra-abdominal undescended testis is rarely reported⁷. We found a case of seminoma of undescended intra-abdominal right testis in 34 years old male which was treated successfully by open surgical removal in our department.

Keyword: undescended testis, testicular cancers, seminoma, orchidopexy, intra-abdominal

1. Introduction

Normally testis develop within the abdominal cavity and descend to scrotum by the time of birth². In some children testis remains undescended in its pathway and hangs in superficial inguinal pouch, inguinal canal or in the abdomen². Right testis alone is involved in half of the cases and is bilateral in 20% cases⁴. About 90% of undescended testis are palpable and remaining 10% are non palpable, from which about 5% are intra-abdominal and rest are atrophic and nonviable². There are many complications associated with undescended testis of which inguinal hernia, sterility, torsion testis, testicular atrophy and risk of malignant transformation are common^{1,2,4}. Development of malignancy in undescended testis is affected by location of testis which is higher in intra-abdominal than in inguinal location³. Most common type malignancy has been reported in undescended testis is seminoma with peak incidence in 4th decade⁴. Physical examination and radiological evaluation identify the correct location of undescended testis. Surgical management of undescended testis is necessary to preserve fertility, associated inguinal hernia correction and to limit the risks of testicular malignancy².

Nowadays, the existence of undescended testis in the adult population is rare because elective orchidopexy is universally practised in early year of life so malignant transformation of intra-abdominal undescended testis is rarely reported⁷. We found a case of seminoma of undescended intra-abdominal right testis in 34 years old male which was treated successfully by open surgical removal in our department.

2. Case Report

A , 34 years old hindu male , skilled labourer was admitted to our department with the complains of pain in the right lower abdomen for last 6 month. He had been feeling of heaviness in right lower abdomen, anorexia and weight loss for last 2 months.

On examination he was a febrile but mildly pale. There was tenderness and a lump of 10 cmx8cm in right iliac fossa and part of hypogastrium. The lump was globular in shape, regular surface, firm consistency with well defined margin. The lump was not moving with respiration and fixed with underlying structures. Left testis was found to be in place but right testis was absent from the right scrotal sac. On provisional diagnosis we suspected right sided intra-abdominal testicular tumour.

On Ultrasonographic scanning of whole abdomen right kidney was ectopic in right iliac fossa. A 9.9cm x 7.0cm large well-defined solid mass in infra umbilical region above ectopic right kidney but separated from it .On CECT of abdomen the right kidney was ectopic and seen in right lower pelvis with hilum directed antero-medially deriving its blood supply from left common iliac artery with venous drainage into inferior vena cava. There was a well-defined mass of 10.5x7.8x6.5cm size in the right lower pelvis, anterior to the ectopic right kidney. It was relatively homogenous in appearance and showing mild homogenous enhancement. It showed prominent tangle of venous channels extending from it and draining into inferior vena cava. The right spermatic cord was not visualised. There were multiple mildly enlarged retroperitoneal nodes seen at the level of renal hilum and extending superiorly.(Fig1)

Volume 5 Issue 12, December 2016

www.ijsr.net

Licensed Under Creative Commons Attribution CC BY

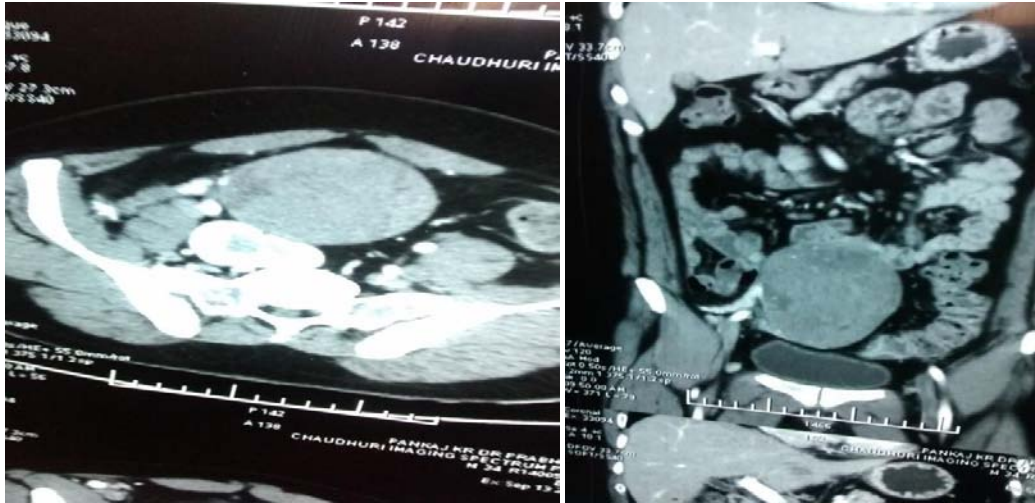


Figure 1: CECT Plate showing well-defined mass in lower pelvis with ectopic right kidney

Findings were suspicious for malignant testicular mass in undescended right testis.

Interpretations of IVU showed normal functioning kidney and Barium enema showed normal colon. Complete blood count, liver function test & kidney function tests were within normal limit. Tumour markers (AFP,HCG,LDH) were also within normal range.

We planned for surgical removal of undescended testicular mass. We went for laparotomy with lower midline incision and found a huge growth occupying the lower abdomen. The growth was excised after ligating its stalk. (Fig2)

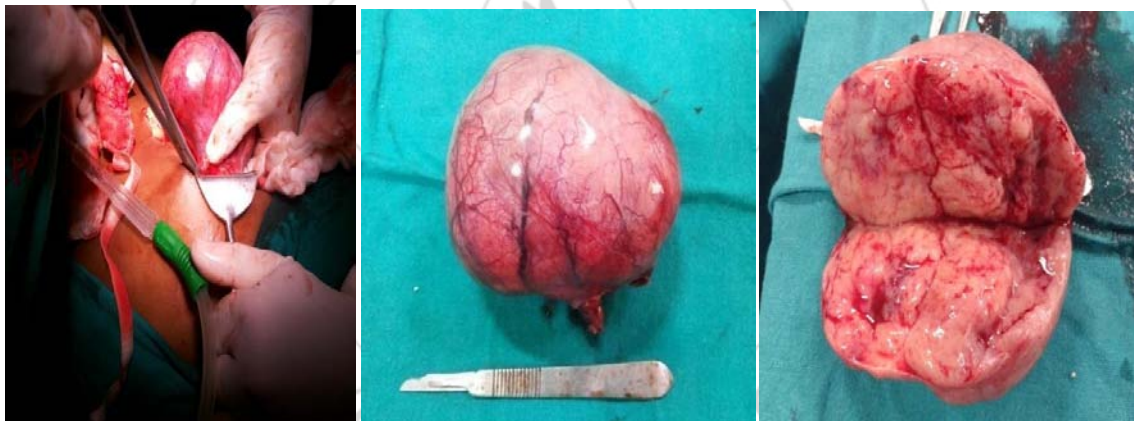

Figure 2: Intraoperative, excised & cut section of intra-abdominal undescended testicular mass

After mobilising caecum and ascending colon few retroperitoneal lymphnodes appearing benign also excised. The Abdomen was closed with one drain in situ. The postoperative period was uneventful.

The histopathological examination of excised mass revealed presence of tumour cells having clear to granular cytoplasm arranged in lobular pattern separated by thick band of fibrocollagenous septa infiltrated by lymphocytes and plasma cells which are features of seminoma of testis.

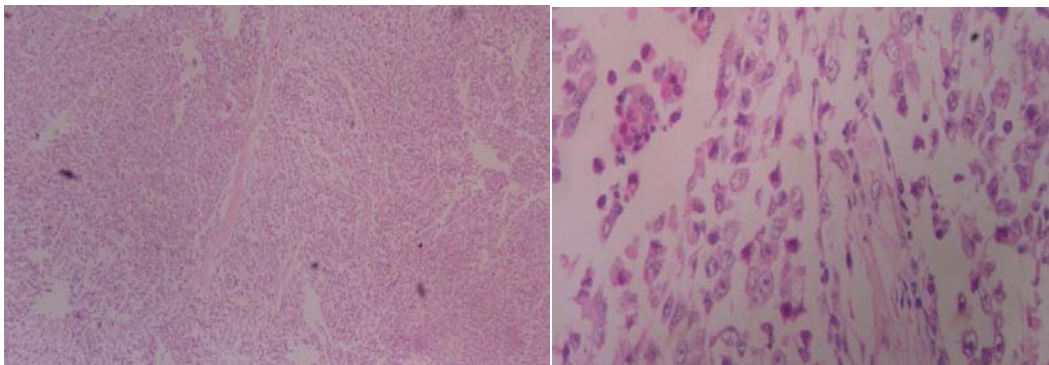


Figure 3: Photomicrograph of intra-abdominal testicular tumour-seminoma

3. Discussion

Testicular tumour accounts for 1% of all malignant tumours and 99% of testicular tumours are malignant⁴. Life time prevalence of getting testicular tumour is 0.2%⁴. Testicular tumours are four times more common in whites than blacks⁴. These are least common in Africa and Asia⁴. Seminoma is most common variety among testicular tumours. Less than 1% of testicular cancers occurs before 10 years of age⁵. The incidence curve increases steeply after the onset of puberty and is most frequent in men in their 4th decade⁵. Undescended testis, Testicular atrophy and Klinefelter's syndrome are known predisposing factors^{1,4,5}. Undescended testis, which also known as cryptorchidism is one of the common congenital abnormality of genitourinary tract¹. The position of undescended testis is related to risk of testicular malignancy with intra-abdominal being highest³. Campbell-Walsh Urology, 9th edition states, "It is well established fact that children born with undescended testis are at increase risk for malignancy...the relative risk is approximately 40 times greater." However, in Adult and Pediatric Urology it is stated that "The combined risk for all cryptorchid males irrespective of the location of testis, has been calculated at 20 to 46 times greater than for patients with normally located testis." In the Pediatric Urology it is stated that "Individuals born with an undescended testis have approximately a 40-fold incidence of testicular malignancy over those born with scrotal testis⁶." Risk of testicular neoplasm is also higher in patients with history of bilateral cryptorchidism than with unilateral cryptorchidism⁶. The cause of higher risk for testicular malignancy in undescended testis is still an mysterious but high intra-abdominal temperature has been incriminate as the cause³. Seminoma in germ cell tumour is most common reported testicular malignancy in undescended testis^{1,4}.

Painless enlargement of the testis, or abdominal mass are the common mode of presentation in the undescended testicular malignancy. Rarely, abdominal testicular tumour can cause acute abdomen, pain or hematuria due to adjacent visceral infiltration³. Sometime patient also develop infertile due to delay in the development of sertoli cells and decrease in spermatogenesis^{3,4}.

The timing for orchidopexy for undescended testis also influences development of neoplasm. Literature shows that excess risk for testicular cancer in cases of undescended testis is higher for men who were treated later than earlier in life⁶. Although orchidopexy helps in early detection of malignancy symptoms, its potential benefit and oncological risks remain to be determined. Testicular biopsy may be helpful during orchidopexy in older age. Usually orchidectomy is advised for intra-abdominal undescended testis. The management of the contralateral testis in unilateral undescended testis is controversial and there are no firm guidelines for their management. There is 5-20% risk of development of testicular tumour in opposite normally descended testis³. Some preferred prophylactic orchidectomy for uninvolved testis³. In our patient we did not manipulate the opposite normal testis and relied on regular follow up.

There is dramatic improvements in survival due to combination of effective diagnostic techniques, improvements in tumour markers, effective multi-drug chemotherapeutic regimens and modifications of surgical techniques during last few years. We expect a very good prognosis from this patient.

4. Conclusion

The abdominal variant of undescended testis is rare but has highest risk of malignant transformation. Primarily the parents, then the school medical officers and finally the patients himself must be aware of undescended testis and address the problem seriously. Undescended testis should be brought down to normal scrotum in early ages. Testicular biopsy in high risk patients and regular follow up after surgery are necessary to early detection of testicular neoplasm. There also should be a clear cut guideline for the management of undescended testis.

References

- [1] Bailey & Love's Short Practice of Surgery; 25th ed. 2008, 76-77, 1377-87
- [2] [www.urologyclinics.com/.../NTPUAOrch...Undescended Testicles-Cryptorchidism-Urology Clinics of North Texas](http://www.urologyclinics.com/.../NTPUAOrch...UndescendedTesticles-Cryptorchidism-UrologyClinicsofNorthTexas).
- [3] M.M.Haque, A.B.Siddique, A.B.M.G.Rabbani, M.A.Quasem, A.K.M.G.Rahman, M.M.Rahman: Seminoma in undescended intra abdominal testis; TAJ December 2005; 18(2): 131-1332. 4. Sriram Bhat M; SRB's Manual of surgery; 4th ed. 2013, 1160-1171
- [4] D.Cortes, J.Thorup, B.L.Peterson: Testicular neoplasia in undescended testes of cryptorchid boys - does surgical strategy have an impact on the risk of invasive testicular neoplasia: The Turkish journal of paediatrics 2004; 46(supplement): 35-42
- [5] H.M.Wood, J.S.Elder; Cryptorchidism and testicular cancer: separating fact from fiction: The journal of urology vol. 181, feb. 2009, 452-461
- [6] P.sarkis, H.R.Kourie, J.Gharios, J.Kattan; Complete Remission by Primary Chemotherapy of Advance Non-seminomatous Germ Cell Tumour in an Intra-Abdominal Testis: Open Journal of Urology, 2014, 4, 105-108