

Transversus Abdominis Plane Block for Post Operative Analgesia in Lower Abdominal Surgery: A Comparison of Bupivacaine and Ropivacain

Dr Dipika Patel¹, Dr Bina Patel², Dr Hardik Patel³, Dr Divyang Shah⁴, Dr Pragna Vachhrajani⁵

Department of Anaesthesiology, Surat Municipal Institute of Medical Education and Research(SMIMER), Surat, Gujarat, India

Abstract: *Transversus Abdominis Plane (TAP) block is an effective method of providing postoperative analgesia in patients undergoing lower abdominal surgery. Prospective, randomized controlled study was carried out in 100 patients of either sex belonging to ASA grade I or II, age group of 18 to 60 years undergoing lower abdominal surgery. The patients were randomly allocated in two groups of fifty patients each. All patients were given spinal anaesthesia with Bupivacaine heavy 0.5%, 0.3 mg/kg, by 25 G spinal needle. After completion of surgery, they received TAP block with either 0.25% Bupivacaine (Group B) or 0.5% Ropivacaine (Group R). During postoperative period, patients were monitored for heart rate, blood pressure, hematoma, nausea, vomiting, Visual Analogue Scale (VAS), need of supplemental analgesia within 24 hours and local anaesthetic toxicity if any.*

Keywords: Transversus Abdominis Plane Block, Spinal anaesthesia, Bupivacaine Ropivacaine, Ultra sonography

1. Introduction

A substantial component of the pain experienced by patients after abdominal surgery is derived from the abdominal wall incision. The abdominal wall is innervated by nerve afferents that course through the transversus abdominis neuro-fascial plane.

Blockade of the neural afferents course through the neuro-fascial plane between the internal oblique and the transversus abdominis muscles can be achieved by Transversus Abdominis Plane Block. Local anaesthetic is injected into the plane between internal oblique and transversus abdominis muscle in Lumbar triangle of Petit and it is possible to block the sensory nerves of the anterior abdominal wall before they pierce the musculature to innervate the abdomen. It produces a dermatomal sensory block of the lower six thoracic and upper lumbar abdominal afferents.

The Transversus Abdominis Plane (TAP) Block is a local anaesthetic block used to provide analgesia to the anterior and lateral abdominal wall. Rafi et al. (2001)⁹ was the first to describe this novel abdominal field block.

The present study was conducted to compare efficacy of Bupivacaine and Ropivacaine in relieving post-operative pain in lower abdominal surgery by Transversus Abdominis Plane Block.

2. Aim and Objectives

- To study the effectiveness of Transversus Abdominis Plane Block for post-operative analgesia and duration of analgesia in lower abdominal surgery
- To compare the hemodynamic stability and any side effects after TAPB with Bupivacaine 0.25% and Ropivacaine 0.5%.

3. Review of Literature

Pain is a normal accompaniment of surgical intervention and it induces a metabolic, neuro-endocrinal and cardio-respiratory response, which has a negative impact on outcome of the surgery.

Several studies were carried out to compare the effect of TAB by giving different type of drugs. Unilateral TAP block with 20 ml of Ropivacaine, as a component of multimodal analgesic regimen, provides superior analgesia compared with placebo in the first 48 postoperative hours after appendectomy in children⁶. Another study stated that Ultrasound-guided TAP block with Bupivacaine 0.25 % improves postoperative analgesia, reduces morphine consumption and improves patient's satisfaction regarding analgesia after caesarean delivery and total morphine requirements in the first 24 postoperative hours were also reduced in the Bupivacaine group compared with the placebo group³. **Bharti N, Kumar P and colleagues (2011)**⁵ evaluated analgesic efficacy of Transversus Abdominis Plane (TAP) block with Bupivacaine in patients undergoing colorectal surgery and concluded that the TAP block provides effective postoperative analgesia after colorectal surgery.

4. Method

After approval from the Institutional Ethics Committee, the present study was conducted in 100 patients of either sex belonging to ASA grade I or II, in the age group 18 to 60 years scheduled for elective lower abdominal surgery.

Detailed history and preoperative assessment was carried out a day before surgery. A detailed general as well as systemic examination was done to rule out any major systemic illness. Routine investigations were carried out. Patients with drug allergy, skin infections at the site of block, history of disorders of blood clotting, and patients with cardiovascular, respiratory, hepatic and renal diseases, inability to understand the use of Visual Analogue Scale (VAS) and

history of epilepsy were excluded from the study. Informed written consent was taken from the patient. Preoperatively patients were inquired about the NBM status. In pre-operative room, pulse rate, blood pressure and respiratory rate were noted.

After securing intravenous line, all patients were preloaded with Inj. Ringer Lactate 10 – 15 ml/kg. Patients were premedicated with inj. Glycopyrrolate 5 µgm/kg and inj. Midazolam 50 µgm/kg I.M. half an hour before surgery. On operation table, baseline pulse, blood pressure and saturation of oxygen were recorded.

Spinal anaesthesia was administered by using 0.3mg/kg, 0.5% Bupivacaine heavy at L2 – L3 or L3 – L4 vertebral interspace by 25 G spinal needle. Routine monitoring included heart rate, noninvasive blood pressure and oxygen saturation were done.

The patients were randomized to receive either Bupivacaine 0.25%, 20 ml (Group B) or Ropivacaine 0.5%, 20 ml (Group R) in transversus abdominis plane after completion of the surgery.

In supine position, the lumbar triangle of Petit (bounded anteriorly by External oblique muscle, posteriorly by Lattissimus dorsi muscle and inferiorly by iliac crest) was identified.

A 22 gauge, 5-8 cm long blunt tipped short bevelled needle was inserted in this triangle, just posterior to the mid axillary line perpendicular to skin. A pop was felt when the needle passed through the fascial extension of the external oblique muscle i.e. the tip was between the fascial layers of the external oblique muscle and the internal oblique muscle. A second pop indicated that the needle was in the fascial plane above the transversus abdominis muscle. 20 ml of the local anaesthetic solution was injected in this plane after negative aspiration.

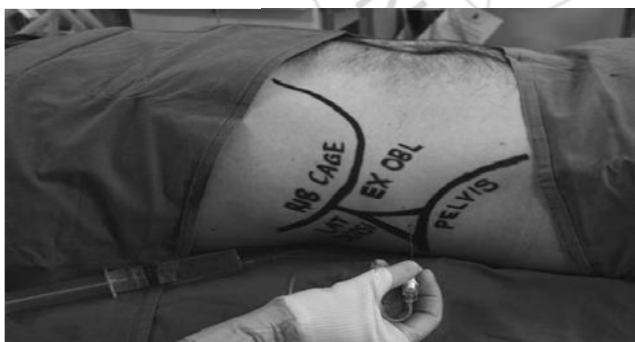

Figure 1: Lumbar triangle of Petit between external oblique muscle and latissimus dorsi.

During postoperative period, patients were monitored for heart rate, blood pressure, nausea, vomiting, hematoma, Visual Analogue Scale (VAS), need of supplemental analgesia and local anaesthetic side effects if any, at every 10 minutes interval up to 30 minutes, then every 30 minutes interval up to 3 hours, then at 6 hours and then every 6 hours interval up to 24 hours.

In the postoperative period, inj. Diclofenac 75 mg IM was given, when VAS>4 and repeated after 6 hours, when patient complained of pain persistently. The time of first analgesic, total doses of analgesic within 24 postoperative hours, VAS at rest and during movement and any side effects were also recorded. Statistical analysis was done by using unpaired 't' test. We assumed there was a statistically significant difference when p value is less than 0.05.

5. Results

100 patients were included in the study, all patients were undergoing lower abdominal surgery. The baseline characteristic of the two groups were not significantly difference.

Table 1: Baseline characteristic of the study participants

Parameter	Group B	Group R
Age (years)	37.32±11.60	39.04±11.96
Weight (Kg)	53.26±7.31	54.10±7.56
Male/ Female	46/4	45/5
ASA grade I/II	38/12	41/9

Table 2: Duration of surgery

	Group B	Group R	'p' value
Mean±SD (min)	84.60±12.28	87.70±11.61	>0.05

In group B, mean duration of surgery was 84.60±12.28 minutes whereas in group R, it was 87.70±11.61 minutes which was comparable in both the groups (P>0.05).

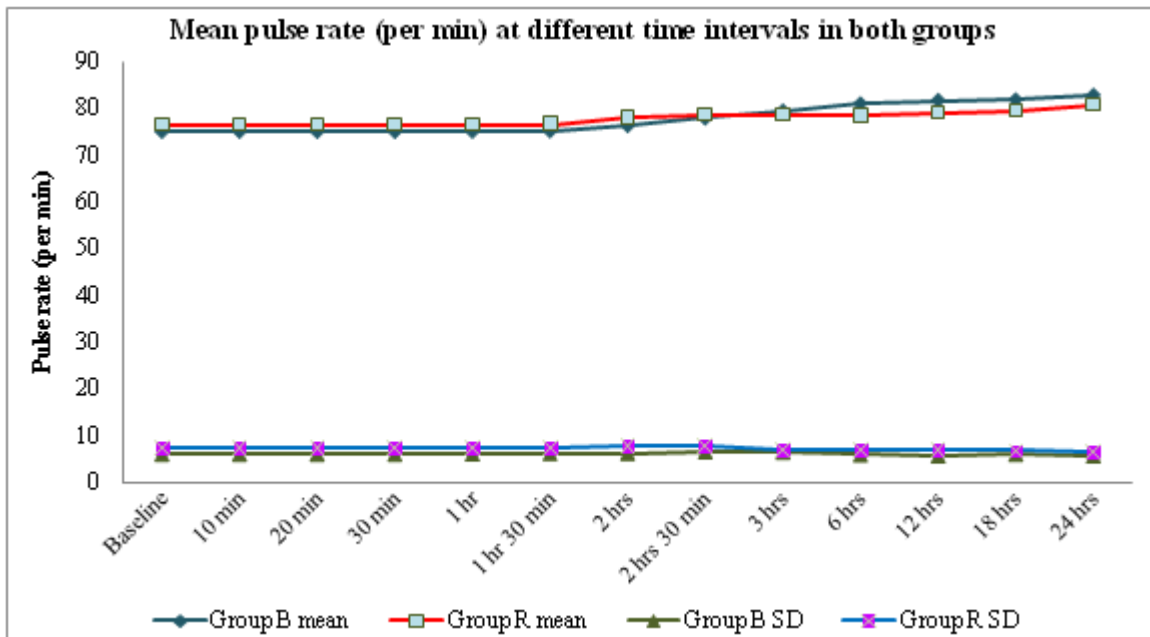


Figure 3: different pulse rate in both groups in different intervals

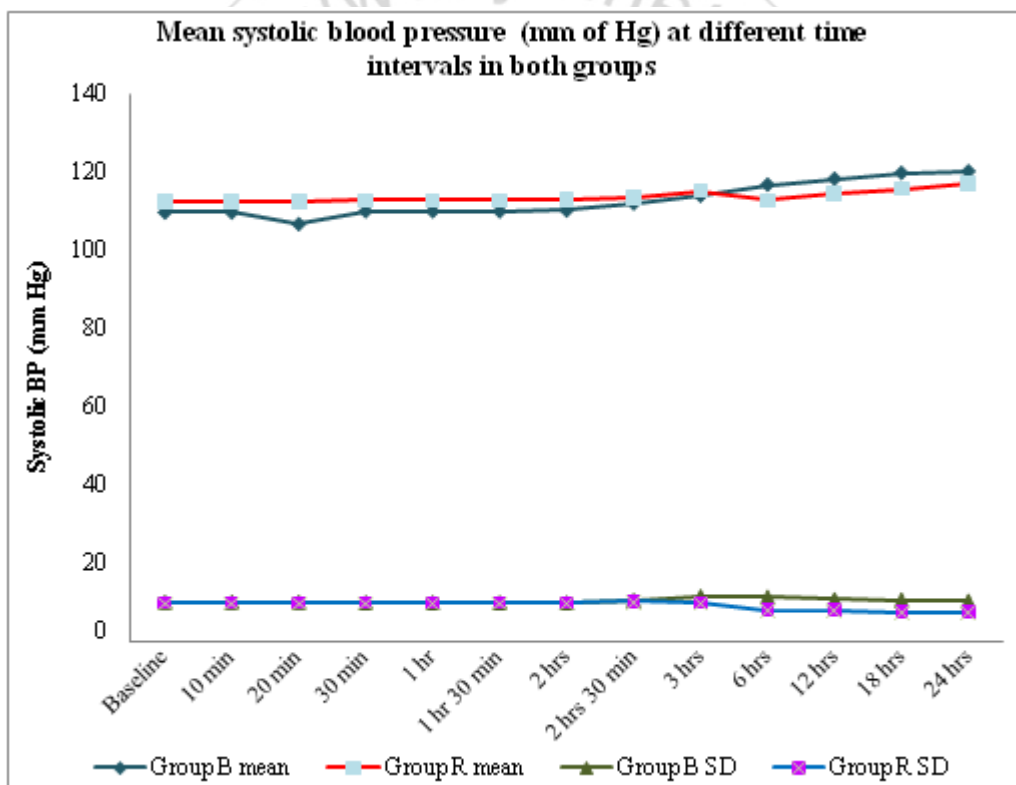


Figure 4: blood pressure changes in both groups in different intervals

There were no statistically significant changes in pulse rate and blood pressure between two groups in first 24 hours ($p > 0.05$). However at 6, 12 and 18 hours, there were significantly low pulse rate and low blood pressure in Group R compared to Group B ($p < 0.05$).

There was statistically significant difference in VAS score at 6 hours ($p < 0.05$) and 12 hours ($p < 0.01$) after performing the block.

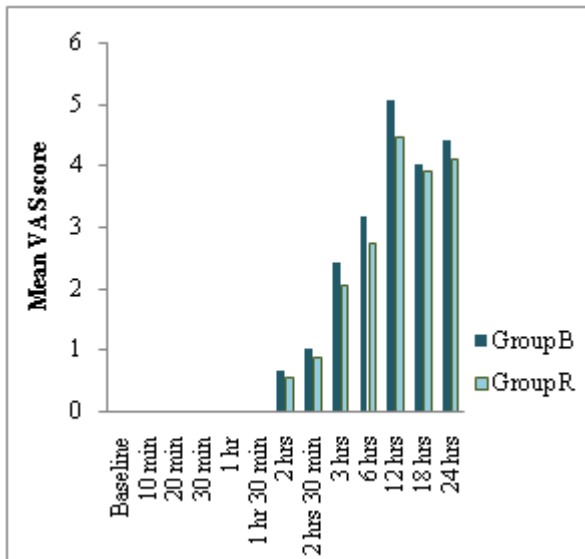


Figure 5: Mean Visual Analogue Score (VAS) at different time intervals in both groups at rest

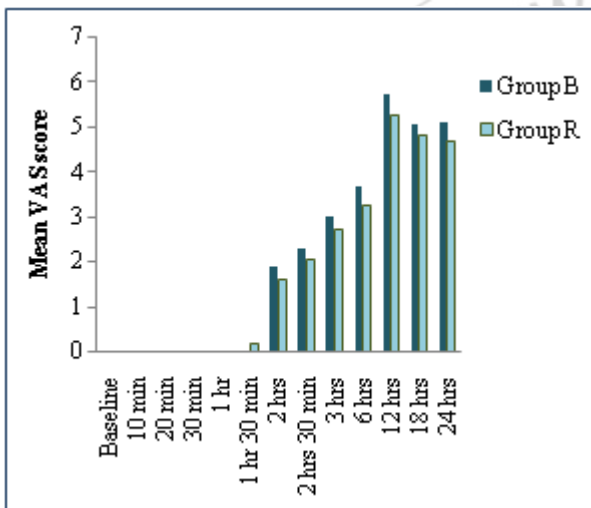


Figure 6: Mean Visual Analogue Score (VAS) at different time intervals in both groups during movement

Table 4: Total duration of analgesia

	Group B	Group R	P value
Duration of analgesia (hours)	7.38±2.35	9.98±2.38	<0.01

The mean duration of analgesia was 7.38±2.35 hours in Group B and 9.98±2.38 hours in Group R. The difference was statistically highly significant in Group R compared to Group B (p<0.01).

Table 5: Postoperative analgesic consumption in 24 hours

Number of dose of analgesic	Group B	Group R
1 dose	52%	74%
2 doses	48%	26%
Mean±SD	1.48±0.50	1.26±0.44
P value	<0.05	

None of the patients in either group had any side effects.

6. Discussion

Pain is the most frequent cause of suffering and disability which seriously impairs the quality of life of millions of people worldwide. Relief of pain during surgery and in post-

operative period is one of the mainstays of balanced anaesthesia.

The TAPB is a simple and effective analgesic technique, appropriate for surgical procedures where parietal pain is a significant component of postoperative pain. It can be performed when neuraxial blocks are contraindicated and it provides an alternative analgesic technique.

Rafi et al. (2001)⁹ was the first to describe this novel abdominal field block. He described an anatomical landmark technique and provided evidence of blockade to the mid/lower thoracic and upper lumbar spinal nerves as they travelled in the fascial plane between the transversus abdominis and internal oblique muscles. Hebbard et al. (2007)⁴ have subsequently described an ultrasound-guided approach to the TAP Block. It has been performed for the following procedures: caesarean delivery⁵, hysterectomy⁶, hernioplasty, retropubic prostatectomy⁸, appendicectomy⁷ and laparoscopic cholecystectomy².

The efficacy of TAP block was also studied by Belavyet al¹ using Ropivacaine 0.5% as one tool of multimodal analgesia in addition to PCA morphine, Paracetamol and NSAIDs regularly, but in this study, Inj. Diclofenac was the single analgesic given to the patient, if post-operative analgesia was required. Efficacy of block was evaluated by assessing pain level with VAS and the post-operative analgesic consumption.

Shibata Y, Sato Y, Fujiwara Y et al (2007)¹⁴ assessed the extent of ultrasound guided TAP block by pinprick in 26 patients undergoing laproscopic gynaecological surgery. They found that the mean upper level of sensory block at 30 min after local anaesthetic injection was T10. They concluded that lower abdominal surgery should be an indication for TAP block.

These studies indicate that deposition of local anaesthetic solution in Transversus Abdominis Plane can block T8 to L1 segments which innervate lower abdominal wall and provide analgesia if these nerve roots are blocked. So we decided to assess the efficacy of TAP block for postoperative analgesia in lower abdominal surgeries like hernia repair, appendicectomy.

In various studies conducted to assess the efficacy of TAPB, it was given in addition to the standard analgesic regimen (patient control IV morphine analgesia, NSAIDs and acetaminophen) and subsequent analgesic requirement was compared with placebo. In our study, we used TAPB as sole method of providing postoperative analgesia.

In our study, duration of post-operative analgesia was 7.38±2.35 hours in Group B and 9.98±2.38 hours in Group R. The difference was statistically highly significant (p<0.01).

Concerning haemodynamics, in our study there were no statistically significant changes in pulse rate and systolic blood pressure between two groups in first 24 hours (p>0.05). However at 6, 12 and 18 hours, there were significantly low pulse rate and systolic blood pressure in Group R compared to Group B (p<0.05). There were no

statistically significant changes in diastolic blood pressure between two groups in first 24 hours ($p > 0.05$).

This difference may be due to relative rise in pulse and systolic blood pressure in Group B because longer duration of analgesia was maintained in Group R. **El-Dawlatly AA, Turkistani A and colleagues (2009)¹⁵, McDonnell JG et al (2007)¹¹, Niraj G et al (2009)¹²** They found that ultrasound guided TAP block with Bupivacaine significantly reduced postoperative morphine consumption in the first 24 hours & also Visual Analogue Pain scores in the TAP block group soon after surgery and at 24 hours so comparable with our study.

Ultrasonographic guidance enable exact placement of local anaesthetics between internal oblique and transversus abdominis muscle. There are reports of visceral damage when the needle went too far like liver injury³. Accidental intravascular injection of local anaesthetic and infection can also be considered as potential complication of TAP block. No side effects were noted in present study.

7. Conclusion

Transversus Abdominis Plane Block (TAP Block) provides postoperative analgesia with Bupivacaine and Ropivacaine in lower abdominal surgeries, where parietal wall pain forms a major component of pain. But, 0.5% Ropivacaine provides longer duration of postoperative analgesia compared to 0.25% Bupivacaine. So, looking to safety profile, longer duration of postoperative analgesia and patient satisfaction, 0.5% Ropivacaine can be used for TAP block.

References

- [1] Belavy D, Cowlshaw PJ, Howes M, Phillips F: Ultrasound-guided transversus abdominis plane block for analgesia after Caesarean delivery. *Br J Anaesth* 2009; 103(5):726-730.
- [2] EL-Dawlatly AA, Turkistani A, Kettner SC, et al. Ultrasound-guided transversus abdominis plane block: description of a new technique and comparison with conventional systemic analgesia during laparoscopic cholecystectomy. *Br J Anaesth* 2009; 102.
- [3] Farooq M, Carey M. A case of liver trauma with a blunt regional anaesthesia needle while performing transversus abdominis plane block. *Reg Anesth Pain Med* 2008; 33:274-5.
- [4] Hebbard P, Fujiwara Y, Shibata Y, Royse C. Ultrasound-guided transversus abdominis plane (TAP) block. *Anaesth Intensive Care* 2007; 35: 616-7.
- [5] McDonnell JG, Curley G, Carney J, et al. The analgesic efficacy of transversus abdominis plane block after caesarean delivery: a randomized controlled trial. *Anesth Analg* 2008; 106: 186-91.
- [6] McDonnell JG, O'Donnell B, Curley G, Heffernam A, Power C, Laffey JG. The analgesic efficacy of transversus abdominis plane block after abdominal surgery: a prospective randomized controlled trial. *Anesth Analg* 2007; 104: 193-7.
- [7] Niraj G, Searle A, Mathews M, Misra V, Baban M, Kiani S, Wong M: Analgesic efficacy of ultrasound-guided transversus abdominis plane block in patients

- undergoing open appendectomy *Br J Anaesth*; 103(4):601-605, 2009.
- [8] O'Donnell BD, McDonnell JG, McShane AG. The transversus abdominis plane (TAP) block in open retropubic prostatectomy. *Reg Anesth Pain Med* 2006; 31: 91.
- [9] Rafi AN. Abdominal field block: A new approach via the lumbar triangle. *Anaesthesia* 2001; 56:1024-6.
- [10] Farooq M, Carey M. A case of liver trauma with a blunt regional anaesthesia needle while performing transversus abdominis plane block. *Reg Anesth Pain Med* 2008; 33:274-5.
- [11] McDonnell JG, O'Donnell B, Curley G, Heffernam A, Power C, Laffey JG. The analgesic efficacy of transversus abdominis plane block after abdominal surgery: a prospective randomized controlled trial. *Anesth Analg* 2007; 104: 193-7.
- [12] Niraj G, Searle A, Mathews M, Misra V, Baban M, Kiani S, Wong M: Analgesic efficacy of ultrasound-guided transversus abdominis plane block in patients undergoing open appendectomy *Br J Anaesth*; 103(4):601-605, 2009.
- [13] Rafi AN. Abdominal field block: A new approach via the lumbar triangle. *Anaesthesia* 2001; 56:1024-6.
- [14] Shibata Y, Sato Y, Fujiwara Y, Komatsu T. Transversus abdominis plane block. *Anesth Analg* 2007; 105:883.
- [15] EL-Dawlatly AA, Turkistani A, Kettner SC, et al. Ultrasound-guided transversus abdominis plane block: description of a new technique and comparison with conventional systemic analgesia during laparoscopic cholecystectomy. *Br J Anaesth* 2009; 102.