

Types of Ossified Pterygospinous Ligament and Its Clinical Implications

J. Leonoline Ebenezer¹, J. Chanemougavally²

^{1,2} Tutor, ACS Medical College and Hospital, Chennai – 600 077, India

Abstract: ***Aim:** To study the anatomical aspects of ossified pterygospinous ligament in adult human skulls. **Objective:** The pterygospinous ligament extends from the spine of the sphenoid to the posterior border of the lateral pterygoid plate. Rarely is it ossified. This study was done to know the abnormal ossification of the ligament and to alarm the dental surgeons, the anaesthetics, neurosurgeons of its clinical implications. **Materials and Methods:** 100 adult dry skull bones, vernier caliper and thread were used. Using vernier caliper, the length & breadth of the ossified pterygospinous ligament and the diameter of pterygospinous foramen were measured. **Results:** Out of 100 Skulls studied, the ossified pterygospinous ligaments were present in 11 Adult dry skull bones. **Conclusion:** The study showed the anatomical aspects of a complete & incomplete ossified pterygospinous ligament. The ossified pterygospinous ligament normally results in the formation of a pterygospinous foramen which may compress the branches of the mandibular nerve and chorda tympani nerve causing neuralgic pain in the area of supply of that particular nerve. Such variations are of great clinical significance for radiologists, dental surgeons, anaesthetists, neurosurgeons to plan their procedure before treating the patients.*

Keywords: Pterygospinous ligament, Pterygospinous bar, pterygospinous foramen, spine of sphenoid, lateral pterygoid plate

1. Introduction

Sphenoid bone is one of the unpaired bone that lies in the base of skull looking like a bat (mammal). It is located between the orbital plate of frontal bone, petrous part of temporal bone and basilar part of occipital bone. It has a body in the Centre, a pair of lesser and greater wings on the sides and two pterygoid processes namely medial and a lateral plate, extending from the junctions of body and greater wing of sphenoid bone. The pterygospinous ligament extends from the upper margin of posterior border of lateral pterygoid plate of the sphenoid bone to the spine of sphenoid. Rarely this ligament is ossified. This ligament is also known as 'ligament of Civinini' [15]. It may be phylogenetic remnant in human being [15]. Calcification of soft tissues also leads to ossification. The ossification starts from below upward. A variable pterygospinous ligament extending from the irregular posterior border of lateral pterygoid plate is connected by a ligament to the sphenoid spine is rarely ossified [1]. Ossified pterygospinous bars were of two types either complete or incomplete. In complete Ossified pterygospinous type, the bony bars extended from lateral pterygoid plate to the spine of sphenoid. In case of complete pterygospinous bar, a pterygospinous foramen was present. In incomplete Ossified pterygospinous type the pterygospinous ligament bar was deficient and did not make a contact with the spine of sphenoid.

2. Aim

The study was done to determine the prevalence of ossified pterygospinous ligament in adult human skulls with its types. It was done to know its clinical implications like the mandibular neuralgia including lingual neuralgia caused due to the compression of branches of mandibular nerve in pterygospinous foramen.

3. Materials and Method

For the study, a total of 100 dry adult human skulls were taken. The vernier caliper and thread were used for the measurement. The measurements like pterygospinous bar length and breadth in complete type, distance between the two ends of incomplete pterygospinous bars, and pterygospinous foramen diameter were measured with the help of vernier caliper.

4. Observations

As stated in table 1 the Pterygospinous bars were found to be present in 11 skulls (11%) as shown in figure 1, out of which completely ossified pterygospinous bony bridges as shown in figure 2, were present in 4 skulls (4%) and in three skulls the completely ossified pterygospinous bony bridges were present bilaterally and in one skull the completely ossified pterygospinous bony bridges was present on the left side. Incompletely ossified pterygospinous ligaments as shown in figure 3, were present in 7 skulls. It is present in one skull on the right side and in 3 skulls on the left side, total of 4 skulls had incompletely ossified pterygospinous ligaments unilaterally and 3 skulls had it bilaterally. All these findings have been recorded.

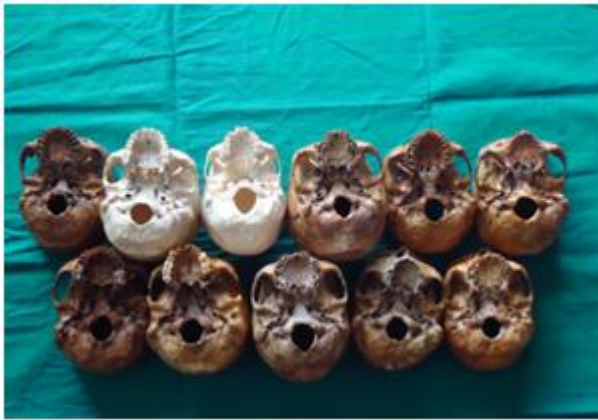

Figure 1: Completely and incompletely ossified pterygospinous ligament

Table 1: Incidence of ossified pterygospinous ligament and pterygospinous foramen in present study

Total no of skulls studied - 100				
Presence of ossified pterygospinous ligament -11(11%)				
Incompletely ossified pterygospinous ligament (11%)	Unilateral/ bilateral	Side(right/left)	No.	%
		U/L	Rt	1
		Lt	3	3
	B/L	Both Rt& Lt	3	3
completely ossified pterygospinous ligament (4)	U/L	Rt	0	0
		Lt	1	1
		B/L	Both Rt& Lt	3

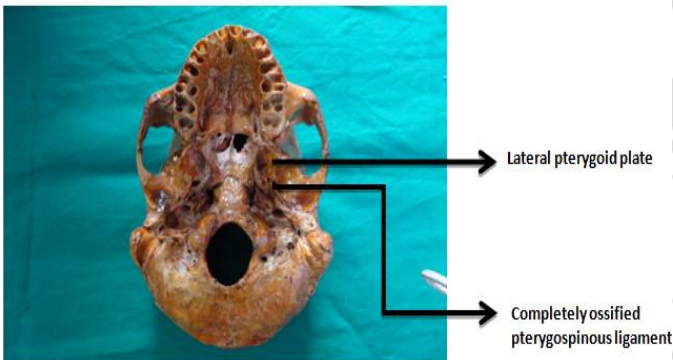


Figure 2: Completely ossified pterygospinous ligament

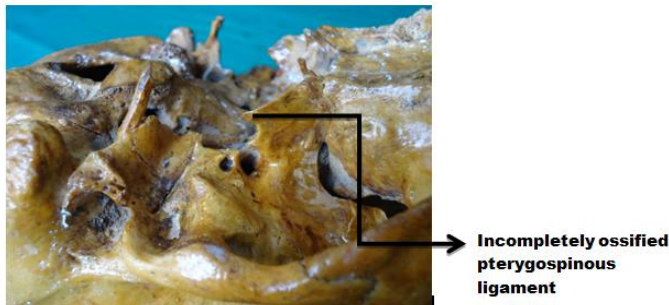


Figure 3: Incompletely ossified pterygospinous ligament

Table 2 represents the measurements of pterygospinous bar and foramen. In case of complete pterygospinous bony bar the length of the pterygospinous bony bar ranged from 4.5 mm to 9.5 mm while breadth of the pterygospinous bony bar varied

from 1 mm to 3.5 mm; the maximum diameter of the pterygospinous foramen ranged from 5.5mm to 10.5 mm. In incomplete pterygospinous bar, the distance between the two ends of the pterygospinous bar ranged from 3.5 mm to 7.5 mm.

Table 2: Measurements of ossified pterygospinous ligament .

Types of ossified pterygospinous ligament	Length/breadth/diameter	Rt side in mm	Lt side in mm
Incompletely ossified pterygospinous ligament	Distance inbetween the two ends of Incompletely ossified pterygospinous ligament	6	4
Completely ossified pterygospinous ligament	Mean length of ossified Pterygospinous ligament	7	7.2
	Mean breadth of ossified Pterygospinous ligament	2	2.4
	Mean diameter of Pterygospinous foramen	7.6	8

5. Results & Discussion

The Pterygospinous bars were found to be present in 11 skulls (11%) out of which completely ossified pterygospinous bony bridges were present in 4 skulls (4%) and 3 skulls had it bilaterally and 1 skull had it on the left side. Incompletely ossified pterygospinous ligaments were present in 7 skulls and unilaterally present in 1skull on the right side and in 3 skulls on the left side and 3 skulls had it bilaterally.

U.SolomonKrupanidhietal[22], Analysed morphological exposure of the presence of bilateral ossified pterygospinous ligament and civinini’s foramens which are clinically important with an incidence 0.95% found 1 out of 105 dried human adult skull bones of either sex.

Peker et al[18] studied 452 adult dry crania in Anatolian population. He observed that completely ossified pterygospinous ligament was found in 5.5% skulls. The complete pterygospinous bony bridges were 4.2% on the right side and 6.4% on the left side. In (3.1%) that is in 14 out of 452 skulls complete pterygospinous osseous bars were bilateral. The course of the mandibularnerve branches were affected by the ligament.

In 1949 Chouke[6]in an anatomical study of European skulls, they observed the presence of the pterygospinous foramen in 5% of the cases studied. A corresponding study of over 6000 sample skulls confirmed their results.

In 1951, Chouke and Hodes[7] analysed the pterygoalar bar in 7.05% of their 1234-patient sample (in 0.89% bilaterally).

Shindeetal [19] and Shweta Solanetal [20]stated that ossified pterygospinous ligament is one of therare anomaly.

Lüdinghausen et al[15] said that a complete osseous bar, arch, or lamina connecting the posterior border of lateral plate of pterygoid process and sphenoidal spine was found in 6 out of the 100 human dry skulls and in 1.85% cadavers.

Shinde et al[19] study states that in a total of 65 skulls, the incompletely ossified pterygospinous ligament was present in only 2 cases out of which one skull had it on the left side and the other had it to the right side. The smaller gap between the posterior border of lateral pterygoid plate and the spine of sphenoid was measured to be 3 mm in both cases.

Nayak et al[16] observed pterygospinous bony bar in 416 dry human skulls of Indian (Dravidian) origin and found that the total incidence was 9.61%, complete pterygospinous bar in 5.76% skulls and incomplete pterygospinous foramen in 3.84%.

Verma et al[24] carried out their study in 116 macerated adult human skulls and reported a total incidence of ossified pterygospinous ligament to be 18.1%. Bilateral presence of complete Pterygospinous bars/bridges has not been reported. Jones [12] stated that the lateral pterygoid plate is broader and gives attachment to pterygospinous ligament that extended backwards to the spine of sphenoid. This ligament is ossified rarely and thus a pterygospinous foramen is formed, which allows the passage of muscular branches of mandibular nerve. Rarely in the lower end of posterior border of lateral pterygoid plate there is another spine for the attachment of additional pterygospinous ligament.

Peuker et al[17] demonstrated the presence of ossified pterygospinous ligament compressing the lingual nerve between the bony bridge and medial pterygoid muscle, which resulted in lingual numbness and pain, associated with speech impairment.

Wood [25] reported 8% pterygospinous ligament ossification in Hawaiian skulls.

Agarwal et al[1] carried out the study in 67 adult human skulls of Punjab region and the incidence of pterygospinous bar was 9.7%. The complete pterygospinous bars in 2.99% skulls and incomplete pterygospinous bars in 6.72% skulls.

Atamaz-Pinar et al[4] found incompletely ossified pterygospinous ligaments in 35 cases and completely ossified pterygospinous ligament in 12 cases out of 361 dry adult human skulls.

Antonopoulou et al[3] study states that in 50 Greek dry skulls, the completely ossified pterygospinous bar in 1 skull bilaterally and incompletely ossified pterygospinous bar in 25 out of 100 observations. The three-dimensional reconstruction in a CT image was done for the above observations.

Kapur et al[13] reported about the prevalence of 18.36% of pterygospinous bars in a sample of 305 Croat skulls. Incomplete ossification of pterygospinous ligament was found in 14.7% skulls, unilaterally in 33 skulls and bilaterally in 12 skulls. Complete ossification of pterygospinous ligament was found in 3.6% skulls. 1.31% bilaterally and 1.31% on the right side and 0.98% on the left side. They highlighted that the presence of an ossified Pterygospinous ligament may prevent

anaesthesia of mandibular nerve at the lateral sub-zygomatic approach.

The present study reveals an incidence of 11% which is similar with the results of earlier studies of Indian skulls studied by Nayak et al[16], Agarwal et al[1] and Anjooyadav et al[2]

In 1935 De Froe and Wagenaar[8] was the first to recognize radio graphically the pterygoalar bar in X-rays of the Foramen Ovale. They also focussed that the presence of the ossified pterygoalar ligament can interfere with the neural projection of the semilunar ganglion.

In the present study completely ossified pterygospinous bar was present in 4 out of 100 skulls. It resulted in a well-defined pterygospinous foramen while Anjooyadav et al[2] found that completely ossified pterygospinous bars were present in 11% skulls with well-defined pterygospinous foramen. Bilateral presence of complete Pterygospinous bars were there in three skulls in the present study similar to U. Solomon Krupanidhi et al[22], who stated that presence of bilateral ossified pterygospinous ligament and Civinini's foramens are clinically important with an incidence of 0.95%. From the above studies it is clear that the incomplete variety was more common than the complete one.

Shinde et al[19] and Das and Paul[9] observed only incompletely ossified Pterygospinous ligament in 2 out of 65 skulls and only 1 case in 50 skulls respectively.

The osseous pterygospinous variations are of great clinical significance. The mandibular nerve branches mainly muscular and lingual nerves are mainly affected by the pterygospinous bar. In humans this bony bar represents a phylogenetic remnant.

Skrzat et al[21] stated that during attempts to relieve the Trigeminal Neuralgia, ossified ligaments can obstruct the passage of the needle into the Foramen Ovale, thus disabling the anaesthetization of the trigeminal ganglion or the Mandibular Nerve.

In 1946 Chouke[5] found out that the pterygoalar foramen was found four times as often in the skulls of Africans than in those of Caucasians; the ratio for males and females being the same at 4:1.

The important structures in and around foramen ovale are otic ganglion, middle meningeal artery and vein, tympanic nerve, branches of mandibular nerve, and medial and lateral pterygoid muscles are affected in complete or incomplete pterygospinous bar. These structures may get compressed against these bony formations and can produce symptoms like pain during chewing, and could provoke trigeminal neuralgia [14].

Faig-Leite H et al[11] stated that the pterygospinous ligament is located near to foramen ovale and it is of great anatomical, clinical and surgical importance because the ossified

pterygospinous ligaments may compress neurovascular structures in the region of foramen ovale and can cause trigeminal neuralgia.

The chorda tympani nerve may also be compressed by the ossified pterygospinous bar and its involvement would result in abnormal taste sensation in the anterior two-thirds of the tongue [9].

Suazo G et al[23], expressed that the ossified pterygospinous ligaments may produce difficulty in locating the foramen ovale in therapeutic approach.

The pterygospinous bony bridge can also pass among the fibers of the lingual nerve and divide it into anterior and posterior parts. Anterior part lies between tensor velipalati muscle and the bony bridge, so these fibers are vulnerable to the risk of compression [10].

In the presence of an ossified pterygospinous ligament, the main trunk of mandibular nerve is redirected laterally and its dividing branches the lingual nerve and the inferior alveolar nerve have to cross the extended lateral pterygoid plate. Because of this abnormal course, there is greater chance for neuralgia to occur due to the nerves becoming compressed between the osseous structures and muscles [15].

Reason for ossification of pterygospinous ligament is not known but formations of ossified pterygospinous ligament were more frequently present in males and unilateral presence was more common than bilateral one.

While applying conductive anaesthesia on the mandibular nerve by lateral subzygomatic route, presence of these ossified structures at the lateral plate's posterior border of pterygoid process should be well noted and verified [13]

In the presence of an ossified pterygospinous ligament, there may be failure of anaesthesia in cases of treatment of trigeminal neuralgia, or be an obstacle for the mandibular nerve block a preferred method for pain relief especially in fractures of mandible or cancer patients [4], [17]

6. Conclusion

The present study is important especially for anaesthetists, surgeons, dentists, anatomists and anthropologists to know the different types of osseous bridges and their incidence in the region of cranial base for their treatment plan.

Out of 100 adult human skulls studied, the presences of pterygospinous bars were present in 11(11%) skulls. The completely ossified pterygospinous ligament was present in 4 skulls (4%) and incomplete ossified pterygospinous ligament was present in 7 skulls (7%).

Such anatomical variations is important because ossified pterygospinous ligament both complete and incomplete can result in compression of mandibular nerve branches, chorda

tympani nerves and structures related close to foramen ovale resulting in various clinical symptoms.

7. Acknowledgement

I extend my gratitude to Mrs. J. Chanemougavally, and Miss. Jayashree, Mr. V. Anurajawho helped me a lot in measuring the parameters and in collecting the reviews in the present study.

References

- [1] Agarwal B, Gupta M, Kumar H. Ossified ligaments of the skull. *Journal of the Anatomical Society of India*. 2012; 61(1):37–40.
- [2] AnjooYadav, Vinod Kumar, and RichaNiranjan, "Pterygospinous Bar and Foramen in the Adult Human Skulls of North India: Its Incidence and Clinical Relevance," *Anatomy Research International*, vol. 2014, Article ID 286794, 5 pages
- [3] Antonopoulou M, Piagou M, Anagnostopoulou S. An anatomical study of the pterygospinous and pterygoalar bars and foramina—their clinical relevance. *Journal of Cranio-Maxillofacial Surgery*. 2008; 36(2):104–108. [PubMed]
- [4] Atamaz-Pinar Y, Arsu G, Aktan-Ekiz ZA, Bilge O. Pterygospinous and pterygoalar bridges. *Sendrom*. 2004; 16(7):66–69.
- [5] Chouke KS (1946). On the incidence of the foramen of Civinini and the poruscrotaphitico-buccinatorius in American Whites and Negroes: I. Observations on 1544 skulls. *Am J PhysAnthropol*, 4(2): 203–225.
- [6] Chouke KS (1949). Injection of mandibular nerve and gasserianganglion;an anatomic study. *Am J Surg*, 78(1): 80–85.
- [7] Chouke KS, Hodes PJ (1951). The ptergoalar bar and its recognition by Roentgen methods in trigeminal neuralgia. *Am J Roentgenol*, 65(2): 180–182
- [8] De Froe, Wagennar JH (1935). Bedeutung des Poruscrotaphitico-buccinatorius und des Foramen pterygos- pinosumfürNeurologie und Röntgenologie. *FortschrRöntgenstr*, 52: 64–69.
- [9] Das S, Paul S. Ossified pterygospinous ligament and its clinical implications. *BratislavskéLekárskeListy*. 2007; 108(3):141–143. [PubMed]
- [10] Erdogmus S, Pinar Y, Celik S. A cause of entrapment of the Lingual nerve: ossified pterygospinous ligament- a case report. *Neuroanatomy*. 2009; 8:43–45.
- [11] Faig-Leite H, Faig-Leite FS, Fernandes RG. Anatomia do ligamentopterigoalar e do for a mecrotafticobucinatório [resumo]. *Int J Morphol*, 2007; 25:15. 12
- [12] Jones FW. *Buchanan's Manual of Anatomy*. 7th edition. London, UK: Bailliere, Tindall& Cox; 1946.
- [13] Kapur E, Dilberović F, Redzepagić S, Berhamović E. Variation in the lateral plate of the pterygoid process and the lateral subzygomatic approach to the mandibular nerve. *Medicinskiarhiv*. 2000; 54(3):133–137. (PubMed)

- [14] Krmpotić-Nemanić J, Vinter I, Hat J, Jalšovec D. Mandibular neuralgia due to anatomical variations. *European Archives of Oto-Rhino-Laryngology*. 1999; 256(4):205–208. [PubMed]
- [15] Lüdinghausen M, Kageyama I, Miura M, AIKhatib M. Morphological peculiarities of the deep infratemporal fossa in advanced age. *Surgical and Radiologic Anatomy*. 2006; 28(3):284–292. [PubMed]
- [16] Nayak SR, Saralaya V, Prabhu LV, Pai MM, Vadgaonkar R, D'Costa S. Pterygospinous bar and foramina in Indian skulls: incidence and phylogenetic significance. *Surgical and Radiologic Anatomy*. 2007; 29(1):5–7. [PubMed]
- [17] Peuker ET, Fischer G, Filler TJ. Entrapment of the lingual nerve due to an ossified pterygospinous ligament. *Clinical Anatomy*. 2001; 14(4):282–284. [PubMed]
- [18] Peker T, Karaköse M, Anil A, Turgut HB, Gülekon N. The incidence of basal sphenoid bony bridges in dried crania and cadavers: their anthropological and clinical relevance. *European Journal of Morphology*. 2002; 40(3):171–180. [PubMed]
- [19] Shinde VS, Mallikarjun M, Patil R. A study on an ossified pterygospinous ligament. *Journal of Clinical and Diagnostic Research*. 2011;5(5):978–979.
- [20] ShwetaSolán and Gokul Krishna Reddy Nune. Anomalous ossified pterygospinous ligament in eastern Zone- a case study. *IOSR-JDMS* 2014; 13 (4): 60-62
- [21] Skrzat J, Walocha J, Srodek R (2005). An anatomical study of the pterygoalar bar and the pterygoalar foramen. *Folia Morphol*, 64(2): 92–96.
- [22] U. Solomon Krupanidhi et al, A Study on Bilateral Ossified Pterygospinous Ligament and Its Clinical Significance, *International Journal of Biomedical Research*, 2014, 05 (09), 563-565
- [23] Suazo G, Zavando, M. D, Smith, R.L. Anatomical Study of the Pterygospinous and Pterygoalar Bony Bridges and Foramina in Dried Crania and its Clinical Relevance. *Int. J. Morphol.*, 2010; 28(2):405-408.
- [24] Verma RK, Rani A, Chopra J, Pankaj AK, Kumar N. Civinini Bar: incidence in North Indians and its clinical relevance. *NJCA*. 2013; 2(3):128–133.
- [25] Wood JF. The non-metrical morphological characters of the skulls as criteria for racial diagnosis. *Journal of Anatomy*. 1931; 65:179–195. [PMC free article] [PubMed].



Mrs.J. Chanemougavally received M.Sc Medical Anatomy from SRM Medical College and Hospital in 2011. She worked in Venkateshwara Medical College initially and at present working in A.C.S Medical College.

Author Profile



Dr. J. Leonoline Ebenezer received the B.H.M.S Degree from Tamil Nadu Dr.M.G.R Medical University in 2009 and M.Sc Medical Anatomy from SRM Medical College and hospital in 2012. She worked in Ragas Dental College initially and at present working in A.C.S Medical College.