

# Branching Pattern of Middle Cerebral Artery

Dr. S. Sundari, M. S.,(Anatomy)

**Keywords:** Artery of cerebral Haemorrhage. Artery of circle Willis. Terminal branch of internal carotid artery

## 1. Introduction

Middle cerebral artery is the largest of the terminal branches of the internal carotid artery. It lies in the cistern of stem of lateral sulcus/sylvian fissure accompanied by superficial middle cerebral vein in the inferior surface of cerebrum. Then it comes to the lateral sulcus and divides into superior and inferior division which come to the posterior ramus of the lateral sulcus of the cerebrum.

The proximal middle cerebral artery (M1 segment) give rise to the perforating Branches (Termed Lenticulo striate arteries) that supplies the putamen, outer Globus pallidum, posterior limb of internal capsule above the plane of upper border of Globus Pallidum, the adjacent corpora Radiata and the body of upper and lateral head of caudate nucleus in the sylvian fissure. The middle cerebral artery is mostly divides in to superior and inferior division.

Superior division gives rise to lateral-orbito frontal which supplies the Pre frontal cortex. The pre Rolandic branch which supplies the middle and posterior parts of superior, middle and inferior Frontal Gyrus. Frontal eye field area and Brocas area. A Rolandic branch which supplies the pre central and post central Gyrus except the leg area and Brocas area. Anterior parietal which distributes to the parietal association cortex and above the supra marginal Gyrus.

Inferior division supplies the two third of individuals. Superior division that supplies region above the angular Gyrus.

## 2. Method of Study

### M1 Segment

- Length of M1 segment is noted from the origin of the middle cerebral artery from the internal carotid artery. The length of M1 was measured. Variation in the mode of course and termination of M1 were also looked.
- Size of Lumen also measured.
- Branches, Numer, Gyrus to which enter any other artery to the same Gyrus . If so size of the lumen of both are noted.
- Angle of origin of each division are noted.
- Termination of M1 segment and number of divisions are noted.
- Sources of origin of middle cerebral artery and source of other arteries if any noted.
- Site and level of origin of internal carotid artery is noted & its terminal branch.
- Size of lumen of middle cerebral artery and compared with other terminal branches for all function of the area.

### Observation

- Angle of origin on fronto polar is 110°
- Angle of origin of pre frontal is 120°
- Angle of origin of orbito frontal is 130°
- It occurs in 94% of cases.
- Only in 6% the angle of fronto polar is 110°
- Angle of pre frontal is 130°
- Angle of origin of orbito frontal is 150°
- In 3 cases middle cerebral artery divides into superior middle and inferior division.
- M1 length is 30 mm.
- Lumen size is 6 mm.
- Angle of origin of pre Rolandic 110°
- Angle of origin of Rolandic 120°
- Angle of origin of post Rolandic is 130° (Anterior parietal)
- Each branch varies 10° variation in middle cerebral artery length is 15 mm Lumen is 6 mm.
- 20° variation in middle cerebral artery is 30 mm Lumen size is 6 mm.
- Branches are superior, middle and inferior.
- Orbito frontal arises from stem & enters pre rolandic area.
- Mostly M1 segment terminated as 2 divisions.
- In 4% it divides into three divisions as superior, middle and inferior.

## 3. Lumen

Lumen size of M1 between origin and termination are noted. Lumen is same at origin and termination. Normal is 3 mm variation into 6mm.

Lenticulo striate branch appears from M1 segment is usually six in number. Four and two branches also seen.

Termination of M1 segment into superior middle and inferior division in 4% of cases. In most of cases it divides into superior & inferior division.

## 4. Conclusion

It has been observed that the middle cerebral artery was the largest of the terminal branch of internal carotid artery arising that lateral to the anterior perforated substance.

An accessory middle cerebral artery has been reported by Jain 1964. Such artery has not been found in the present study.

Size of lumen of anterior cerebral artery is between is 3-6 mm . The largest diameter of 6 mm has been observed in four specimens of which two specimens the lumen of anterior cerebral artery was only 2 mm. So it may be concluded that these two cases are more prone for anterior cerebral artery ischaemia.

Length of artery which is between 14-16 mm is majority is agree with the previous works.

The length of middle cerebral artery in 2 specimens were only 10 mm. In these cases the force of flow will be more and so prone for damage to the tunics of the arteries. In one lumen is 21 mm and another is 30 mm. So possibility for sluggish flow which is a predisposing factor for the formation of Thrombus.

Three divisions denotes liberal blood supply to all the functional lobes of cerebral cortex.

## References

[1] Hemicraniectomy in older patients with extensive middle - cerebral -artery stroke E Jutter, A Unterberg. J.

Woltzik J. Bosel – England Journal of 2014 Mass Medical section.

[2] Treatment of acute middle cerebral artery occlusion with a Solitaire AB stent preliminary experience. – S. Nayak. G. Ladumer. M. Killer – The British journal of radiology, 2014.

[3] Hyperforinattenuates brain damage induced by transient middle cerebral artery occlusion (MCAO) in rats via inhibition of TRPCS channels degradation Y Lin, JC Zhang, J Fu F Chen j Wang – Journal of Cerebral -2013.

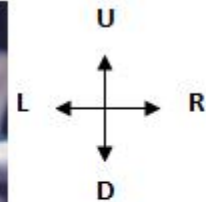
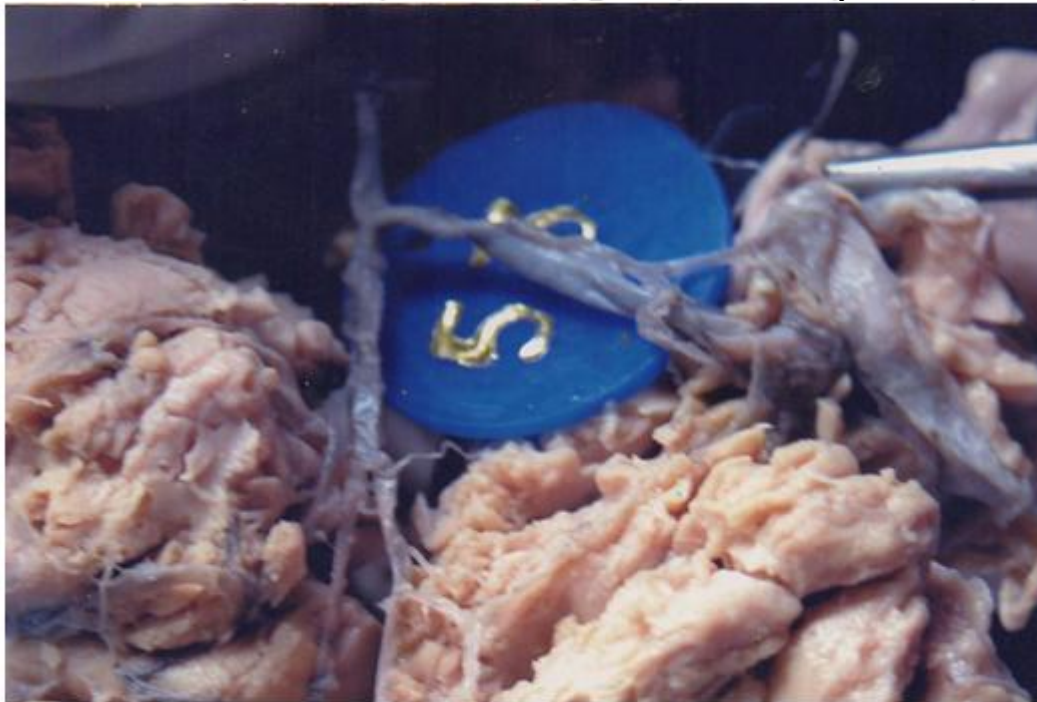[4] Assessment of leptomeningeal collaterals using dynamic CT angiography in patients with acute ischemic stroke BK Menon, B O'Brien. A Bivard. NJ Spratt – Journal of Cerebral -2013 – jcb. Sagepub. Com.

[5] Decompressivehemicraniectomy in malignant middle cerebral artery infarct.- J Zhao, YY Su, Y Zhang, YZ Zhang, R Zhao L Wang – Neurocritical care, 2012.

[6] Stent – retriever thrombectomy after intravenous t – PA vs. t-PA alone in stroke JL Saver, M Goyal, A Bonafe HC diener – England journal of – 2015.

[7] Original Research sickle cell anemia and pediatric strokes – computational fluid dynamics analysis in the middle cerebral artery. – CP Rivera, AVeneziani RE Ware – Biology and Medicine, 2016.

Three Divisions Of Middle Cerebral Artery



Orbito Frontal Arises From Stem And Connected With From To Polar

