

# Hyalinizing Trabecular Tumor of the Thyroid: A Rare Case Report

Jadhav Dnyaneshwar S.<sup>1</sup>, Dukare Sandip R.<sup>2</sup>, Kale Priyanka<sup>3</sup>

<sup>1</sup>MD Pathology, Asso. Professor, Department of Pathology. Swami Ramanand Teerth Rural Government Medical College and Hospital, Ambajogai, Maharashtra, India

<sup>2</sup>MD Pathology, Asst. Professor, Department of Pathology. Swami Ramanand Teerth Rural Government Medical College and Hospital, Ambajogai, Maharashtra, India

<sup>3</sup>MD Pathology, Resident, Department of Pathology. Swami Ramanand Teerth Rural Government Medical College and Hospital, Ambajogai, Maharashtra, India

**Abstract:** *Hyalinizing trabecular tumor (HTT) of the thyroid is a rare neoplasm that was first described by Carney in 1987. HTT may be commonly mistaken for papillary carcinoma, medullary carcinoma or paraganglioma. Due to the uncertain malignant potential and entity of this tumor, a more general term, hyalinizing trabecular tumor (HTT), has been adopted by most pathologists and the World Health Organization classification. Herein, a case of HTT is reported in detail, and the review of literature is also discussed.*

**Keywords:** Thyroid, Hyalinizing trabecular tumor, TTF-1

## 1. Introduction

Hyalinizing trabecular tumor (HTT) of the thyroid is a rare neoplasm that was first described by Carney in 1987. It is a tumor of follicular derivation with peculiar nuclear, architectural, histochemical, and immunohistochemical feature<sup>[1]</sup>. Some researchers considered this tumor a distinctive entity whereas some others considered it a non-specific configuration with thyroid lesions. It is considered as a variant of papillary carcinoma of thyroid due to similar nuclear morphology and immune profile. It also contains hyaline material that mimics amyloid so it confuses for medullary carcinoma<sup>[2]</sup>. Majority of the reported cases were benign, while a few were named hyalinizing trabecular carcinoma (HTC), which were accompanied by metastasis in the lymph nodes or the lung<sup>[3]</sup>. Due to the uncertain malignant potential and entity of this tumor, a more general term, hyalinizing trabecular tumor (HTT), has been adopted by most pathologists and the World Health Organization classification<sup>[4]</sup>.

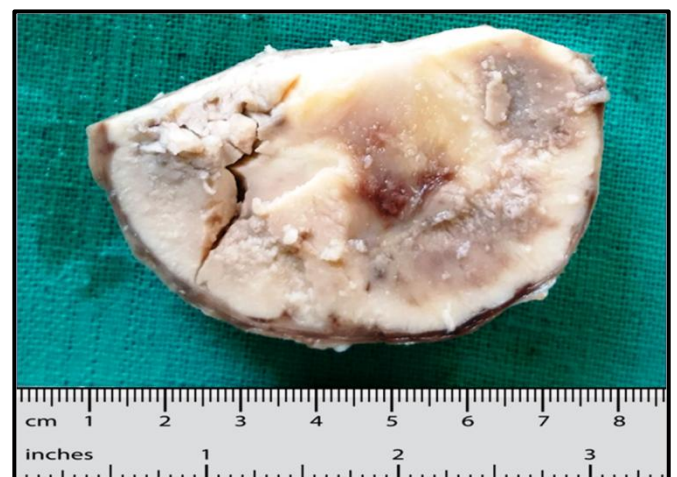In this paper, we report the clinical and pathologic features of a female patient presenting with HTT, a rare and controversial tumor with review of literature.

## 2. Case Report

A female patient 29 years of age presented with a single lump in the left side of the neck. Ultrasonography revealed a solid nodule, which was regarded as a thyroid adenoma. Thus, the intact neoplasm was surgically removed for pathological examination.

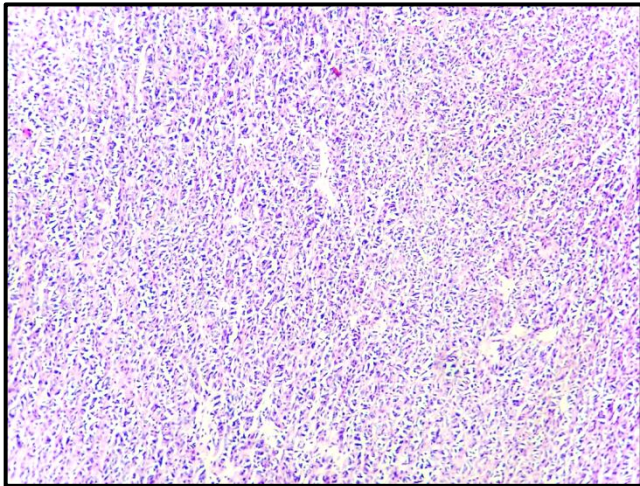
Gross investigation showed an encapsulated globular mass of 7×5.5×2 cm. The cut surface was firm whitish area with friable papillae and haemorrhagic areas [Fig 1]. Microscopically, the lump was surrounded by a thin capsule. The tumor was characterized by trabecular structures

separated by minimal fibrous stroma. Tumor cells were cuboidal to polygonal present in straight or curved trabeculae arranged perpendicular to longest axis. Tumour cells showed nuclei with papillary carcinoma features i.e. optically clear with nuclear grooving and overlapping [Fig 2 & 3]. Section also showed evidence of pale eosinophilic hyaline material and capsular invasion [Fig 4] while vascular invasion by tumour was absent. Foci of bizarre nuclei were also noted. Mitosis was extremely sparse with <1MF/20 HPF.

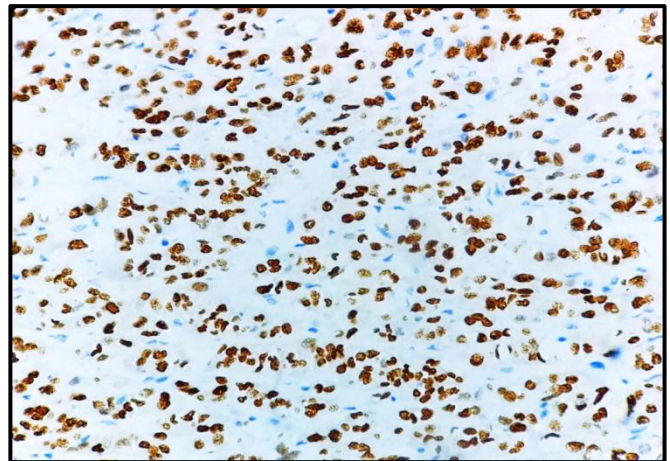


**Figure 1:** Gross photograph showing encapsulated globular mass of 7×5.5×2 cm. with c/s whitish with friable papillae and haemorrhagic areas.

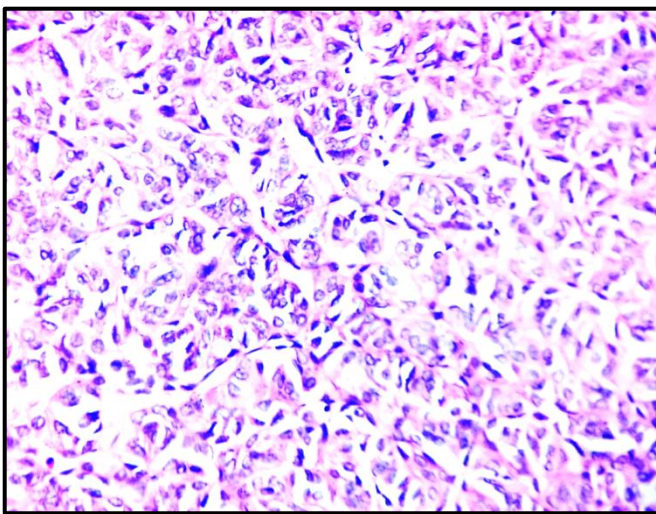




**Figure 2:** Microphotograph shows trabecular structures separated by minimal fibrous stroma(10x).



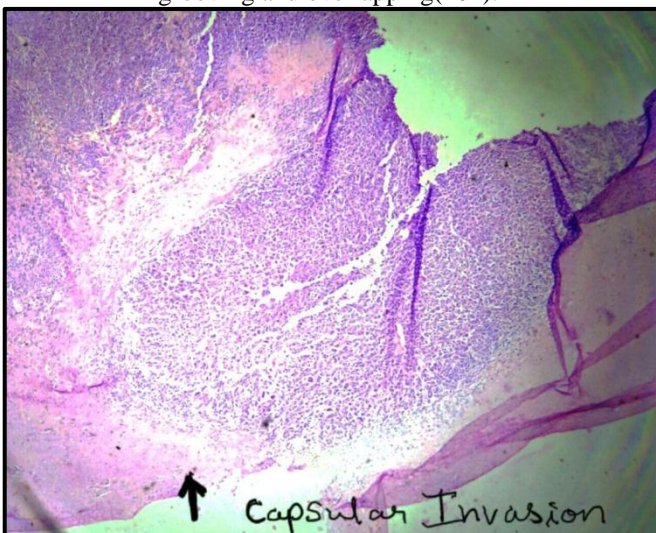
**Figure 5:** IHC: Thyroglobulin positive



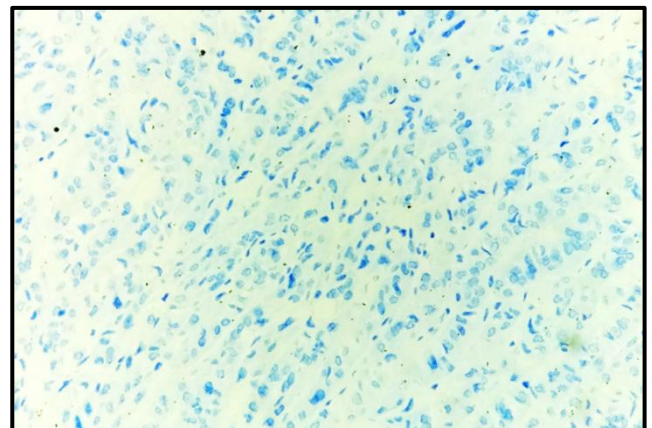
**Figure 3:** Microphotograph showing Tumour cells with papillary carcinoma features i.e optically clear nuclei with grooving and overlapping(40x).



**Figure 6:** IHC: Thyroid transcription factor-1 (TTF-1) positive.



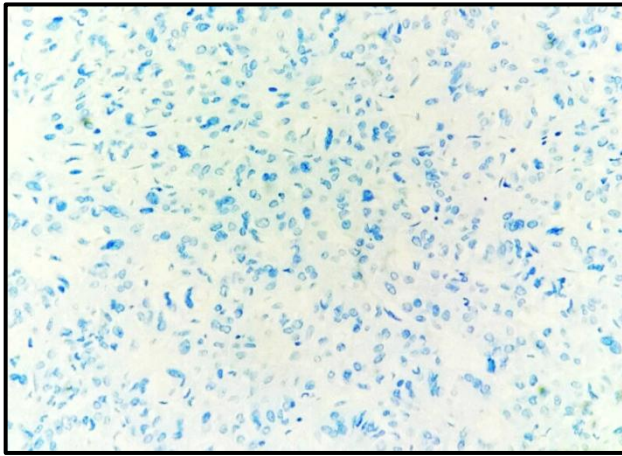
**Figure 4:** Tumor showing capsular invasion



**Figure 7:** IHC: Chromogranin A negative.

Immunohistochemical study of this tumor showed positivity for thyroglobulin, thyroid transcription factor-1 (TTF-1) [Fig5&6]and negativity for synaptophysin and chromogranin A.[ Fig 7&8] So final diagnosis of Hyalinizing trabecular tumour was made.





**Figure 8:** IHC: Synaptophysin negative

### 3. Discussion

Hyalinizing trabecular tumor of thyroid gland, prevalent in females between the fourth and fifth decades of age, was originally defined as infrequent but potentially a confusing neoplasm. Recent World Health Organization (WHO) classification of tumours of endocrine organs has defined this terminology as “a rare tumour of follicular cell origin with a trabecular pattern of growth and marked intratrabeular hyalinization”<sup>[5]</sup>. WHO classification has assigned it the term, i.e., Hyalinizing trabecular tumour (HTT)<sup>[4]</sup>.

HTT may be commonly mistaken for papillary carcinoma, medullary carcinoma or paraganglioma. Some authors believe that this tumor represents an unusual encapsulated variant of papillary carcinoma, based on the following observations:

- 1) Merging with or coexistence with typical papillary carcinoma in some cases.
- 2) Focal hyalinizing trabecular neoplasm-like areas can be seen in some typical papillary carcinomas.
- 3) Several morphologic characteristics that are shared by HTN and PTC like fine psammoma bodies, nuclear grooving and intranuclear inclusions.
- 4) Similarities in cytology to papillary carcinoma.
- 5) Similarities in immunohistochemical profile and RET/PTC rearrangements<sup>[4,6]</sup>.

According to Carney on morphology HTT exhibit a prominent trabecular arrangement and an equally prominent hyaline appearance. The trabeculae are straight or curved, resulting in curious organoid formations. The pattern of growth may simulate that of paraganglioma and medullary carcinoma<sup>[7]</sup>. HTT may also be misinterpreted as MTC because of the existence of hyaline fibrosis that mimics amyloid<sup>[8]</sup>. The hyaline material is present both in the cytoplasm of the tumor cells as the result of the accumulation of intermediate filaments and in the extracellular space (as the result of heavy deposition of hyalinized collagen fibers and basement membrane material).

By immunohistochemistry, HTT is positive for thyroglobulin and TTF-1. Whereas they show a variable positivity of galectin-3. Cytokeratin-19 is usually negative in HTT. Whereas cytokeratin 19 & galectin 3 are strongly

positive in PTC<sup>[9]</sup>. Hirokawa and Carney stated that unique cytoplasmic MIB-1 (Ki-67) expression in HTT is useful in making the distinction from PTC<sup>[10]</sup>.

The hyalinizing material in HTT is PAS positive & congo red negative and is positive for collagen type 4 in immunostaining. HTT also stains negative for calcitonin, NSE, chromogranin A or synaptophysin. On the contrary MTC is positive for congo red staining, calcitonin and neuroendocrine markers such as chromogranin A, synaptophysin, NSE and neurotensin<sup>[4]</sup>.

RET/PTC rearrangements, characteristic of PTC, were noted in HTT samples by immunohistochemistry staining and reverse transcription-polymerase chain reaction. However, RET rearrangements may also occur in other thyroid lesions, such as lymphocytic thyroiditis which is frequently associated with HTT. Mutations of the BRAF and N-ras genes shows high prevalence in PTC, such have not been detected in HTT. Also five microRNAs, which have been found to be upregulated in PTC, were verified to be downregulated in HTT. These provide evidence that HTT is distinct from PTC. Thus, to date, HTT is diagnosed as an independent neoplasm, rather than one variant of PTC<sup>[4]</sup>.

Moreover, one additional controversy is whether HTT is a benign or malignant. Rare examples of hyalinizing trabecular carcinoma (malignant) have also been reported, and the distinction from hyalinizing trabecular adenoma (benign) is based solely on the presence of vascular and/or capsular invasion<sup>[6]</sup>.

However in early reports, malignant phenotypes were not observed in histological studies, but in the recent years, HTT presenting vascular or capsular invasion with low mitosis are reported. So concerning its biologic and clinical behaviour, HTT should be considered as a benign tumor or, a tumor of extremely low malignant potential<sup>[2]</sup>. Our case showed capsular invasion (no vascular invasion) with a very low mitoses (<1/20 hpf) establishing its benign nature with very low malignant potential. The prognosis of most HTT cases is favorable, therefore, lobectomy, total thyroidectomy or hemithyroidectomy signify suitable treatments.

In summary, HTT represents a rare and controversial thyroid tumor. It has a characteristic trabecular growth pattern and hyalinizing stroma. The differentiation of HTT from other thyroid tumors such as PTC and MTC can be achieved using histochemistry and immunohistochemistry in addition to morphology. HTT is diagnosed as an independent neoplasm with a favourable prognosis.

### References

- [1] Caraci P, Fulcheri A, Ondolo C, Laino F, Volante M, Aversa S. Hyalinizing Trabecular Tumor of the Thyroid: A Case Report Head and Neck Pathol (2011) 5:423–427.
- [2] Riaz S, Bashir H, Jahangir S, Nawaz M K. Hyalinizing trabecular neoplasm of thyroid J Ayub Med Coll Abbottabad 2014;26(3)
- [3] Gowrishankar S, Pai SA, Carney JA. Hyalinizing trabecular carcinoma of the thyroid gland. Histopathology. 2008;52:529–531

- [4] Li J, Yang GZ, Gao LX, Yan WX, Jin H, Li L. Hyalinizing trabecular tumour of the thyroid: Case report and review of the literature. *ExpTher Med*. 2012;3(6):1015–7
- [5] DeLellis RA, Lloyd RD, Heitz PU, Eng C. WHO: Pathology and Genetics. Tumours of Endocrine Organs. In: Kleihues P, Sobin LE, editors. WHO Classification of Tumours. Lyon, France: IARC Press; 2004. p. 49–133.
- [6] Chan JKC. Tumors of the thyroid and parathyroid glands. In: Diagnostic Histopathology of Tumors. Fletcher CDM, Vol. II. Editors 3<sup>rd</sup> Ed. China: Elsevier; 2007. P. 997-1079
- [7] Carney JA, Ryan J, Goellner JR: Hyalinizing trabecular adenoma of the thyroid gland. *Am J SurgPathol* 1987; 11:583-591.
- [8] Evenson A, Mowschenson P, Wang H, Connolly J, Mendrinios S, Parangi S et al. Hyalinizing trabecular adenoma-an uncommon thyroid tumour frequently misdiagnosed as papillary or medullary thyroid carcinoma. *Am J Surg*. 2007;193(6):707–12.
- [9] Papotti M, Riella P, Montemurro F, Pietribiasi F, Bussolati G. Immunophenotypic heterogeneity of hyalinizing trabecular tumors of the thyroid. *Histopathology*. 1997;31:525–33
- [10] Hirokawa M, Carney JA. Cell membrane and cytoplasmic staining for MIB-1 in hyalinizing trabecular adenoma of the thyroid gland. *Am J SurgPathol*. 2000;24:575–8