

Comparative Study of Thyroid Nodule Appearance between CT & US in Hail City from 1435 to 1436 H

Abdulsalam Almulyfi¹, Diabate Adama²

¹Collage of Applied Medical Science, University of Hail. KSA

²Assistant Prof. Collage of Applied Medical Science, University of Hail, KSA

Abstract: This study indicates that, the comparison of CT and US appearance criteria to diagnose the thyroid nodule. It is was found that from PACS system with the sample size of 168 patients , the prevalence of thyroid nodule in Hail region is higher in female with 48.2% than male with 7.7% (21-40 years) respectively. The US is better in terms of diagnosis and safe to patients and personals than CT because it does not differentiate well the tissue of thyroid gland when it presents low brightness. This finding will help clinician to take a proper decision. Finally, the low brightness appearance of CT should be a subject of through future investigations.

Keywords: Thyroid nodules. Ultrasonography, Computer Tomography, Hyperechoic, Brightness.

1. Introduction

The thyroid nodule appearance in computed tomography and ultrasound is important and has received much attention in recent years due to its unknown cause. Because most of patients are exposed to computed tomography than ultrasound ⁽¹⁾. In addition to that, the thyroid nodule prevalence in Hail region is increasing dramatically with median age of 45 years old among male (ranging from 13 to 96 years), and 38 years old among female (ranging from 13 to 90 years) ⁽²⁾. While some researchers shows that ,the thyroid nodules occurs up to 50% of the adult population ⁽³⁾. Furthermore, the CT scans are highly sensitive in detecting thyroid nodules and more useful to reveal mediastinal extension, retrotracheal extension and retroclavicular extension of the mass. Since the gland contains high iodine content, the brightness of the gland is increased on a CT even without contrast ⁽⁴⁾.

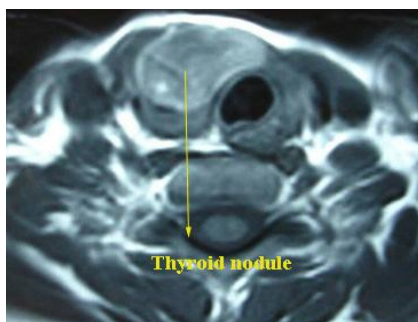


Figure 1.1: CT scan showing thyroid nodule

ultrasound present the appearance of thyroid nodules in three steps (a) nodules, (b) echo pattern of the gland, and (c) volumetric measurement. Nodules on ultrasonography appearance are commonly characterised as hypoechoic, hyperechoic , isoechoic , and echo free. In general, thyroid cancer will appears as hypoechoic nodules on ultrasonography with or without margin irregularities. In the majority of cases, thyroid carcinoma may show enhanced central vascularisation on color doppler US, and hyperfunctional adenoma may show increased vascularisation in the margins. Microcalcification is another ultrasound

feature suggestive of malignancy⁽⁵⁾. However, although the effect of thyroid nodule on patient behavior, little attention has been paid to compare between two modalities CT and US. Furthermore Mohamed, explained again in his study that, the ultrasound can find symptoms and signs about types of thyroid diseases meanwhile, ultrasound normally use high frequency transducers(7-13 MHz) to detect solid nodules of 3mm to 4 mm and cystic nodules of 2mm in diameter. Cystic nodules have a lower risk of malignancy when compared to solid nodules⁽⁶⁾.

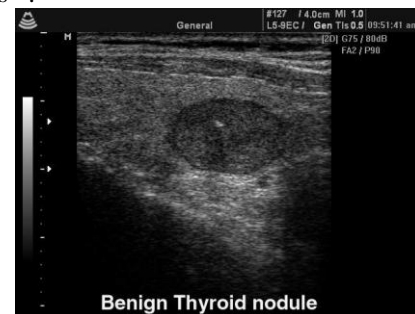

Figure 01.2: Ultrasound Showing Thyroid Nodule

Computed tomography scans revealed several common features. Palpable mass mobility was not definitive for lack of histopathological invasion. Computed tomography invasion was specific but not very sensitive for histopathological invasion. The present paper will study clinical preferences in using CT or US appearance to diagnose for safety measures for patients and care providers⁽⁷⁾.

2. Material and Methods

2.1 Patients

The current investigation involved sampling and analyzing the thyroid nodules and study the population sample (168 patients) was fluctuating between 10 to 60 years old , with PACS system , the number of male , female and children were was 19 , 147, 2 respectively with the age (ranging from 10 to 60 years) .The study observe that, the thyroid nodule occurs among female with 8.6% according to Saudi cancer

registry 2009, comparing to male 7.8 %⁽⁸⁾. The sample showed graves' type ; that will prevent a body from a virus that triggers the body defense mechanism to secrete more thyroid hormone consequently to combat thyroid nodule due to hypersecretion “ hyperthyroidism” the real reason to activate this virus still unknown whether its prevalence or manifestation in a patient , and this is a site for more clinical investigation ⁽⁹⁾.

2.2 Data Collection

The sample was collected from King Khalid Hospital, the thyroid nodules ultrasonography and computed tomogram, because most of such cases were normally admitted there. Therefore, the interview was conducted with some of patients to collect a data directly as well as co-patient, and the

majority of data were directly collected from PACS system by case only without names.

2.3 Limitation of Data

In data collection , we faces some problems relating to patient information obtaining from medical records offices and some medical staffs , their cooperation with us was not satisfactory , with reason of being confidential . In addition to that, the research faces again problem to get information from Hail General Hospital due to lack of PACS and refusal medical record office cooperation.

3. Results

Table 1. 3: Age-Specific Incidence Rate (AIR) for Thyroid Nodule in Hail Region, 2015

| Age Factor | Population | | | | | |
|------------|------------|------------|-----------|------------|-----------|------------|
| | Male | | Female | | Children | |
| | Frequency | Percentage | Frequency | Percentage | Frequency | Percentage |
| 0-10 | 1 | 0.6% | 1 | 0.6% | 2 | 1.2% |
| 11-20 | 1 | 0.6% | 18 | 10.7% | | |
| 21-40 | 13 | 7.7% | 81 | 48.2% | | |
| 41-60 | 4 | 2.3% | 37 | 22% | | |
| 60 + | | | 10 | 5.9% | | |
| Total | 19 | | 147 | | 2 | |
| Total | 168 | | | | | |

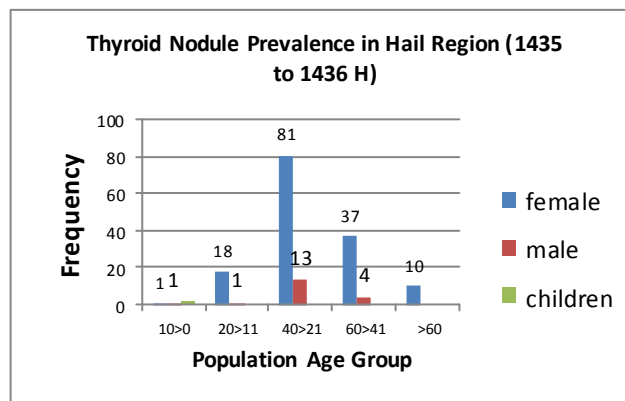
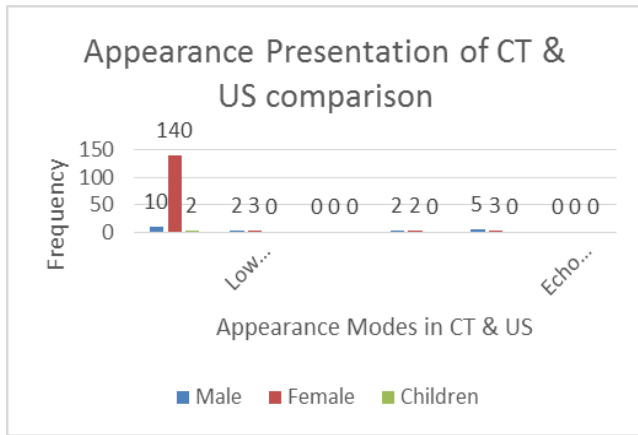


Figure 1.3: The thyroid nodule incidence among age group (KKH)

Table 2.3: The Comparison between the Appearance of Thyroid Nodule ultrasonography and computed tomography tomogram (KKH 2015)

| Frequency | Computed Tomography | | Ultrasound | | | |
|-----------|---------------------|----------------|------------|-------------|-----------|-----------|
| | Brightness | Low brightness | Hypoechoic | Hyperechoic | Isoechoic | Echo free |
| Male | 10 | 2 | 0 | 2 | 5 | 0 |
| Female | 140 | 3 | 0 | 2 | 3 | 0 |
| Children | 2 | 0 | 0 | 0 | 0 | 0 |



Data obtained in previous studies using a thyroid nodule incidence rate, and the comparison appearance of thyroid nodules in CT and US, indicated that the characteristics of each modalities had its impact on the diagnosis. According to Saudi cancer registry (2009) the thyroid nodule occurs among female with 8.6% comparing to male 7.8%⁽¹⁰⁾. In this study, the data were collected using PACS system and interview. The modeled results were compared with a previous result at a fix rate. Figure 3 shows the results obtained using PACS the heist incidence in male was 7.7%, and female 48.2% ranging age (21-40 years) respectively.

As can be seen, in a figure 4, the graph represented that the majority of patients collected were in CT with the peak incidence in a female number was 140 (83.3%) patients and the rest of used US, and male with (10) 5.9% only the rest had the US. Nevertheless, these results suggest that data obtained using CT and US appearance in thyroid nodules may provide more sensitive information for assessing the physicians and technologists to choose the best modalities depending upon the diagnosis characteristics.

4. Discussions

Previous studies documented the effectiveness of CT and US appearance intervention in improving the treatment quality and reducing unnecessary radiation to patient as well as personals. However, these studies have either been not focused on which modality is used and why? In this study we tested the pack incidence rate of thyroid nodule among age group of patients being exposed to two modalities male and female sometimes children. This study found that all cases of thyroid nodules was associated with the characteristics of both modalities CT and US. These finding extend those of Saudi cancer registry, conforming that the female incidence is higher with 8.6% than male to 7.8%. There are a sign of hyperthyroidism in female with 83.3% and 5.9% in male respectively in a CT appearance in Hail region as a method of detection. Furthermore, the CT tomograms show brightness which reflects the presence of iodine substance in the thyroid tissues, and lack of it will show low brightness in the tissue; that may lead to different diseases; according to Rachelet al (2009) Computed tomography is not very sensitive for histopathological invasion.

In an Ultrasonography appearance of thyroid nodule, were 1.1% hyperechoic for both male and female respectively.

While in isoechoic there are 2.9% inmale, and 1.7% in female respectively. Meanwhile there is no sign of cancer because in the sample no one present hypoechoic.

This study therefore indicates that the benefits gained from the choice of modalities in the diagnosis and treatment for the sake of patient and protection of personals. However, some limitations are worth nothing although our hypothesis were supported statistically, the sample was reassessed in both modalities especially in low brightness appearance in CT. Future work should therefore include follow-up work designed to evaluate the low brightness of thyroid nodule in CT appearance.

5. Conclusions

This study concluded that, the thyroid nodules studies in Hail region reach its highest incidence in female (48.2%). The Ultrasonography is preferable in thyroid nodule diagnosis than CT, because it does not expose patients and personals to radiation. In spite of that, CT cannot differentiate well the of thyroid glands soft tissue histopathology.

References

- [1] Mohamed Yousef1, Mohamed Adam, Mustafa Gaafar, Bushra Ahmed, Thyroid Nodules Evaluation with Sonography, International Journal of Science and Research (IJSR), India Online ISSN: 2319-7064
- [2] Haya S. Al-Eid , Angelica D. Garcia , ShoukiBazarbashi , Ali Al-Zahrani Cancer Incidence Report Saudi Arabia 2009, pp: 42
- [3] Ignac Fogelman, Susan E. M. Clarke, Gary Cook, GopinathGnanasegaran, An Atlas of Clinical Nuclear Medicine, Third Edition, 2014 By Taylor & Francis Group, LLC , Pp: 307
- [4] Deitz K, Gilmour L, Wilke V, Riedesel E, Computed tomographic appearance of canine thyroid tumours, J Small AnimPract. 2014 Jun; 55 (6):323-9. 2014 Apr 7.
- [5] www.thyroid.org
- [6] http://radiopaedia.org/articles/assessment-of-thyroid-lesions
- [7] www.iarc.fr. Cancer Research UK 2014
- [8] http://www.cancer.org/cancer/thyroidcancer/detailedguide/thyroid-cancer-diagnosis
- [9] http://www.researchgate.net/publication/5346887_Computed_tomography_and_magnetic_resonance_imaging_in_diseases_of_the_thyroid_and_parathyroid
- [10] Rachel Desaillood , Didier Hober, Viruses and thyroiditis: an update, Virology Journal 2009, vol6:pp: 5