

Four-Year Follow-Up of the Healing Process in Periapical Lesions - A Conservative Approach in Two Cases

Gusiyska A.

Department of Conservative Dentistry, Faculty of Dental Medicine, Medical University-Sofia, Bulgaria

Abstract: *One of the basic principles of endodontic treatment of teeth with chronic periapical lesions is to achieve a three-dimensional obturation of the root canal space, with accentuated attention to the obturation of the apical third. The achievement of maximum sealing of the apical zone is much more predictable in the presence of an apical constriction and the possibility of preparing an apical stop and not to overfill. The effect of overfilling is varied, determined by the type of sealer and the sealer's quantity which passes through the apical foramen. Based on these factors, the most common effects of overfilling are inflammation reaction of the tissue in the apical zone causing severe pain accompanied by swollen tissue, periodontal ligament breakage, and periapical lesion persistence.*

Keywords: conservative treatment, granuloma, healing process, inflammation, periapical lesion

1. Introduction

The initiation of apical periodontitis emerges from a pulpal inflammation that exceeds to a necrotic pulp which gives the opportunity for bacteria from the oral environment to enter the pulp chamber and the root canal. This colonization inside the tooth results in a leakage of bacterial products, toxins and bacteria's through the apical foramen causing an inflammatory reaction in the periapical area [9,25,30,32,35,39].

The dynamic collision between microorganisms and the macroorganism in the zone of infected radicular pulp tissue and periodontal ligament is defined as local inflammation. The typical signs of hard tissue resorption or destruction of the periapical tissues and finally formation of lesions in various histopathological stages of the development of chronic apical periodontitis (CAP), commonly referred to as periapical lesion [11, 38]. Most periapical lesions (>90%) can be classified as dental granulomas, radicular cysts or abscesses [2]. It is generally accepted that periapical lesions cannot be differentially diagnosed as either radicular cysts or apical granuloma based on radiographic evidence alone [5, 7, 22, 26, 34].

The healing processes in this region can be separated into regeneration and repair. Regeneration results in the complete restitution of lost or damaged tissue, while repair involves restoration of some of the original structures [24].

Processes of repair and regeneration of periapical tissues after conservative or surgical treatment follow the general principles typical of tissue repair. At the same time, there are some specifics since in this zone there are different by its nature tissues that are characterized by different processes [20, 36, 41].

Various materials for sealing the root canal system and apical barrier have been used in endodontic treatment. The choice of a material could be governed by handling properties, biocompatibility, apical seal and long-term

clinical success. Some clinical studies have confirmed that simple non-surgical treatment with proper infection control can promote healing of large periapical lesions [9,16, 18, 19, 27, 28, 40].

2. Case Report 1

A 49-year old woman was referred complaining of repeated swelling and pain in the anterior maxilla over the last few months. Clinical examination revealed that left maxillary lateral incisor (tooth 22) were tender to percussion and palpation. The patient reported that the lateral incisor has undergone apical surgery 9 years ago. The diagnostic radiograph revealed that tooth 22 had an unsatisfactory root canal obturation and radiolucency in the periapical region. Despite the advanced horizontal bone resorption and apical surgery the tooth had a minimum degree of mobility. So the treatment plan was to re-treat the tooth orthograde and wait for 6 months for definitive crown. Following rubber dam isolation the outline of the access cavity in the lateral incisor was modified. The root canal walls were prepared using ProTaper Universal rotary files (Dentsply Maillefer, Ballaigues, Switzerland) till F5 finishing file and irrigated passively with 5.25% NaOCl and 17% EDTA. Intracanal medication- Ca(OH)₂ - was used for 10 days because of resorptive processes in the periapical area. After that period of time the root canal was definitively obturated using apical barrier, sealer and gutta-percha due to the wide open apex after surgery [16, 17]. Due to satisfactory healing processes in the periapical area six months later a restoration with FRC post and a crown was done. Satisfactory results were obtained also after 4 years. There was no increased tooth mobility of the initial situation (Figure 1. a-f).

3. Case Report 2

A 32-year old man was referred complaining of non-satisfactory appearance of the crown of the left central incisor. The diagnostic radiographic examination shows a large periapical lesion according to periapical index - PAI5. Upon chemo-mechanical preparation of the root canal space

it was filed with Ca(OH)_2 for 10 days. The root canal was definitively obturated using apical barrier of calcium phosphate bioceramic in order to improve both, clinical and radiographic outcome.

This apical barrier initiated regeneration processes in the periapical area and created conditions for maximum sealing of the root canal and eliminated overfilling within the zone. The calcium phosphate bioceramic has the capacity to stop bleeding after application in the periapical zone and gives its antimicrobial effect (Figure 2. a-f).

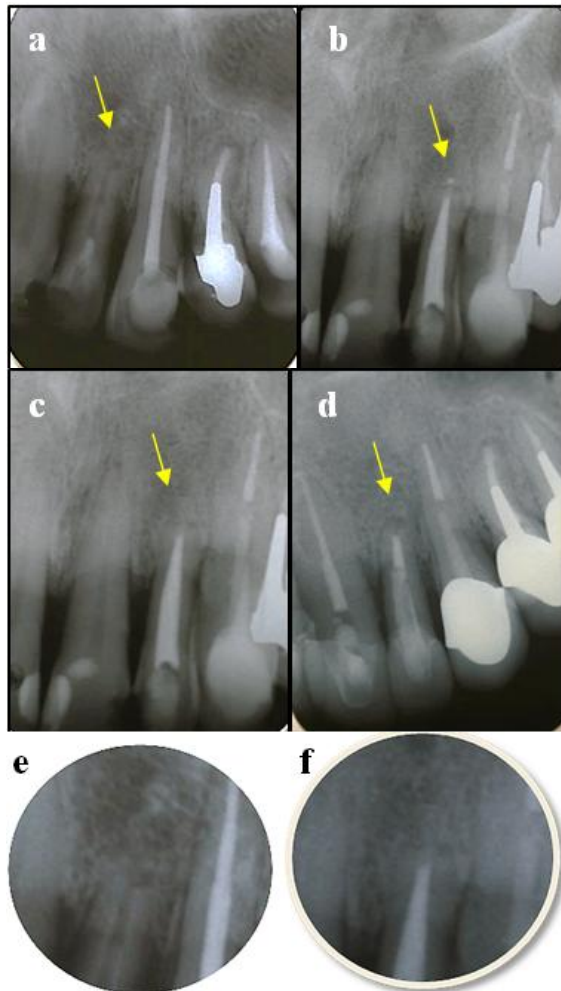


Figure 1: a/initial x-ray presents the periapical condition of tooth 22 after apical surgery 9 years ago; b/control x-ray after obturation using biphasic calcium phosphate ceramic as a apical barrier and AH Plus as a sealer and gutta-percha; c/control x-ray at 6th month; d/control x-ray after FRC post placement e/ zoom at initial clinical situation; f/zoom at 4th year after definitive obturation.

4. Discussion

The basis for success of endodontic treatment is to remove the cause, i.e. all necrotic debris, bacteria and their byproducts. As early as in 1939, it was known that the root canal was the seat of infection [6, 10]. After debridement and disinfection of root canals, periradicular lesion had healed even without obturation of root canal [23]. Research suggests that the high pH and released calcium ions are required for the materials, which should stimulate

mineralization in the process of hard tissue healing in teeth with CAP.

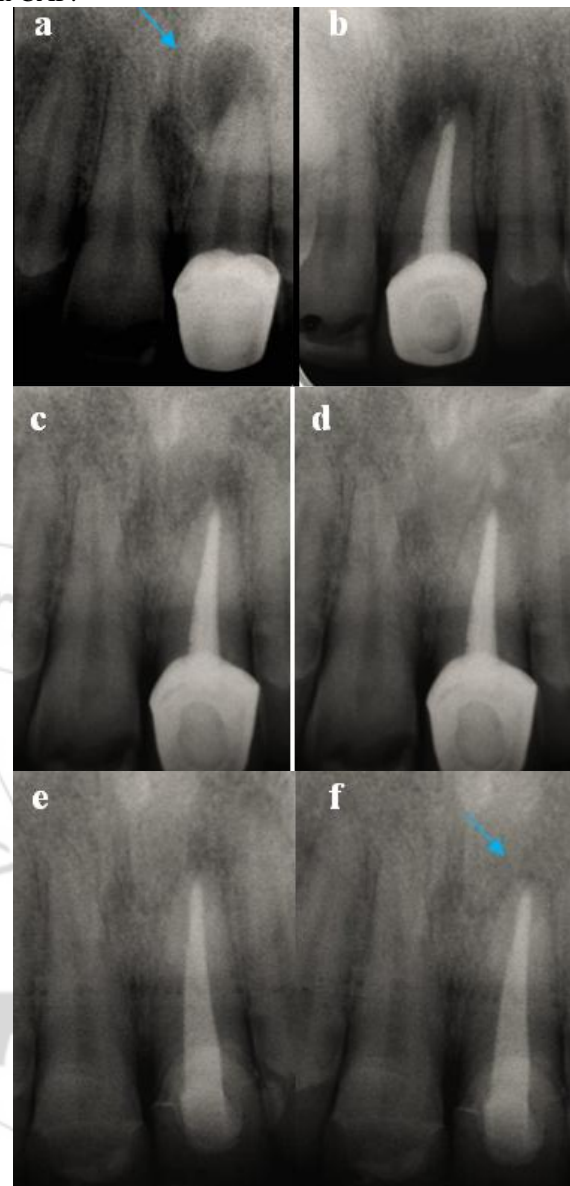


Figure 2: a/initial x-ray presents the periapical condition of tooth 21 indicated for primary endodontic treatment; b/definitive obturation of root canal using apical barrier from biphasic calcium phosphate ceramic and after that sealer and gutta-percha; c/control x-ray at the 3rd month; d/control x-ray at the 6th month and after that the old metal-ceramic crown were replaced with new one; e/x-ray after 1 year; f/x-ray after 4 years.

The effect of overfilling is varied, determined by the type of sealer and sealer's quantity which passes through the apical foramen. Based on these factors, the most common effects of overfilling are inflammation reaction of the tissue in apical zone causing severe pain accompanied by swollen tissue, periodontal ligament breakage, and periapical lesion persistence [15, 31, 42, 21]. It is documented that in cases of apical periodontitis, intra-canal bacteria can penetrate dentin to a depth of 150-250 μ , where they remain protected from the action of medicament and irrigants [4, 22]. Therefore, apical canal widening to 300-500 μ is required to thoroughly cleanse the apical portion of the canal. Apical foramen widening was done with gradually increasing number of

files till #025 or #030. This allowed thorough cleaning of cemental part of the canal and also ensured subsequent smooth passage of instrument taken past the foramen without breakage [37]. When healing process starts the amount of inflammatory mediators, metalloproteinases, and growth factors released by immune cells is substantially reduced in the lesion.

Apical clearing, apical foramen widening and over-instrumentation into the periapical region were done to induce bleeding near the apical foramen. It is assumed that the clot formed provides a scaffold into which locally residing stem cells can get seeded and the cascade of healing process can initiate [37].

The periapical tissues have a rich blood supply, lymphatic drainage and abundant undifferentiated cells. The periapical region of teeth is rich in various stem cells such as - periodontal ligament stem cells, dental pulp stem cells, bone marrow mesenchymal stem cells and the more recently identified stem cells from apical papilla [14]. These stem cells are documented to play a significant role in maturation processes of immature teeth using revascularization procedure [14]. Shah (2012) wrote, that it could be hypothesized that the same mechanism probably takes place in cases of mature teeth. The bleeding and clot formed in the area of apical foramen by over-instrumentation can lead to seeding of stem cells, their proliferation, differentiation and mineralized tissue formation, sealing the apical foramen [37]. Bhaskar suggested that if instruments are extended 1 mm beyond the apical foramen, the inflammatory reaction that develops destroys the cyst lining and converts the lesion into a granuloma. Once the causative factors are eliminated, the granuloma heals spontaneously [3]. Bender added that penetration to the center of the apical lesion might help in resolution by establishing the drainage and relieving pressure [1].

According to the latest data, removal of the smear layer is an essential of root canal disinfection and sealing. Contrary to the vulnerable planktonic state, bacteria are protected from the antibacterial agent in biofilms. To date, many methods and antibacterial agents have been proposed against biofilms and are effective within a wide range of activity [29, 13, 33].

Endodontic pathogens have different survival strategies when the conditions are unfavorable. The microbes penetrate the dentinal tubules in 1000 µm depth, creating a firmly bonded biofilm. The use of red light is giving good results in photoactivated disinfection of the root canals as a new method of treatment. The latest results in this area demonstrate the need for further research associated with bacterial pathogens for achieving the best results possible.

5. Conclusion

After the endodontic infection is effectively eliminated by nonsurgical orthograde treatment, inflammation of the periapical lesion gradually subsides, and the healing process is initiated. The biomimetical obturation of dental apex and overfilling of the apical periodontal lesion with calcium phosphate bioceramic, stimulate the remodeling healing processes in the periodontal zone. Most probably the

effective orthograde treatment and the application of bioceramic stimulate the reduction of the amount of inflammatory mediators, metalloproteinases, and the growth factors released by the immune cells in the lesion.

References

- [1] Bender I. A commentary on General Bhaskar's hypothesis. *Oral Surg Oral Med Oral Pathol* 1972; 34: 469–76.
- [2] Bhaskar S. Periapical lesion-types, incidence and clinical features. *Oral Surg Oral Med Oral Pathol* 1966; 21: 657–71.
- [3] Bhaskar S. Nonsurgical resolution of radicular cysts. *Oral Surg Oral Med Oral Pathol* 1972; 34: 458–68.
- [4] Borlina S, de Souza V, Holland R, Murata S, Gomes-Filho J, Dezan E, Junior, et al. Influence of apical foramen widening and sealer on the healing of chronic periapical lesions induced in dogs' teeth. *Oral Surg Oral Med Oral Pathol Radiol Endod.* 2010; 109:932–40.
- [5] Caliskan M. Prognosis of large cyst-like periapical lesions following nonsurgical root canal treatment. *Int Endod J* 2004; 37: 408–16.
- [6] Estrela, C. *Endodontic Science*. – Editoria Artes Medicas Ltda, SP, Brazil, 2009, Vol. 1, 25–48.
- [7] Fernandes M, De Ataide I. Non-surgical management of a large periapical lesion using a simple aspiration technique: a case report. *Int. Endod. J.*, 2010, 43, 536–542.
- [8] Filipov I, Markova K, Boyadzhieva E. Efficacy of photoactivated disinfection on experimental biofilm - scanning electron microscopy results. *IMAB* 2013;19(4):383-387.
- [9] Friedman S, Mor C. The success of endodontic therapy – healing and functionality. – *J. Can. Dent. Assoc.*, 2004, 32, 493–503.
- [10] Fish. Bone infections. *J Amer J Dent Assoc.* 1939;26:691.
- [11] García, C. et al. The post-endodontic periapical lesion: Histologic and etiopathogenic aspects. *Med Oral Patol Oral Cir Bucal* 2007, 12(8):E585–90.
- [12] Georgieva Cv, Dimitrov Sl, Dogandjiiska V. Photodynamic therapy – nature and action mechanisms *Dental Medicine*. 2008; 92(2):140-147. [inBulgarian]
- [13] Gorni F, Gagliani M. The outcome of endodontic retreatment: a 2-yr follow-up. *J Endod* 2004, 30(1): 1–4.
- [14] Gronthos S, Mankani M, Brahimi J, Robey P, Shi S. Postnatal human dental pulp stem cells (DPSCs) in vitro and in vivo. *Proc Natl Acad Sci U S A.* 2000;7:13625–30.
- [15] Grossman L, Oliet S, Del Río C. *Endodontic practice*. 11th ed. Philadelphia: Lea and Febiger; 1988. p. 179.
- [16] Gusiyska A, Dylgerova E. Remodeling of periapical lesions scaffolding by biphasic calcium phosphate ceramics – A pilot study, *Journal of IMAB*, Volume 15, Book 2, 2009, p.113-118.
- [17] Gusiyska A, Ilieva R. Nanosize Biphasic Calcium Phosphate used for Treatment of Periapical Lesions. *International Journal of Current Research* 2015;7(1): 11564-11567.
- [18] Gusiyska A, Ilieva R, Dylgerova E. Nanosize bi-phase calcium phosphate ceramics and treatment strategy for

- regeneration in endodontic periapical lesions – case report and review. Proceedings of the 12th Workshops “Nanoscience& Nanotechnology”, Nov. 26-28, 2010, Varna, edited by E.Balabanova&I.Dragieva, 2011, BAS-NCCNT, 211-213.
- [19] Haapasalo M, Udnaes T, Endal U. Persistent, recurrent, and acquired infection of the root canal system post-treatment. *Endod Topics* 2003; 6: 29–56.
- [20] Holland G. Periapical innervation of the ferret canine one year after pulpectomy. *J Dent Res* 1992;71:470-474.
- [21] Hoskinson S, Ng Y, Hoskinson A, Moles D, Gulabivala K. A retrospective comparison of outcome of root canal treatment using two different protocols. – *Oral Surg Oral Med Oral Pathol Oral Radiol Endod* 2002; 93: 705–715.
- [22] Ingle J, Bakland L. *Endodontics*. 6th edn. 2007, PMPH USA.
- [23] Ingle J, Bakland L, Baumgartner J. *Endodontics*. 6 ed. Ontario: B C Decker Inc; 2008. p. 922
- [24] Kumar V. et al. Robbins and Cotran pathologic basis of disease. 8th ed. Philadelphia: Sanders/Elsevier, 2010.
- [25] Lana M, Ribeiro-Sobrinho A, Stehling R. et al. Microorganisms isolated from root canals presenting necrotic pulp and their drug susceptibility in vitro. *Oral Microbiol Immunol* 2001; 16: 100–105.
- [26] Lalonde E. A new rationale for the management of periapical granulomas and cysts. *J Endod* 1970; 80: 1056–9.
- [27] Leonardo M, Silveria F, Silva L, TanomaruFilho M, Utrilla L. Calcium hydroxide root canal dressing. Histopathological evaluation of periapical repair at different time periods. *Braz Dent J* 2002; 13: 17–22.
- [28] Marques, M. D., B. Moreira, H. M. Eriksen. Prevalence of apical periodontitis and results of endodontic treatment in an adult Portuguese population. *Int Endod J* 1998; 31: 161–5.
- [29] Mohammadi Z, Soltani M, Shalavi S. An Update on the Management of Endodontic Biofilms Using Root Canal Irrigants and Medicaments. *Iran Endod J* 2014;9(2):89-97.
- [30] Molander A, Reit C, Dahlén G, Kvist T. Microbiological status of root filled teeth with apical periodontitis. *Int Endod J* 1998; 31: 1–7.
- [31] Neaverth E. Disabling complications following inadvertent overextension of a root canal filling material. *J Endod* 1989; 15(3):135-9.
- [32] Nair P, Sjogren U, Krey G, Kahnberg E, Sundqvist G. Intraradicular bacteria and fungi in rootfilled, asymptomatic human teeth with therapy-resistant periapical lesions: A long-term light and electron microscopic follow-up study. *J Endod* 1990;16:580-8.
- [33] Nair P, Sjögren U, Krey G, Kahnberg E, Sundqvist G. Intraradicular bacteria and fungi in root filled asymptomatic human teeth with therapy resistant periapical lesions: a long term light and electron microscope follow-up study. – *J. Endod.*, 1990, 16, 580–588.
- [34] Nair P. Apical periodontitis: a dynamic encounter between root canal infection and host response. *Periodontol* 2000; 13: 121–148.
- [35] Sen B, Piskin B, Demirci T. Observation of bacteria and fungi in infected root canals and dentinal tubules by SEM. *Endod Dent Traumatol* 1995;11:6-9.
- [36] Siqueira J, Rôças I. Clinical implications and microbiology of bacterial persistence after treatment procedure. *J Endod* 2008; 34:1291-1301/ e1293.
- [37] Shah N, Logani A. Seal Bio: A novel, non-obturation endodontic treatment based on concept of regeneration. *J Conserv Dent*. 2012; 15(4): 328–332.
- [38] Soares J. et al. Favorable response of an extensive periapical lesion to root canal treatment. *J. Oral Sci.*, 2008 Mar; 50 (1), 107–11.
- [39] Tronstad L, Barnett F, Cervone F. Periapical bacterial plaque in teeth refractory to endodontic treatment. *Endod Dent Traumatol* 1990;6:73-7.
- [40] Weiger R, Rosendahl R, Löst C. Influence of calcium hydroxide intracanal dressings on the prognosis of teeth with endodontically induced periapical lesions. *Int Endod J* 2000; 33: 219–26.
- [41] Wu M, et al. Consequences of and strategies to deal with residual post-treatment root canal infection. *Int Endod J* 2006; 39: 343-356.
- [42] Yaltirik M, Berberoglu HK, Koray M, Dulger O, Yildirim S, AydilBA. Orbital pain and headache secondary to overfilling of a root canal. *J Endod* 2003; 29(11):771-2.