

Post Operative Functional Outcomes in Patients After Titanium Mesh Cage in Thoracic Spine

Mohammad Kamran Ayoob¹, Hafiz Muhammad Asim², Zahid Mehmood Bhatti³

Lecturer, Lahore College of Physical Therapy, Lahore Medical & Dental College, Department of Physical Therapy, Canal Bank Road, Lahore

Associate Professor/ Lahore College of Physical Therapy, Lahore Medical & Dental College, Canal Bank Road, Lahore

Assistant Professor, Lahore College of Physical Therapy, Lahore Medical & Dental College, Department of Physical Therapy, Canal Bank Road, Lahore

Abstract: *The objective of study was to describe the functional outcome after TMC application in Thoracic spine within one year postoperatively. This case series study comprised 62 patients surgically treated with TMC in Thoracic spine from January, 2011 to December, 2012 in Ghurki Trust Teaching Hospital. All patients fulfilling the criteria for study was include. Written consent forms, demographic information, detailed history, clinical examination used to assess for functional outcomes and muscle strengthening by using barthel index score, bed mobility profile and manual muscle testing. The findings of this study indicate that after TMC application in thoracic spine there is progress from dependency to independent life. TMC is a safe and effective device in restoring functional activities without recurrence of any complication.*

Keywords: Titanium Mesh Cage(TMC), Thoracic spine, Functional outcome, Barthel index score, Bed mobility profile.

1. Introduction

The use of cages for stabilization procedures in the spine takes its origin from the work of Bagby, who developed a stainless-steel basket, which could be packed with cancellous bone in order to stabilize the necks of horses with Wobbler Syndrome (a form of cervical myelopathy seen in race horses). Better results were achieved than with the Cloward technique.(1). The application of Titanium Mesh Cages(TMC) for spinal stability and fusion opened new technique in spine surgery. A range of equipment are accessible for thoracic spine stability and reconstruction; Titanium Mesh Cages, pedicle screw and flaps have been publicized in terms of promoting fusion provide excellent structural support (2).

The anterior column of spine represent typical use of cylindrical TMC for replacement and support(3) TMC has consistently better results for large anterior spinal column fracture or defect reconstructions(4).

1.1 Indications for TMC placement

- 1) Tuberculosis of spine
- 2) Infection
- 3) Tumor
- 4) Trauma
- 5) Degenerative disease
- 6) Fracture Vertebrae
- 7) Osteoporosis
- 8) Deformity correction (scoliosis, kyphosis)
- 9) Miscellaneous conditions etc. (5)

Patient presents with a mixture of symptoms including pain, sensory changes (including parenthesis, dysaesthesia), motor deficits, and loss in bowel and bladder control. Pain is the most frequent symptom. It may be localized to the spine or radiates. Nocturnal pain is also representative of pain in

thoracic spine. Unlike pleuritic or musculoskeletal pain, with deep inspiration. Motor examination may show a paraparesis or monoparesis with support spasticity in lower limb and sensory disorder.(6)

The ability to accurately predict the magnitude of neuro-recovery and expected functional outcomes following spinal cord injury is of great importance.(7).Clinically relevant functional outcome after Spinal Cord Injury is related to the degree to which functional organization within the central nervous system is disrupted.(8)

Consistent Functional outcomes offer a general frame which help to assess the achievement of physiotherapy interventions, thus give source for comparing outcomes interrelated to dissimilar intervention approaches. Observing functional outcomes surrounded by the related components of function, together with body movements and mechanics, range of motion, and involvement, with patients with the identical diagnosis, is the base for shaping which intervention approaches consist of best clinical results.

1.2 Objectives

To describe the functional outcome after TMC application in Thoracic spine within one year postoperatively.

1.3 Rationale

The current research enabled us to assess the effectiveness of TMC surgery in terms of functional abilities of patients including ADL's and IADL's.

1.4 Operational Definitions

1.4.1 Assessment of Functional Outcome

Functional Outcome is measured by using The Barthel ADL index or Barthel scale, **Bed Mobility Profile** and **Manual Muscle Testing**.

1.4.2 Barthel scale or Barthel ADL index

Barthel scale is an ordinal scale used to assess performance in daily life activities (ADL). Ten variables are used to ten variables to relating mobility and ADL. Item scores are gather to present a total score ranging from 0 to 100 (0: complete dependent; 100: complete independent). (9)

1.4.3 Bed Mobility Profile

Bed Mobility Score provides base to count the independence in mobility of transferring from bed, the capability to go up in and out of a chair and bed. it is a common problem in elders, mainly those residing in expert nursing services. Total score of Bed Mobility Profile is counted out 77 in which eleven bed mobility activities are observed.

1.4.4 Manual Muscle Strength Testing

Manual Muscle testing will be used to measure the strengths of lower limb muscles. (10) Muscles group which are in the range of grade 1-2 is included. e.g flickering. Grade 3 muscle strength is categories as gravity free. e.g. Straight Leg Raise. Muscles group works against gravity and with resistant are included, Grade 4-5. e.g. Knee extension with weight.

1.5 Methodology

1.5.1 Sample Selection

An institutional database of Ghurki Trust Teaching Hospital was explored to discover all patients who undergo Titanium Mesh Cage in thoracic spine between January, 2011 to December, 2012

1.5.2 Sample Size

62 patients participates in study.

1.5.3 Setting

Ghurki Trust Teaching Hospital, Lahore

1.5.4 Duration of Study

Study will be completed within 4 month period from November 2013 to February 2014.

1.5.5 Study Design

Case series.

1.5.6 Inclusive Criteria

- Patients from all the age group will be selected.
- Patients underwent thoracic cage application at Ghurki Trust Teaching Hospital between January, 2011 to December, 2012
- Both genders

1.5.7 Exclusive Criteria

- Patient with multiple surgery.
- Patient with bullet injury.

- Application of Cage in cervical or lumbar region.

1.5.8 Data Collection

An institutional database of Ghurki Trust Teaching Hospital was explored to discover all patients who undergo Titanium Mesh Cage in thoracic spine between January, 2011 to December, 2012. All patients fulfilling the criteria for study is include. Written consent forms, demographic information and detailed history was taken and clinical examination is performed (if patient is available).

1.5.9 Data Analysis

The data was entered and analyzed by Statistical Package for Social Sciences (SPSS) version 21. Numeric data like Barthel score, Manual muscle testing score and bed mobility profile score were presented as mean \pm SD and qualitative data like gender, Bed profile grouping and Barthel index grouping were presented as frequency and percentage. Wilcoxon signed-rank test was applied for comparing two related samples. Significance for statistical tests was accepted at ≤ 0.05 level of probability.

2. Results

The current research enabled us to assess the effectiveness of TMC surgery in terms of functional abilities of patients including ADL's and IADL's. In this study, Mean age of the patients was 39 ± 19.54 . there were 34 (54.84%) males and 28 (45.16%) female patients. Males mean age was 44.71 ± 19.58 and females age average age was 32.07 ± 17.52 .

Cage implantation is done on each segment of thoracic spine. In our study, Majority of patient have cage implant at the T6-T11 level of Thoracic spine.

2.1 Barhtel Index Score

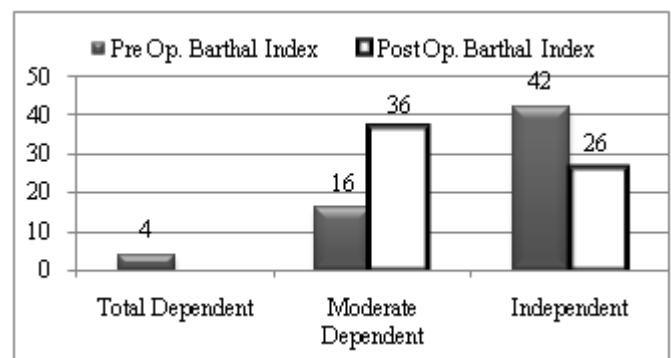


Figure 1: Pre and Post Op Barthel Index Score.

Above graph shows that there is improvement in barthel index score post op., majority of patient is lie in moderate dependent group.

2.2 Bed Mobility Profile

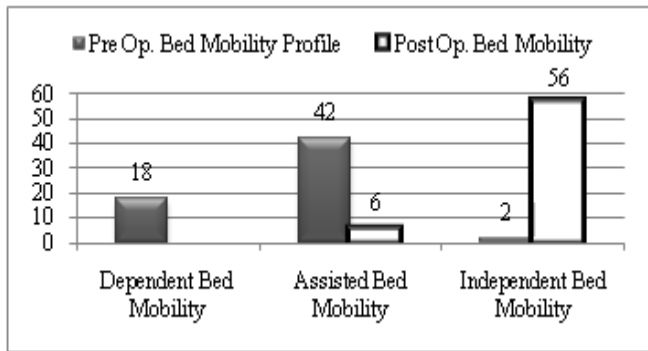


Figure 2: Pre and Post Op Bed Mobility Profile.

There is increase in bed mobility score after post op.; 56 patients lie in independent Bed Mobility profile group as shown in graph.

2.3 Wilcoxon rank sum test

Table 1

	n	Mean	Wilcoxon rank sum test	p-value
Pre Op. Manual Muscle Testing	62	50±20.804	6.827	<0.001
Post Op. Manual Muscle Testing	62	78.13±11.712		
Pre Op. Bed Mobility Profile	62	28.13±13.288	6.849	<0.001
Post Op. Bed Mobility Profile	62	63.29±8.350		
Pre Op. Barthel Index	62	58.48±17.726	6.349	<0.001
Post Op. Barthel Index	62	84.19±10.732		

There was mean difference of 28.129 between Pre and Post Op Manual Muscle Testing. The difference was statistically significant different (p-value <0.001). There was mean difference of 35.16 between Pre and Post Op bed Mobility Profile. The difference was statistically significant different (p-value <0.001). Mean of Pre Op bed mobility profile is 28.13. Mean of Post Op bed mobility profile is 63.29. Shows increase in bed mobility score after TMC application in thoracic spine. Similarly, there was mean difference of 25.71 between Pre and Post Operative Barthel index score. The difference was statistically significant different (p-value <0.001).

3. Conclusion

After TMC application in thoracic spine there is improvement in the muscle strengthening with time. Mean difference of 35.16 between Pre and Post Op bed Mobility Profile. There is increase in patients ability to rise in and out of a bed and chair.

Increase barthel index score in Post Op. Patient, independence from any help to perform their daily activities independently. There is significant difference between Pre & Post Operative Barthel Index Score. After TMC application in thoracic spine there is progress from dependency to independent life. TMC is a safe and effective device in restoring functional activities without recurrence of any complication. TMC is the ideal treatment in cases of

spinal anterior instability due to its related excellent functional outcomes.

References

- [1] Cloward RB. Vertebral body fusion for ruptured cervical discs. American journal of surgery. 1959 Nov;98:722-7. PubMed PMID: 13810740. Epub 1959/11/01. eng.
- [2] O'Shaughnessy BA, Ondra SL, Ganju A, Said HK, Few JW, Liu JC. Anterior thoracic spine reconstruction using a titanium mesh cage and pedicled rib flap. Spine. 2006 Jul 15;31(16):1820-7. PubMed PMID: 16845358. Epub 2006/07/18. eng.
- [3] Grob D, Daehn S, Mannion AF. Titanium mesh cages (TMC) in spine surgery. European spine journal : official publication of the European Spine Society, the European Spinal Deformity Society, and the European Section of the Cervical Spine Research Society. 2005 Apr;14(3):211-21. PubMed PMID: 15340827. Pubmed Central PMCID: PMC3476740. Epub 2004/09/02. eng.
- [4] Fayazi AH, Ludwig SC, Dabbah M, Bryan Butler R, Gelb DE. Preliminary results of staged anterior debridement and reconstruction using titanium mesh cages in the treatment of thoracolumbar vertebral osteomyelitis. The spine journal : official journal of the North American Spine Society. 2004 Jul-Aug;4(4):388-95. PubMed PMID: 15246297. Epub 2004/07/13. eng.
- [5] Sheeraz A. Qureshi MNC, and Andrew C. Hecht. Anterior Thoracic Corpectomy. In: Operative Techniques in Orthopaedic Surgery [Internet]. Wolters Kluwer. 1st edition.
- [6] Patel N. SURGICAL DISORDERS OF THE THORACIC AND LUMBAR SPINE: A GUIDE FOR NEUROLOGISTS. J Neurol Neurosurg Psychiatry 2002. 2002;73(suppl 1). Pubmed Central PMCID: PMC1765594.
- [7] Burns AS, Ditunno JF. Establishing prognosis and maximizing functional outcomes after spinal cord injury: a review of current and future directions in rehabilitation management. Spine. 2001 Dec 15;26(24 Suppl):S137-45. PubMed PMID: 11805621. Epub 2002/01/24. eng.
- [8] Ovechkin AV, Vitaz TW, Terson de Paleville DG, McKay WB. Quality of residual neuromuscular control and functional deficits in patients with spinal cord injury. Frontiers in neurology. 2013;4:174. PubMed PMID: 24223568. Pubmed Central PMCID: PMC3819596. Epub 2013/11/14. eng.
- [9] Hsieh Y-W, Wang C-H, Wu S-C, Chen P-C, Sheu C-F, Hsieh C-L. Establishing the minimal clinically important difference of the Barthel Index in stroke patients. Neurorehabilitation and neural repair. 2007;21(3):233-8.
- [10] Hislop H, Montgomery J. Daniels and Worthingham's Muscle testing. Techniques of manual examination. 2002:208-15.