

# A Case Report of Posner Schlossman Syndrome

Dr Rajiv Kumar Das<sup>1</sup>, Dr (Mrs.) B. Devi<sup>2</sup>

<sup>1</sup>Refractionist, Department of Ophthalmology, Assam Medical College & Hospital, Dibrugarh-786002

<sup>2</sup>Professor, Department of Ophthalmology, Assam Medical College & Hospital, Dibrugarh-786002

**Abstract:** A 43 year old male presented to the emergency room of Assam Medical College & Hospital, Dibrugarh, with the chief complains of vision of right eye with redness, fogginess of vision, pain and vomiting. There was corneal edema with mild ciliary congestion and sluggishly reacting mid dilated pupil. The optic disc was normal. The intra ocular tension was found 56 mmHg but diurnal variation was less than 8 mmHg. In left eye visual acuity was 6/18 with normal intraocular tension. There was past history of iridectomy in the left eye which were done 15 years back due to similar complaint to the left eye and they were patent superiorly in 12 and 10'clock positions. But gonioscopy found no occludable angle of the anterior chamber, rather they were found wide open. There were neither synachiae nor abnormal vessels seen, except few keratic precipitate cells in the anterior chamber of the right eye. Dark room provocative tests and water drinking test were negative and there was no history of any steroid use in any form. The patient was treated with intravenous mannitol, timolol maleate and prednisolone acetate eye drops. He got relief after two days and subsequent follow ups showed normal intraocular tension. The case was diagnosed as a Posner-Schlossman syndrome. This is a relatively rare uveitic condition as Posner Schlossman syndrome with occasional cells only is a very rare finding.

**Keywords:** Posner Schlossman syndrome, glaucomatocyclitic crisis, few keratic precipitate cells

## 1. Introduction

Posner-Schlossman syndrome or glaucomatocyclitic crisis is a condition with self-limited recurrent episodes of markedly elevated intraocular pressure (IOP) and mild idiopathic anterior chamber inflammation.<sup>4,6</sup> In 1948, Posner and Schlossman first recognized glaucomatocyclitic crisis and described the features of this syndrome<sup>1</sup>. It is seen most commonly between the age group of 20-50 years. Typically, the onset is acute consisting of slight ocular discomfort, blurred vision and seeing colored haloes around lights, characteristically affecting only one eye. Examination reveals epithelial edema and tension usually between 40 and 70 mm. hg. A few K.P.s may be seen. The treatment is cortisone locally and the patient becomes alright within 3-4 days without any diminution of vision and field defects.<sup>3,6</sup> It is a rare condition. The finding of only occasional cells with no flare and no KP in this condition is very rare.

## 2. Case Report

A 43 year old male presented to the emergency room of Assam Medical College & Hospital, Dibrugarh, with the chief complains of diminution of vision of right eye with fogginess and pain for last 2 days along with vomiting.

The diminution of vision of the right eye developed gradually but fogginess had appeared 2 days back. Foggy vision was more in the morning. The pain was acute and throbbing in nature. He also complained of redness in the right eye. He had 3 episodes of vomiting which was projectile in nature and subsided after taking anti emetics though nausea persisted.

He had neither history of diabetes, hypertension nor any other major illness. There was a treatment history of surgical iridectomy of the left eye 20 years back when he was admitted in the hospital with similar kind of symptoms. He had no history of any steroid use. There was no suggestive allergic history found. Family history is of no significance. He was non-vegetarian and non-alcoholic. He lived with his wife and children, each are enjoying good health.

## 3. During Examination

Visual acuity for right eye was 6/36 and for left eye 6/18 by Snellen chart. Lids were normal. There was corneal edema and mild ciliary congestion noted. The pupil was sluggishly reacting to light, round, regular but mid-dilated. Left eye was normal.

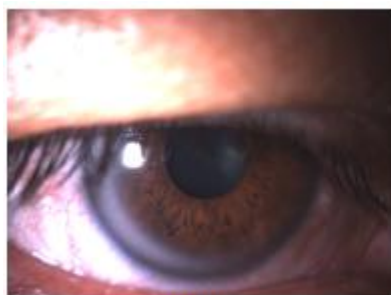

Figure 1: Right eye

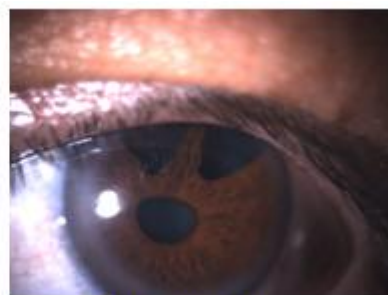

Figure 2: Left eye

Anterior chamber was of normal depth with occasional cells

found in the anterior chamber. Few KP cells are seen.

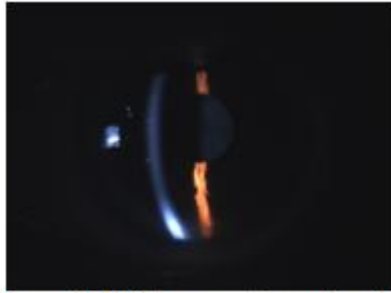


Figure 3: Right eye anterior chamber



Figure 4: Left eye anterior chamber

No exfoliative or pseudoexfoliative material found in the anterior segment. The lens appeared to be normal and clear, capsule was intact. Ophthalmoscopy revealed completely

normal fundus. Optic disc, cup-disc ratio and vessels were normal.




Figure 5: right eye fundus





Figure 6: left eye fundus

The intra ocular tension was 56 mmHg. Intraocular tension was recorded at morning, daytime and evening but diurnal variation was less than 8 mmHg.

**On Gonioscopy:**

No occludable angle of the anterior chamber seen in both the eyes and they were wide open. No K. P.; no pigment and no abnormal vessels or synechia seen.

Left eye, visual acuity was 6/18 and intraocular tension was 12 mmHg. Two patent iridectomy holes were found superiorly in 12 and 10'clock positions.



Water drinking test, dark room provocative test were negative. Automated Perimetry was normal.

TLC : 6000/cc  
 ESR : 8 mmAEFH.q  
**Random Blood Sugar:** 104 mg%.  
**Chest X-ray:** Normal Study

**General examination:** Other systemic examination findings were within normal limit.

**Diagnosis**

The case was diagnosed as a Posner-Schlossman syndrome because of the occasional cells found in the anterior chamber

**Routine Investigation was as follows:**

**R/E Blood :** Hb : 11 gm%

with normal angle, and with all the signs going against the establishment of Primary angle closure glaucoma.

### Treatment

He was treated with intravenous manitol 100 ml stat, Prednisolone acetate eye drop 4 times daily, timolol maleate and dorzolamide eye drop 2 times daily and atropine eye drop 2 times daily in the right eye. The next morning his fogginess and pain in the right eye disappeared. Intraocular tension was found 29 mmHg on day 1 following treatment, which came down to 19 mmHg on the subsequent day. He was on that treatment regime for one month. Steroid eye drop was tapered accordingly.

### Follow up

He was followed up after one month and at 3 month. During follow up his intra ocular tension was within normal limit, visual acuity was 6/9 and there was no ciliary congestion and no cells in the anterior chamber.

## 4. Discussion

There are few case reports of Posner Schlossman syndrome with occasional cells. In a case report by Harstad HK et al<sup>1</sup> showed numerous mononuclear cells in the trabecular interspaces. The hypertensive attacks were supposed more to be due to blockage of the aqueous outflow pathway by these cells, and less to increased aqueous formation.<sup>1</sup>

In another case report by In-Hei Hahn et al<sup>2</sup> showed that the diagnosis was easily missed due to nonspecific findings in the anterior chamber<sup>2</sup>. The study typically revealed a noninjected, slightly mydriatic eye. Slit-lamp examination might reveal fewer-than-expected inflammatory cells in the anterior chamber, with only occasional small nonpigmented keratic precipitates on the corneal epithelium. The intraocular pressure was typically increased (30 to 70 mmHg), despite an open angle.

In a case report by Narang SK, Shah et al<sup>3</sup> gave opinions that rise of tension should not give rise to such an inflammatory reaction as to have keratic precipitates. The basic process was probably the inflammation of the ciliary body and trabecular meshwork which may be minimal and rise of tension was secondary to it.<sup>3</sup>

## 5. Conclusion

This is a relatively rare uveitic condition as Posner Schlossman syndrome with occasional cells only is a very rare finding. The disease well responds to medical treatment.<sup>1</sup>

## References

- [1] Adlph Posner ,M.D.; Abraham Schlossman ,M.D.; Syndrome of unilateral recurrent attacks of glaucoma with cyclitic symptoms. *Arch Ophthalmol.* 1948;39(4):517doi:10.1001/archopht.1948.00900020525007.
- [2] Hei Hahn, MD, Mark C. Stillman, MD. A Case of Glaucomatocyclitic Crisis in the Emergency Department.

July 2005.

- [3] *Annals of Emergency Medicine.*,  
[http://www.annemergmed.com/article/s0196-0644\(05\)00399-9/](http://www.annemergmed.com/article/s0196-0644(05)00399-9/) abstract.
- [4] Narang SK, Shah SJ. Glaucomatocyclitic crisis (Posner-Schlossman syndrome) case report. *Indian J Ophthalmol* 1972;20:25-7.
- [5] Green R J et al, Posner schlossman syndrome; *Clin Exp Optom.* 2007 Jan;90(1):53-6
- [6] PMID: 3727952 [PubMed - indexed for MEDLINE], *Arch Ophthalmology.*  
<http://www.ncbi.nlm.nih.gov/pubmed/3727952>
- [7] Jap Aliza, Sivalumar Meenakshi et al. (1998) .Posner Schlossman syndrome benign? *Ophthalmol.* Manuscript no. 99796. DOI: [http://dx.doi.org/10.1016/S0161-6420\(01\)00551-6](http://dx.doi.org/10.1016/S0161-6420(01)00551-6)

## Author Profile



**Dr Rajiv Kumar Das** received his MBBS and MS (Ophthalmology) from Assam Medical College, Dibrugarh. He also holds a postgraduate diploma in health management from IGNOU. He is working as a refractionist in the ophthalmology department of his Alma Mater and currently undergoing PhD under Srimanta Sankaradeva University of Health Sciences, Assam. His keen interest is in community ophthalmology and research in genetics of diabetic retinopathy.