

Hypospadias Repairs and Their Outcome in a Medical College Hospital in Rural India – A Prospective Study

Dr. Sunil Kumar .V¹, Dr. Keshav Murthy², Dr. Nanditha .G³, Dr. Prathik .R⁴

¹Associate Professor & consultant Endoscopist, Department of Surgery, PESIMSR, Kuppam, A.P., India

²Consultant Paediatric Surgeon, Department of Pediatric Surgery, PESIMSR, Kuppam, A.P., India

³Assistant Professor, Department of Pediatrics, PESIMSR, Kuppam, A.P., India

⁴Postgraduate, Department of Surgery, PESIMSR, Kuppam, A.P., India

Abstract: *Hypospadias is a common congenital defect in male children. Though it has been studied extensively and the corrective surgeries exist in numbers, an ideal surgical procedure is not defined. Aim: to study the various types of hypospadias presenting to our hospitals and to study the outcomes of hypospadias repairs. Materials & methods: A prospective study conducted at PESIMSR, Kuppam, A.P., India from Jan 2011 to Dec 2013 and follow-up till Dec 2014. Results: A total of 22 children underwent the hypospadias repairs during Jan 2011 to Dec 2013. 59% underwent Snodgrass, 9% underwent Duckett's and 32% underwent staged type of urethroplasties. We had 2 fistulae and 3 minor skin dehiscence as our complications. Majority of the parents of our patients were happy and satisfied with surgical corrections. Conclusion: The surgical techniques are best when tailored according to the patient's condition, in terms of good postoperative outcome. Snodgrass tubularised incised plate urethroplasty is a good single staged surgical technique with minimal post-operative complications and can be practised widely.*

Keywords: Hypospadias, Chordee, meatus, urethroplasty, urinary stream.

1. Introduction

Hypospadias is one of the most common congenital defects affecting male external genitalia. The incidence of hypospadias is around 1 in 250 male newborns[1, 2].

Embryo studies suggest the penis initially exhibits ventral curvature, which on arrest of normal development, can persist as hypospadias[3]. The ventral curvature was initially ascribed to fibrous tissue bands, but histology from embryos and resected surgical specimens have demonstrated well-vascularised tissues without fibrosis[4, 5]. The underlying cause for non-syndromic hypospadias in most of the individual cases is unknown, though several causes like familial factors, gene mutations, endocrinopathies involving androgen pathways, endocrine disrupters and others are being studied based on the presumption that hypospadias represents arrest in normal development of penis[6-14]. There are as many as 200 syndromes associated with hypospadias. Assisted reproduction, paternal subfertility and twin pregnancy has been associated with increased risk of hypospadias[15].

Hypospadias can be classified on the basis of meatus, into 3 categories: **Distal** or anterior hypospadias- glandular, subcoronal types; **Mid-penile** hypospadias- distal penile shaft, midshaft, proximal penile shaft types; **Proximal** or posterior hypospadias- penoscrotal, scrotal, perineal types. Distal hypospadias is more common among western world as against more proximal forms are common in Asia.[1, 2]

Despite the numerous techniques used for hypospadias, the incidence of complications is still high in patients undergoing hypospadias repair[16].

2. Aims and Objectives:

- To study the various types of hypospadias presenting to the hospital.
- To study the outcomes of hypospadias repairs.

3. Materials and methods:

This prospective study was conducted at PESIMSR, Kuppam- a medical college hospital situated in rural part of Andhra Pradesh, India during Jan 2011 to Dec 2014, data regarding surgeries were restricted till Dec 2013 and follow-up till Dec 2014. All the children below 16years of age with the diagnosis of hypospadias who underwent surgical management were included in the study. Those with hypospadias and more than 16years of age were excluded from the study. The children who were circumcised prior to the current presentation were also excluded from the study. The cases were grouped into one of the three surgical groups based on our selection criteria and were operated accordingly, based on parameters like meatal position, urethral plate, chordee and morphology of the glans (Table 1).

Table 1: Selection criteria and patient grouping

Selection criteria	Parameters and according surgeries		
	A	B	C
Meatal position	Coronal, Subcoronal	Midpenile	Peno-scrotal, Perineal
Urethral plate	Good	Poor	Poor
Gross morphology of glans	Conical	Wide hood	Triangular, Poor
Groove in glans	Deep	Shallow	Shallow/ Absent
Chordee	Mild	Moderate	Moderate/ Severe
Surgery of choice	Snodgrass TIP urethroplasty	Duckett's urethroplasty	Staged urethroplasty

All the children strictly underwent our pre-operative preparations.

Pre-operative preparations:

- Screening investigations such as chest radiographs, ECG, blood investigations.
- Inj. HCG 100 I.U/kg i.m. once every 21 days, 3-5 doses for peno-scrotal and perineal hypospadias to improve vascularity & shaft development.
- Routine Anaesthesiology assessment, Paediatric evaluation when required.
- Thorough scrub bath one day prior to surgery.
- Blood grouping.

Just before surgery, betadine scrub painting was done before draping. Again repainted with Betadine scrub, followed by spirit paint with was air dried and parts painted with Betadine solution routinely. Endotracheal general anaesthesia was used for all cases supplemented with spinal anaesthesia in few cases. The part preparation was given utmost importance before commencing surgery. The operating time was around 90 to 120 minutes. Suture materials used were- 6-0 & 5-0 PDS(polydioxanone) for urethroplasty; 5-0 Vicryl(polyglactin) for glansplasty; 4-0 Vicryl for Byar's flap and dorsal inner preputial flaps, - all with round body needles. Infant feeding tube no. 8Fr was used in all cases and glove tourniquet was used for maintaining haemostasis during surgery which was released every 20 minutes. The Snodgrass(group A) surgeries were covered with Dynaplast flower type dressings and the Duckett's & Staged (group B & C) surgeries were completed with Sandwich dressings over the anterior abdominal wall. After surgery routine post-operative protocols were followed.

Post-operative protocols:

- I.V fluids for 6 hours
- I.V. antibiotics for 4-5 days then changed to oral antibiotics
- Oral laxatives, anti-spasmodics, anti-edema drugs were administered till catheter was in situ.
- Oral Paracetamol as analgesic and anti-inflammatory agent was used.
- Flushing of catheter with 2cc normal saline once daily.
- Dressings, if clean were changed on POD-6 and if soaked or in presence of urine leak, was changed immediately.
- Catheter removal was done on POD 12-14

4. Results

A total of 22 children underwent surgeries for correction of hypospadias during this period. Age of subjects ranged from

2years to 9years and children of 2-3years were 40.9% of the study group (table 2, fig 1).

Table 1: Cases according to groups

Selection groups	Cases
A	13 (59%)
B	2 (9%)
C	7 (32%)

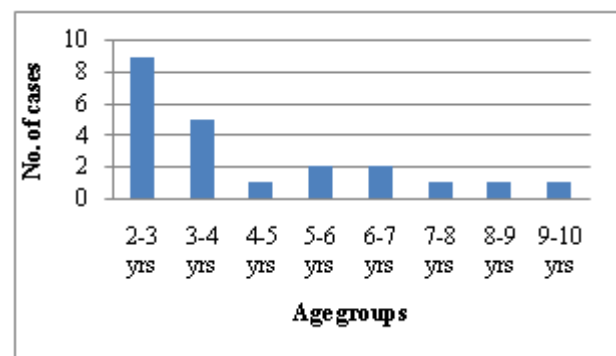


Figure 1: Age distribution

The position of meatal position in hypospadias were – subcoronal 37%, Penoscrotal 27%, coronal 18% and midshaft 18% (fig 2).

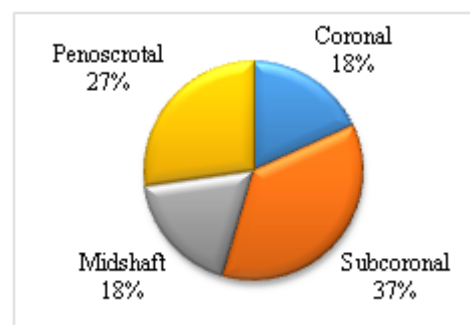


Figure 2: Meatal position in Hypospadias

According to the parameters described, they were categorised into 3 groups and were operated. Group A children(13; 59.09%) were treated with Snodgrass tubularised incised plate urethroplasty, Group B (2; 9.09%) were treated with Duckett's preputial flap urethroplasty and Group C (7; 31.81%) were treated with staged urethroplasties having around 6 months interval between the stages (table 2, fig 3).

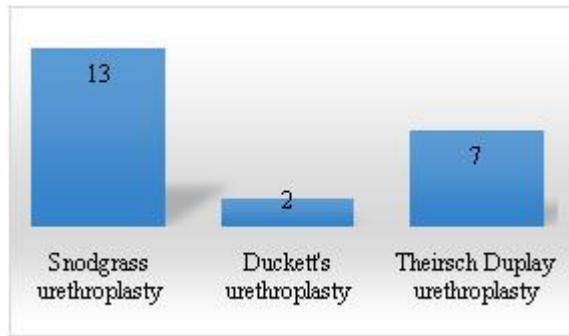


Figure 3: Types of surgeries

The part preparation was given utmost importance before commencing surgery. The operating time was around 90 to 120 minutes. With the routine postoperative protocols and discharge, patients were followed up on the outpatient basis at 2 weeks, 1 month and 6 months interval and in between whenever necessary. We observed 2 fistulas (9%) and 3 minor skin dehiscence (13%) as post-operative complications which were conservatively managed. On interviewing the parents of the patients during the follow-ups, 90.9% parents were satisfied with the results and 9% were worried or not satisfied, parameters being postoperative appearance, urinary stream. Based on surgeries we had 100% parent's satisfaction and least complications with Snodgrass & staged urethroplasties and not so satisfying results with children who underwent Duckett's urethroplasties (chi square p-value <0.001) (fig 4).

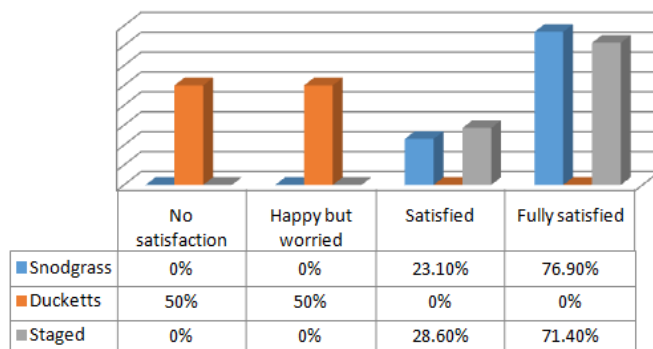


Figure 4: Surgery-wise postoperative satisfaction

We also looked for post-operative complications in comparison with adequacy of weight for age (table 3).

Table 3: Patient satisfaction w.r.t. weight for age

	No satisfaction	Happy but worried	Satisfied	Fully satisfied	Total
Below avg. Wt. for age	1(5.9%)	1(5.9%)	2(11.8%)	13(76.5%)	17
Adequate wt. for age	0	0	3(60%)	2(40%)	5

Though below average weight for age children had few post-operative complications, it was not found to be statistically significant (p-value=0.402)

5. Discussion

There are more than 200 surgeries described for correction of hypospadias. In spite of having so many options, there is no single accurate surgical option as there are variety of presentation of the condition. Several well-established techniques exist for the repair of all hypospadias defects, but there is no single, universally applicable technique for hypospadias repair. Command of a technically straightforward repair with few complications and proven success and versatility in a reasonable range of hypospadias defects are desired goals. The Snodgrass tubularised incised plate urethroplasty, a recent contribution with exemplary early results, has become a popular technique for primary and preoperative repair of middle and distal hypospadias, Duckett's tube repair and staged urethroplasties are commonly considered for proximal and few mid-penile varieties. Other innovative modifications, and technical advances, such as the use of laser and tissue solder, continue to emerge[17-20]. We grouped our patients as described so that hypospadias receives tailored approach for individual cases. We have not used laser or soldering techniques for any of our cases. Preservation of the foreskin or Preputioplasty is also tried and studied for its outcome in combination with various hypospadias repairs[21-23]. The majority of urethroplasty complications are diagnosed with in first year of post-operative follow-up especially in the first follow-up visit[24]. We had 2(9%) fistulae and 3(13%) minor skin dehiscence post-operatively, which were managed conservatively and we didn't had do any re-do surgeries in our study. The follow-up in our study ranges between 4-36months which is adequate to identify urethroplasty related complications. All the children were carefully examined for the post-operative complications in their follow-up, along with the satisfaction of the parents in respect to the urinary stream and appearance of penis.

6. Conclusion:

Hypospadias, though congenital, the time of presentation to the hospital is variable. The surgical techniques are best when tailored according to the patient's condition, in terms of good postoperative outcome. Snodgrass tubularised incised plate urethroplasty is a good single staged surgical technique with minimal post-operative complications and can be practised widely.

7. Limitations of the Study

The study group is small to draw significant conclusions on a single technique. The current study is based on our hospital protocols and is non-randomised. All the available surgical techniques were not studied.

8. Conflict of interest: None

References

- [1] Kraft, K.H., A.R. Shukla, and D.A. Canning, Hypospadias. Urol Clin North Am, 2010. 37(2): p. 167-81.

- [2] Baskin, L.S. and M.B. Ebberts, Hypospadias: anatomy, etiology, and technique. *J Pediatr Surg*, 2006. 41(3): p. 463-72.
- [3] Kaplan, G.W. and D.L. Lamm, Embryogenesis of chordee. *J Urol*, 1975. 114(5): p. 769-72.
- [4] Baskin, L.S., et al., Anatomical studies of hypospadias. *J Urol*, 1998. 160(3 Pt 2): p. 1108-15; discussion 1137.
- [5] Snodgrass, W., et al., Histology of the urethral plate: implications for hypospadias repair. *J Urol*, 2000. 164(3 Pt 2): p. 988-9; discussion 989-90.
- [6] Schnack, T.H., et al., Familial aggregation of cryptorchidism--a nationwide cohort study. *Am J Epidemiol*, 2008. 167(12): p. 1453-7.
- [7] Harris, E.L. and T.H. Beaty, Segregation analysis of hypospadias: a reanalysis of published pedigree data. *Am J Med Genet*, 1993. 45(4): p. 420-5.
- [8] Holmes, N.M., W.L. Miller, and L.S. Baskin, Lack of defects in androgen production in children with hypospadias. *J Clin Endocrinol Metab*, 2004. 89(6): p. 2811-6.
- [9] Beleza-Meireles, A., et al., Risk factors for hypospadias in the estrogen receptor 2 gene. *J Clin Endocrinol Metab*, 2007. 92(9): p. 3712-8.
- [10] Beleza-Meireles, A., et al., Studies of a co-chaperone of the androgen receptor, FKBP52, as candidate for hypospadias. *Reprod Biol Endocrinol*, 2007. 5: p. 8.
- [11] Wang, Z., et al., Up-regulation of estrogen responsive genes in hypospadias: microarray analysis. *J Urol*, 2007. 177(5): p. 1939-46.
- [12] Gray, L.E., Jr., et al., Toxicant-induced hypospadias in the male rat. *Adv Exp Med Biol*, 2004. 545: p. 217-41.
- [13] Snodgrass, W.T., et al., Objective use of testosterone reveals androgen insensitivity in patients with proximal hypospadias. *J Pediatr Urol*, 2013.
- [14] Snodgrass, W.T., C. Granberg, and N.C. Bush, Urethral strictures following urethral plate and proximal urethral elevation during proximal TIP hypospadias repair. *J Pediatr Urol*, 2013. 9(6 Pt B): p. 990-4.
- [15] Wennerholm, U.B. and C. Bergh, Obstetric outcome and follow-up of children born after in vitro fertilization (IVF). *Hum Fertil (Camb)*, 2000. 3(1): p. 52-64.
- [16] Prat, D., et al., Surgical outcome of different types of primary hypospadias repair during three decades in a single center. *Urology*, 2012. 79(6): p. 1350-3.
- [17] Kirsch, A.J., et al., Laser tissue soldering for hypospadias repair: results of a controlled prospective clinical trial. *J Urol*, 2001. 165(2): p. 574-7.
- [18] Kirsch, A.J., et al., Skin flap closure by dermal laser soldering: a wound healing model for sutureless hypospadias repair. *Urology*, 1997. 50(2): p. 263-72.
- [19] Merguerian, P.A., G. Seremetis, and M.W. Becher, Hypospadias repair using laser welding of ventral skin flap in rabbits: comparison with sutured repair. *J Urol*, 1992. 148(2 Pt 2): p. 667-70; discussion 671.
- [20] Nikol'skii, A.D., et al., [The surgical treatment of hypospadias using the CO2 laser]. *Urol Nefrol (Mosk)*, 1994(5): p. 5-7.
- [21] Jayanthi, V.R., The modified Snodgrass hypospadias repair: reducing the risk of fistula and meatal stenosis. *J Urol*, 2003. 170(4 Pt 2): p. 1603-5; discussion 1605.
- [22] Nguyen, M.T., W.T. Snodgrass, and M.R. Zaontz, Effect of urethral plate characteristics on tubularized

incised plate urethroplasty. *J Urol*, 2004. 171(3): p. 1260-2; discussion 1262.

[23] Snodgrass, W.T., et al., Foreskin preservation in penile surgery. *J Urol*, 2006. 176(2): p. 711-4.

[24] Snodgrass, W., C. Villanueva, and N.C. Bush, Duration of follow-up to diagnose hypospadias urethroplasty complications. *J Pediatr Urol*, 2013.

Authors Profile



Dr. Sunil Kumar. V received his M.B.B.S & M.S(gen sur) from Bangalore Medical College(2005) & Madurai Medical College(2010) respectively. He has also obtained D.N.B.(gen sur) in 2012, Diploma in Laparoscopy and travelling fellowship from Association of surgeons of India for Endoscopy and Fellowship in Minimal access surgery- F.M.A.S. from World association of laparoscopic surgeons. He is Fellow of International college of surgeons - F.I.C.S.; Indian association of gastrointestinal endosurgeons- F.I.A.G.E.S. Currently he is Associate professor and consultant endoscopist at PESIMSR, Kuppam, A.P.



Dr. Keshav Murthy has done his M.B.B.S from Mysore, M.S(gen sur) from Bangalore and M.Ch(paed sur) from Maharashtra. He is Member of Royal college of surgeons- M.R.C.S (Edin). Currently he is a teaching faculty in Bangalore and a visiting consultant at PESIMSR, Kuppam



Dr. Nanditha. G. Sunil has obtained her M.B.B.S. from Bangalore Medical College & Research Institute in 2008 and M.D.(paed) from Indira Gandhi institute of child health, Bangalore in 2012. Currently she is working as an Assistant professor in PESIMSR, Kuppam



Dr. Prathik. R has received his M.B.B.S degree from M.S.Ramaiah medical college, Bangalore in 2013 and is currently pursuing his M.S.(gen sur) at PESIMSR, Kuppam.