

# Confronting a Ganglioglioma: Case Report

Thejaswini. B<sup>1</sup>, Aradhana. K<sup>2</sup>, Sruthi. R<sup>3</sup>, R. Nanda<sup>4</sup>, G. V. Giri<sup>5</sup>

<sup>1</sup>MD, Associate Professor, Department of Radiation Oncology, Kidwai memorial Institute Of Oncology, Hosur Road, Bangalore 560029

<sup>2</sup>DNBRT, Associate Professor, Department of Radiation Oncology, Kidwai memorial Institute Of Oncology, Hosur Road, Bangalore 560029

<sup>3</sup>MD, Registrar, Department of Radiation Oncology, Kidwai memorial Institute Of Oncology, Hosur Road, Bangalore 560029

<sup>4</sup>MD, Associate Professor, Department of Radiation Oncology, Kidwai memorial Institute Of Oncology, Hosur Road, Bangalore 560029

<sup>5</sup>MD, Professor, Department of Radiation Oncology, Kidwai memorial Institute Of Oncology, Hosur Road, Bangalore 560029

**Abstract:** Introduction: Gangliogliomas are rare neuroepithelial tumours that account for only 0.4% of the CNS tumours hence no prospective studies are done regarding the management. This case report describes management of ganglioglioma and use of radiotherapy in the adjuvant setting. Case Description: An eight year old girl presented with complaints of seizures and after evaluation underwent craniotomy and decompression. Subsequently was considered for adjuvant radiotherapy as post-op histopathology revealed Anaplastic ganglioglioma grade 3. Post radiotherapy MRI whole brain scan at 9 months showed features of a porencephalic cyst in the treated area with enhancing wall and no significant solid component. A follow up MRI screening scan two years later showed mild decrease in the enhancement of the cyst wall and a neurosurgical opinion was taken where in the patient was advised to be on follow up. Conclusion: Anaplastic gangliogliomas are aggressive tumours which despite being dealt with surgery and radiotherapy have a propensity to recur thereby reiterating the fact of needing an insistent adjuvant therapy which has to be determined in future studies as the definitive treatment options for this tumour have not been elaborated as the tumour is very rare.

**Keywords:** Ganglioglioma, neuro-epithelial tumors, surgery, radiotherapy, brain tumour.

## 1. Introduction

Gangliogliomas are rare neuroepithelial tumors of the central nervous system that were first described in 1926 as a distinct clinico pathological entity. It comprises 0.4% to 1.3% of all brain neoplasms. It is mainly a tumor of young people with 80% of cases presenting younger than 30yrs<sup>1</sup>.

In the world health organization (WHO) Classification 1979, the term ganglioglioma is applied to a rare tumor of central nervous system composed of dysplastic neurons and neoplastic glial cells<sup>2</sup>. Although they can involve any part of neurons, most are supratentorial and involve temporal lobe often causing seizures. Ganglioglioma are classically considered WHO grade I or II. Anaplastic features or necrosis in the glial component can result in upgrading to WHO grade III to IV. It can readily be misinterpreted as anaplastic astrocytoma. Long term survival is possible after aggressive treatment and much more favorable prognosis than malignant gliomas<sup>3</sup>.

Gross tumor resection is considered as the treatment of choice, and the role of radiotherapy is controversial. It is not clear whether postoperative radiation influences the outcome of patients with ganglioglioma. Many physicians are hesitant to administer radiotherapy because of the potential radiation related morbidity in long term survivors. The current data suggests that patient with subtotal resection should be considered for radiotherapy<sup>1</sup>.

## 2. Case Report

A 8 year old girl presented to the hospital in February 2013 with complaints of right focal motor seizures with secondary

generalization for 4 years but with no neurological deficit. She was evaluated with an MRI whole brain scan which revealed a mass lesion having solid cystic component in the left frontal lobe, hypointense on T1 weighted image (Fig 1) and hyperintense on T2 weighted image with peripheral enhancement with mild midline shift and the MRS showed a choline peak(Fig 2).

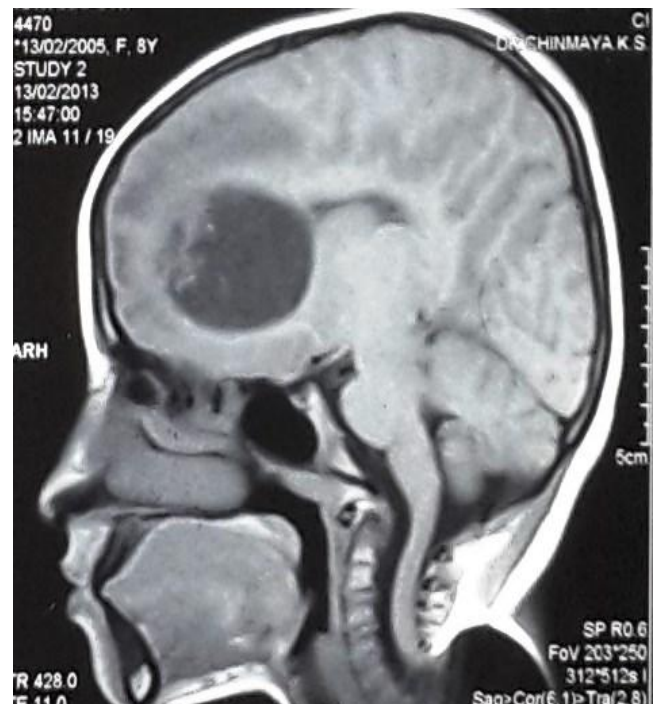
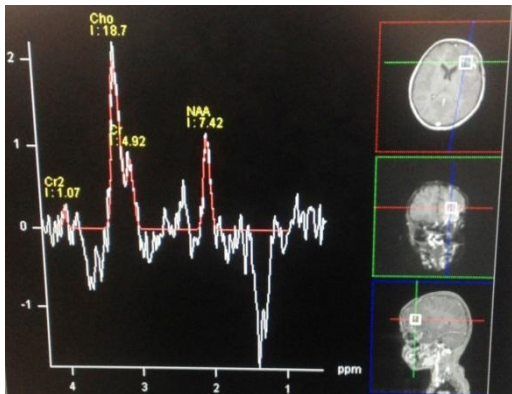


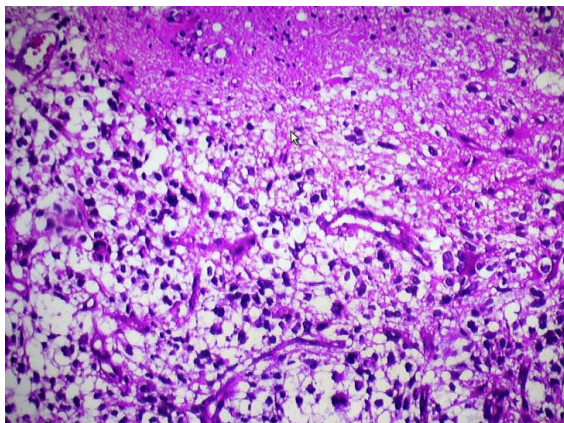
Figure 1: Sagittal section MRI whole brain T1W1 image of ganglioglioma



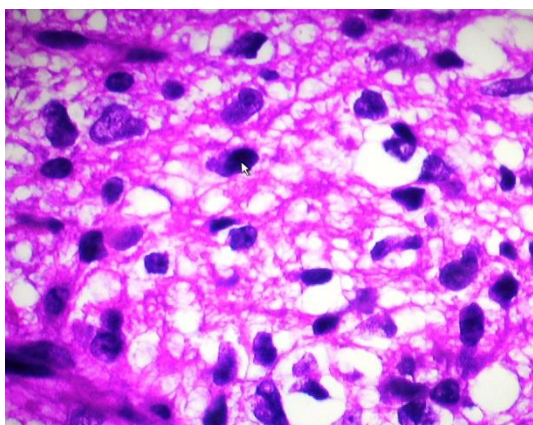
**Figure 2:** MRS image of the lesion showing rise in the choline peak

She underwent left frontal craniotomy and complete decompression of the lesion in February 2013. The histopathology revealed it to be an anaplastic ganglioglioma grade III (Fig 3 and 4). The child had no neurological deficits post operatively. Subsequently received external beam radiotherapy with Intensity modulated radiotherapy technique to a total dose of 54 Gy in 30 fractions over 48 days.

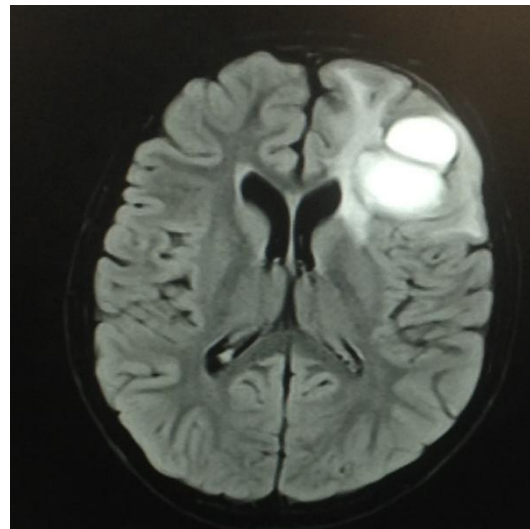
On post treatment followup, MRI scan of whole brain done in the fifth month showed a cyst in the operated area with enhancing wall but had no significant solid component (Fig 5).



**Figure 3:** Photomicrograph of ganglioglioma (low power view).



**Figure 4:** Photomicrograph of ganglioglioma (high power view).



**Figure 5:** Fifth month post radiotherapy follow up MRI scan T2W1 axial image of Cyst with enhanced walls.

She was on regular follow up and asymptomatic for 8 months after which she had 2 episodes of seizures over a span of 1 month and a repeat MRI scan at 9 months post radiotherapy showed features suggestive of a porencephalic cyst. At two years, MRI screening has been done which revealed mild decrease in the enhancement of the cyst wall. A neurosurgical opinion was taken and advised to continue observation.

### 3. Discussion

Ganglioglioma are tumors of low grade malignancy and slow growth with long clinical history. They are well circumscribed and are commonly located in temporal lobe, followed by frontal lobe and less frequently in ventricular regions, thalamus and hypothalamus, parietal & occipital lobe. Most common presenting symptom is seizures. Radiologically it appears as frequently cystic and calcified components. Contrast enhancement may be seen with computed tomography and magnetic resonance imaging, while solid and anaplastic subtypes demonstrate better contrast enhancement<sup>4</sup>.

Most important prerequisite for accurate clinical management, is the correct histo-morphologic diagnosis on conventionally stained histologic slides. Nevertheless, immune-morphologic study has undoubtedly contributed to the understanding of cellular differentiation and composition in ganglioglioma. Several monoclonal antibodies, such as anti-neurofilament polypeptide (NF), antineuron specific enolase (NSE) and antisynaptophysin of ganglion cells are found in ganglioglioma<sup>2</sup>. High neurosecretory activity was documented in ganglioid cells of the tumor ultra structurally and immune-histochemically in a case of ganglioglioma with anaplastic features<sup>5</sup>.

They are composed of both neuronal and glial population. Although malignant transformation is rare, it occurs in glial element. The histological appearance usually resembles anaplastic astrocytoma/ glioblastoma. Although some isolated cases present interesting evidence for a possible etiological role of cranial irradiation in the malignant transformation of ganglioglioma the case is far from proven.

However, case reports add to the body of evidence that suggests the use of postop radiotherapy in selected cases.<sup>6</sup>

Ganglioglioma are very rare and prospective studies are not available. The review suggest that Gross total resection (GTR) as significantly better than subtotal resection (STR) with respect to both local control (LC) and overall survival (OS). Role of RT is poorly defined and controversial. Subtotal resection followed by radiation therapy results in better LC than STR alone, but does not significantly improve OS, both in low grade and high grade subgroups. It appears that a dose escalation beyond 54 Gy does not improve LC compared with dose less than 54Gy regardless of pathologic grade. However given the small number of patients with known radiation dose, recommendations cannot be made from the review studies. The data regarding treatment volume (whole brain vs involved brain with margin) of RT are limited.

In the study by Luyken et.al better local control was associated significantly with favorable tumor site (temporal lobe  $p < .001$ ) lower pathologic grade ( $p < .001$ ) and complete tumor resection ( $p=0.028$ )<sup>7</sup>.

Indications for RT in the literature includes high grade histology, STR and/or recurrence because most failures occur locally<sup>1</sup>. Elective radiation to uninvolved portions of cranio-spinal axis is unnecessary. Conformal techniques should be used optimally with sparing normal tissues. For high grade histology (WHO grade III and IV) adjuvant RT of higher doses (60Gy) is warranted, especially after STR, given the lower likelihood of disease control with surgery alone<sup>6</sup>.

#### 4. Conclusion

Anaplastic Gangliogliomas in view of their rarity and aggressive behaviour with no well defined protocols, need adjuvant therapy post operatively in the form of radiotherapy. The risk benefit analysis of further adjuvant therapy must be weighed and appropriate decision must be taken as they tend to recur with post op radiotherapy alone thereby warranting an aggressive approach of treatment.

#### References

- [1] Stanley L Liauw, Jennifer E Byer, Anthony T Yachnis, Robert J Amdur, William M Mendenhall. Radiotherapy after subtotally resected or recurrent ganglioglioma. *Int J Radiat Oncol Biol Phys* 2007; 67(1):244-7.
- [2] Diepholder H. M, Schwechheimer K, Mohadjer M, Knoth R, Volk B. A clinicopathologic and immunomorphologic study of 13 cases of ganglioglioma. *Cancer* 1991;68: 2192-201.
- [3] Cox J. O, Zimmerman H. M, Haughton V. M. Microcystic ganglioglioma treated by partial removal and radiation therapy. *Cancer* 1982;50: 473-7.
- [4] Faruk Zorlu, Ugur Selek, Cem Onal, Figen Söylemezoğlu, Murat Gurkaynak. Postoperative radiotherapy in cranial ganglioglioma. *Journal of Neuro-Oncology* 2006; 77: 321- 4.
- [5] T.Hirose, S.Kannuki, K.Nishida, K.Matsumoto, T.Sano, K. Hizawa. Anaplastic ganglioglioma of the brain stem

demonstrating active neurosecretory features of neoplastic neuronal cells. *Acta Neuropathol* 1992;83:65-70

- [6] Tarnaris Andrew, Ciaran O'Brien, Robert M. Redfern. Ganglioglioma with anaplastic recurrence of the neuronal element following radiotherapy. *Clinical Neurology and Neurosurgery*;108, Issue 8:761 – 7.
- [7] Dirk Rades , Lena Zwick, Jan Leppert, Matteo M Bonsanto, Volker Tronnier, Juergen Dunst, Steven E. Schild. The role of postoperative radiotherapy for the treatment of gangliogliomas. *Cancer* 2010; 116, Issue 2: 432-442.