

A Case of Electrocution Induced Optic Atrophy

Dr. Jaineel Gandhi¹, Dr. Roopa Naik²

¹Resident, Padmashree Dr. Vithalrao Vikhe Patil Medical College & Hospital, Near Govt. Milk Dairy, Vilad Ghat, Ahmednagar, Maharashtra, India

²Professor and Head of Department Dept of ophthalmology, Padmashree Dr. Vithalrao Vikhe Patil Medical College & Hospital, Near Govt. Milk Dairy, Vilad Ghat, Ahmednagar, Maharashtra, India

Abstract: Introduction: Electrical injuries have emerged as a significant health problem in developing countries because of increase in electrification of rural areas in the last few decades and lack of adequate safety measures. (1) Electrical eye or orbital injuries are not common events. However, they have a broad spectrum, ranging from minimal injury of the lid to complete retinal detachment and total blindness. (2-6). Case report: A 7 years old child presented to ophthalmology OPD with complaints of diminution of vision in both eyes since 2 years, it was gradual in onset and progressive type. Discussion: Electricity can be a serious health and environmental hazard, especially in developing countries where protective measures are almost non-existent. These hazards include contact injuries, electric shocks, electrocutions, burns, fires, explosions and falls. We reported an electric eye injury involving a child who survived a high voltage trauma but unfortunately lost vision in both the eyes. There are many factors that determine the severity of the electric damage and its outcome. These include the type of current, the duration of exposure, the type of tissue surface contact, the extent of multisystem involvement, the duration between exposure and presentation. Conclusion: It is important to note that electrical eye injuries are largely preventable by taking simple and time-tested protective measures such as the use of rubber insulating gloves and shoes, and industrial protective helmets.

Keywords: electrocution, cornea, visual acuity, optic atrophy, ocular, perimetry

1. Introduction

Electrical injuries have emerged as a significant health problem in developing countries because of increase in electrification of rural areas in the last few decades and lack of adequate safety measures. (1) Electrical eye or orbital injuries are not common events. However, they have a broad spectrum, ranging from minimal injury of the lid to complete retinal detachment and total blindness. (2-6)

Boozalis and colleagues reviewed 159 cases of electric burns to determine the ocular sequelae of such injuries. (7) Only 5 (3.1%) of them had eye manifestation (number) including recurrent iritis, cataract, macular holes and central retinal artery occlusion. 7 Of those who had electric-burn associated cataracts, 3 had anterior subcapsular opacification while one had a dense white opacified lens. Ocular changes such as macular cysts, optic nerve damage and retinal changes 8-10 have also been reported. Careful follow-up is recommended because many such cases develop delayed ocular changes.

2. Case Report

A 7 years old child presented to ophthalmology OPD with complaints of diminution of vision in both eyes since 2 years, it was gradual in onset and progressive type. There is history of exposure to electric shock 2 years ago, while the child was playing in field, he got in contact with the water

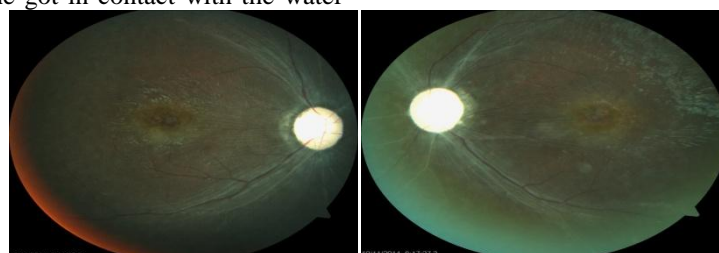motor wire. There was a history of convulsions after the episode of electric shock and he was treated for convulsion but later he discontinued the treatment.

On Ocular Examination:

1. The visual acuity was Finger counting at 1 meters in both eyes, not improving with pin-hole.
2. lids appeared normal
3. Conjunctiva and cornea were within normal limits in both eyes
4. Anterior segment: normal in both eyes
5. Pupils: mid-dilated and sluggishly reacting to light in both eyes
6. Confrontation test showed bilateral generalized constriction of visual field
7. On Fundoscopy: both eyes showed pale optic disc with attenuation of blood vessels.

3. Investigations

- 1) Complete blood count showed all counts within normal limits.
- 2) Serum electrolytes were normal.
- 3) Perimetry showed generalized constriction in visual fields.
- 4) MRI showed bilateral optic atrophy.
- 5) EEG showing normal Electric activity

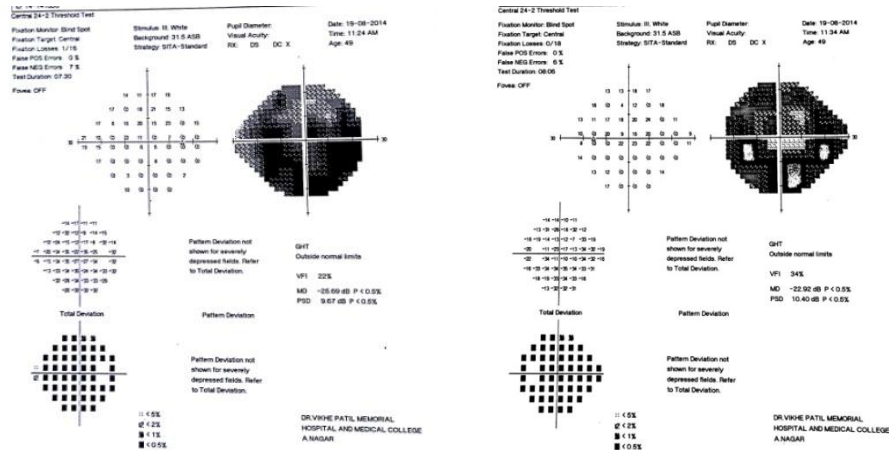


Fundoscopy: both eyes showed pale optic disc with attenuation of blood vessels.

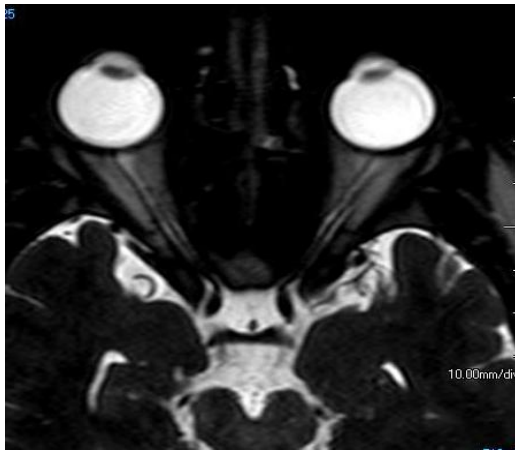
Volume 4 Issue 3, March 2015

www.ijsr.net

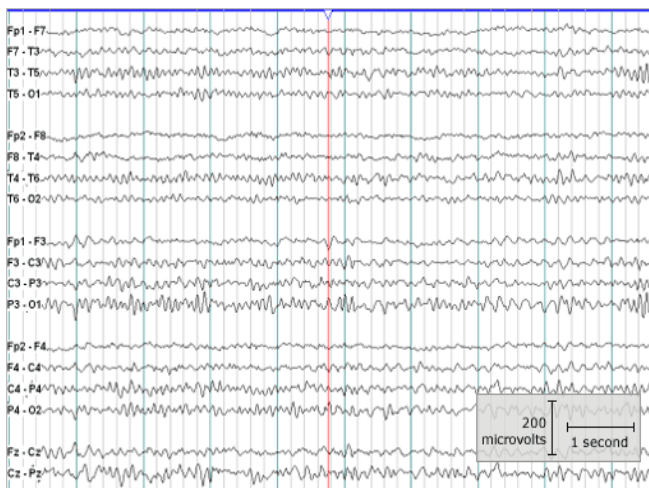
Licensed Under Creative Commons Attribution CC BY



Perimetry showed generalized constriction in visual fields



MRI showed bilateral optic atrophy



EEG showing normal Electric activity

4. Discussion

Electricity can be a serious health and environmental hazard, especially in developing countries where protective measures are almost non-existent.¹ These hazards include contact injuries, electric shocks, electrocutions, burns, fires, explosions and falls. We reported an electric eye injury involving a child who survived a high voltage trauma but unfortunately lost vision in both the eyes.

There are many factors that determine the severity of the electric damage and its outcome. These include the type of current, the duration of exposure, the type of tissue surface contact, the extent of multisystem involvement, the duration between exposure and presentation. Electric eye injuries are uncommon events. There is a wide spectrum of ocular injuries associated with exposure to electricity.^{3,4,6} These include corneal burns, intraocular bleeding, thrombosis, cataract, glaucoma, retinal detachments. Thus ophthalmologists should not only focus on the presenting injuries, but also be aware of the long-term ocular complications. In our patient, he presented to us very late and there was not much we could do about the vision, he was referred to visual rehabilitation center and his parents were explained about the prognosis.

It is important to note that electrical eye injuries are largely preventable by taking simple and time-tested protective measures such as the use of rubber insulating gloves and shoes, and industrial protective helmets. Targeted public awareness programmes can not only save many eyes from going blind but can also save many lives. This case report highlights the importance of seeking immediate medical attention, early intervention and targeted awareness programmes on electricity related ocular and non-ocular hazards.

5. Conclusion

It is important to note that electrical eye injuries are largely preventable by taking simple and time-tested protective measures such as the use of rubber insulating gloves and shoes, and industrial protective helmets. Targetted public awareness programmes can not only save many eyes from going blind but can also save many lives. This case report highlights the importance of seeking immediate medical attention, early intervention and targeted awareness programs on electricity related ocular and non-ocular hazards.

References

- [1] Mashreky SR, Rahman A, Svanstrom L, Khan TF, Rahman F. Burn mortality in Bangladesh: findings of

- national health and injury survey. *Injury* 2011; **42**:507-10.
- [2] Luz DP, Millan LS, Alessi MS, Uguetto WF, Paggiaro A, Gomez DS, *et al.* Electrical burns: a retrospective analysis across a 5-year period. *Burns* 2009; **35**:1015-9.
- [3] Lakosha H, Tremblay F, De Becker I. High-voltage electrical trauma to the eye. *Can J Ophthalmol* 2009; **44**:605-6.
- [4] Hashemi H, Jabbarvand M, Mohammadpour M. Bilateral electric cataracts: clinicopathologic report. *J Cataract Refract Surg* 2008; **34**: 1409-12.
- [5] Grewal DS, Jain R, Brar GS, Grewal SP. Unilateral electric cataract: Scheimpflug imaging and review of the literature. *J Cataract Refract Surg* 2007; **33**:1116-9.
- [7] Khan MR, El Faki H. Acute cataract and optic atrophy after highvoltage
- [8] electrical injury. *Eur J Plast Surg* 2008; **31**:73-4.
- [9] Boozalis GT, Purdue GF, Hunt JL, McCulley JP. Ocular changes from electrical burn injuries. A literature review and report of cases. *J Burn Care Rehabil* 1991; **12**:458-62.
- [10] Sony P, Venkatesh P, Tewari HK, Garg SP. Bilateral macular cysts following electric burn. *Clin Experiment Ophthalmol* 2005; **33**:78-80.
- [11] Bienfang DC, Zakov ZN, Albert DM. Severe electrical burn of the eye. *Albrecht Von Graefes Arch Klin Exp Ophthalmol* 1980; **214**:147-53.
- [12] Al Rabiah SM, Archer DB, Millar R, Collins AD, Shepherd WF. Electrical injury of the eye. *Int Ophthalmol* 1987; **11**:31-40.