

The Unparalleled Presentations of the Hideous Pleomorphic Adenomas - 2 Year Study

Dr. Shreesha Khandige¹, Dr. Suchithra Shetty², Dr. Ragini Thapa^{3*}

¹Professor, Department of Pathology, Yenepoya Medical College, Mangalore

²Assistant Professor, Department Of Pathology, Yenepoya Medical College

^{3*}(Author for Correspondence) Department of Pathology, Yenepoya Medical College, 2 Floor, Academic Block, Mangalore, India

Abstract: *Pleomorphic adenomas arising in the lacrimal gland are extremely uncommon, despite the large numbers of minor mucous and serous glands in the region. We present rare cases(5) compilations of a pleomorphic adenomas arising from the lacrimal gland, a two year study. Age ranged from 45-60years, predominantly women with most common complaints of nasal obstruction for 5-6 months. Flexible nasal endoscopy for all these patients showed a prominent swelling which was in continuity with the anterior part of the right inferior turbinate followed by left inferior turbinate. Computed tomography revealed well-defined, soft tissue dense lesion in the anterior nasal cavity. All the patients underwent a formal surgery to obtain definite diagnosis via a lateral rhinotomy incision. Intra-operatively, a soft mass was seen arising from the lateral nasal wall and the final histology for all 5 cases confirmed pleomorphic adenoma with a predominant stromal component. The main treatment modality is surgical resection with histological clear margins. Good exposure is necessary to ensure complete excision of the tumour, more so when its cellular pattern shows stromal predominance. In our cases, the patients demonstrated satisfactory cosmetic results with no evidence of recurrence.*

Keywords: pleomorphic adenomas lacrimal gland

1. Introduction

Pleomorphic adenomas are the most common neoplasms of the salivary gland, occurring mainly in the parotid, submandibular and sublingual glands. These neoplasms affect females more than males and are commonly seen in the third to sixth decades of life. The pleomorphic adenoma is the most common benign glandular tumor originated in the head and neck (1,2). It is the tumor that most commonly affects the major salivary glands, specially the parotid glands in 80% of the cases. The minor salivary glands are only affected in 8% of the cases, generally in soft and hard palates (3). It seldom affects other areas of the aerodigestive tract.

In the nasal cavity, its most frequent location is the quadrangular cartilage, followed by the nasal lateral wall, mainly the infundibula (4). Maxillary sinus pleomorphic adenoma cases are rarely described in the literature (4). While pleomorphic adenomas are highly uncommon in the nasal cavity, approximately 80% of nasal pleomorphic adenomas are detected in the nasal septum, while the remaining 20% are found in the lateral wall or turbinate despite the fact that a significant proportion of mucous and serous glands is confined to the lateral nasal wall (5).

The reason for the predilection of nasal pleomorphic adenomas to lateral nasal wall has been postulated by some authors. Stevenson suggested that remnants of the vomeronasal organ, an epithelium-lined duct in the cartilaginous nasal septum degenerated in early foetus, could be the reason for the appearance of these tumours in the nasal turbinate (2). Whereas, Ersner and Saltzman postulated that the precursors of the septal pleomorphic adenomas are ectopic embryonic epithelialised cells on the nasal septum mucosa, found during the migration of the nasal buds

(3,4,5). We present a rare case of a pleomorphic adenoma arising from the lateral nasal wall.

2. Materials and Method

5 cases of Lacrimal gland pleomorphic adenomas were studied over a period from June 2012 to December 2014 using routine histopathological, histochemical and immunohistochemical methods wherever indicated and possible. Paraffin blocks and haematoxylin and eosin stained slides from archives were reviewed for histopathological examination. Clinical details with results of imaging studies were collected and results were correlated with the pathological findings

3. Results

Out of the 5 cases studied the majority of cases were located in the 80%(4/5) lacrimal gland parotid gland followed by minor salivary glands. No cases were found in the sublingual gland. The mean age was 42.9 (± 16) years ranging from 13 to 90 years and the peak of incidence was in the fourth and fifth decades. (3/5) cases (60%) were in females while (2/5) (40%) in males. PA were classified as stroma-rich in 3 cases (60%), cell-rich in (1/5) (20%) and classic in 1 case (20%). Plasmacytoid cells were the most commonly found cellular type, being present in all studied tumors and were the predominant cellular type in 6. They represented less than 30% of the tumor cells in 60% cases. Spindle cells were present in 50%, representing the second most frequent cellular type. It was. Cuboidal cells were found in 80% of the case. Basaloid cells were present in 40% of cases. Squamous cells were found in 40% of the cases. Clear cells were present in only (40%) cases. Mucous and oncocytic cells were considered occasional findings. Mitosis were rare. Trabeculae formation was found in 60%

of the cases. . Ductal, cystic and solid formations were also observed. Myxochondroid stroma was present in 80% of the cases(Figure 3-6). Myxoid areas were found in 100% of the cases corresponding . Chondroid areas were seen in 80% of the cases .Tumor cells were immunopositive for keratin , indicating their duct-epithelial or squamous cell differentiation, while some were positive for both keratin and S-100 protein, indicating their myoepithelial cell differentiation.The CT scan confirmed in all cases ,a well-defined, soft tissue dense, smooth margined lesion of small to medium size in the right anterior nasal cavity, abutting the anterior part of the right inferior turbinate medially, cartilaginous part of the nasal septum and anterolateral wall of the right nasal cavity without eroding them. In majority of the cases ,the anterior nasal septum deviated towards the left. Initial biopsy were unhelpful as it revealed inferior turbinate type tissue with no pathological findings.The final histology in most of the cases showed a pleomorphic adenoma with a lobulated, biphasic morphology(Figure 1-3). The stromal component were predominantly myxochondroid with no evidence of malignancy . The post-operative recovery was uneventful and all patients were in good condition.

4. Discussion

Pleomorphic adenomas arising in the nasal cavity are extremely rare, despite the large numbers of minor mucous and serous glands in the region (4). Patients often seek medical attention because of nasal obstruction, epistaxis or the presence of a nasal mass.Histologically, pleomorphic adenomas of the nasal cavity differ in certain characteristics. The nasal cavity tumours have greater cellularity and contain more epithelial components than the chondroid, myxoid and collagenous stromal components that are seen in pleomorphic adenomas of the parotid gland. The relatively low rate of recurrence is attributed to diminished amount of myxoid stroma of intranasal tumours (7.5%) [4].Motoori et al. (5) reported a case of recurrence in which the nasal pleomorphic adenoma had a cellular pattern with many areas of myxoid stromal predominance. It is postulated that the myxoid stroma could easily be spilled into the surgical field,

providing a focus for recurrence (4). Interestingly, the pleomorphic adenoma in this case has stromal predominance and resembles a typical adenoma of the parotid gland more closely than one of the nasal cavity.The main treatment modality is complete surgical resection with histological clear margins. Recent literature has advocated the effectiveness of conservative excision via an intranasal endoscopic approach in eliminating disease with no recurrence on follow up (6 ,7). However, histologically the pleomorphic adenoma in these cases showed a predominance of epithelial rather than stromal elements.The surgical approach should depend on the size, location and extension of the tumour. In this case, the lateral rhinotomy method was chosen because the nasal tumour was very anterior, displacing the maxilla and abutting the inferior turbinate medially. The concern was that the anterior location of the nasal tumour would not have allowed adequate access via an endoscopic approach for complete resection.It is a well known fact that there is always risk of recurrence, regardless of where the tumour arises from. The recurrence rate of pleomorphic adenoma depends almost on the sufficiency of the initial excision. Surgery for recurrent tumours often does not produce desirable results (8). Hence, good exposure is necessary to ensure complete excision of the tumour, more so when its cellular pattern shows stromal predominance.Given the rarity of the intranasal pleomorphic adenoma and heterogeneity of its behaviour, no standard treatment algorithm has been established. Nevertheless, post-operative follow up examination is mandatory in view of its potential for recurrence. In our case, the patient demonstrated satisfactory cosmetic results with no evidence of recurrent disease during subsequent follow up visits.

5. Conclusion

In summary, these results emphasize the immense variety of cells, architectures and morphological characteristics present in PA of the salivary gland. Since PA is the most frequent salivary gland neoplasia and can resemble other salivary gland tumors, the knowledge about these variations and locations is essential for a correct diagnosis.

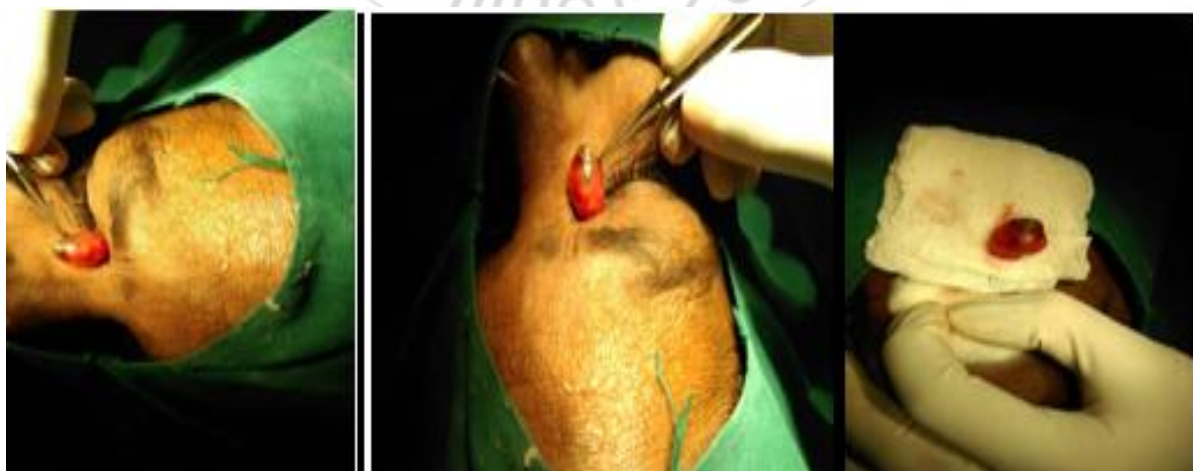

Figure (1-3): Excision of the tumour mass situated in the lacrimal gland. Picture showing the modified excision of the lesion.

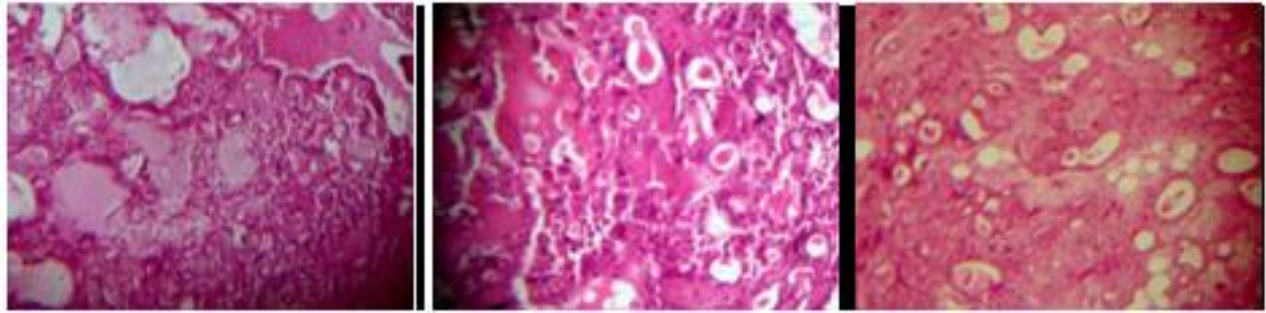


Figure (3-6): Histopathological picture showing an encapsulated lesion comprising of duct like spaces

References

- [1] J. Batsakis Tumor of the head and neck Williams and Wilkins, Baltimore (1984), pp 76–99
- [2] H.N. Stevenson Mixed tumor of the septum Ann Otol Rhinol Laryngol, 41 (1932), pp. 563–570
- [3] Felix JAP, Tonon S, Saddy JC et al. Adenoma pleomórfico de septo nasal: relato de caso e revisão da literatura. Rev Bras Otorrinolaringol. 2000, 66:409-412.
- [4] Rocha MP, Campagnolo AM, Macedo VS et al. Adenoma pleomórfico de septo: relato de caso. Rev Bras Otorrinolaringol. 2004, 70:416-418.
- [5] Patrocínio TG, Patrocínio JÁ, Patrocínio LG. Adenoma pleomórfico nasal: ressecção via degloving médio-facial. Arq Int Otorrinolaringol. 2006, 10:154-158.
- [6] Berenholz L, Kessler A, Segal S. Massive pleomorphic adenoma of the maxillary sinus. Int J Oral Maxillofac Surg. 1998, 27:372-373.
- [7] Compagno J, Wong RT. Intranasal mixed tumors (pleomorphic adenomas). A clinicopathologic study of 40 cases. Am J Clin Pathol. 1977, 68:213-218.
- [8] M.J. Ersner, M. Saltzman A mixed tumor of the nasal septum. Report of a case. Laryngoscope, 54 (1944), pp. 287–296

