

Laurence Moon Bardet Biedl Syndrome- Case Report and Review of Literature

Dr.P.Rajasekhar¹, Dr.M.Parni Kumar², Dr.P.S.Aalekhya³

¹M.S. Assistant Professor of Ophthalmology, Guntur Medical College, Guntur, A.P., India

²M.S, Professor of Ophthalmology, Guntur Medical College, Guntur, A.P., India

³Post Graduate in Ophthalmology, Guntur Medical College, Guntur, A.P., India

Abstract: *Laurence Moon Bardet Biedl syndrome is an autosomal recessive genetic disorder with variable expressivity and a wide range of clinical variability observed both within and between families. It includes Laurence Moon syndrome with features of Retinitis pigmentosa(Rod-cone dystrophy), mental retardation, hypogenitalism and spastic paresis and Bardet Biedl syndrome as Retinitis pigmentosa, obesity, postaxial polydactyly, learning disabilities and hypogenitalism in males. We report a typical case of Laurence Moon Bardet Biedl syndrome in a female showing all ocular features, most of the general features and a typical family history. There is a typical early onset of blindness in this case.*

Keywords: Retinitis pigmentosa, polydactyly, mental retardation, hypogenitalism, obesity, consanguinous marriage.

1. Case Report

Here is a case of 32 year old female who came to our OPD , Ophthalmology department, Government General Hospital, Guntur with complaints of night blindness, jerky eye movements since childhood which progressed gradually over years. She is born of consanguinous marriage. Had developmental delay. Mentally retarded. The other female sibling and parents were normal but there is family history of similar presentation in one of their relatives . Systemic examination revealed obesity , polydactyly (hexadactyly) and syndactyly in both upper and lower limbs, ataxic gait and hypogonadism. Ophthalmic examination revealed only perception of light in both eyes with nystagmus and left eye exotropia. On slit lamp examination there is Posterior subcapsular cataract *in both the eyes*. Fundus examination revealed pale, waxy optic disc with attenuation of arterioles and bony corpuscular pigment seen at periphery giving the impression of Primary typical Retinitis pigmentosa with consecutive optic atrophy .

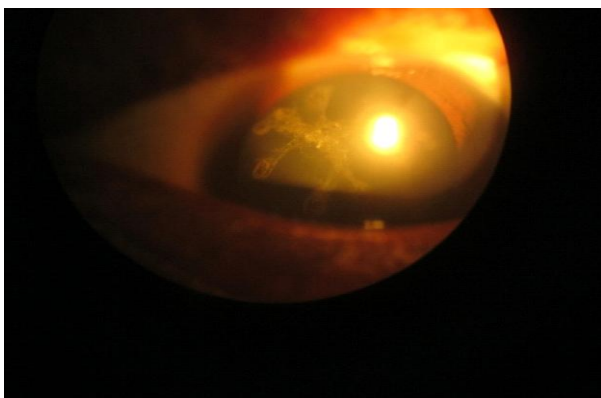


Figure 1: Picture showing Posterior subcapsular cataract

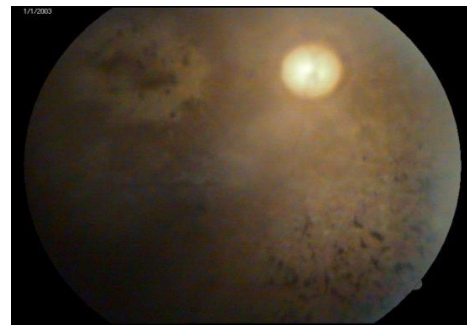

Figure 2: Fundus picture showing bony corpuscular pigmentation and consecutive optic atrophy

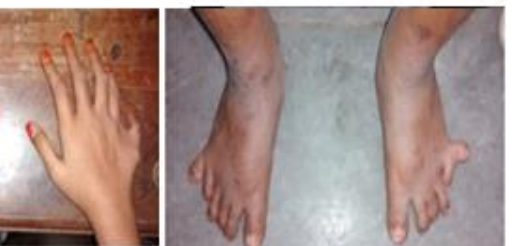
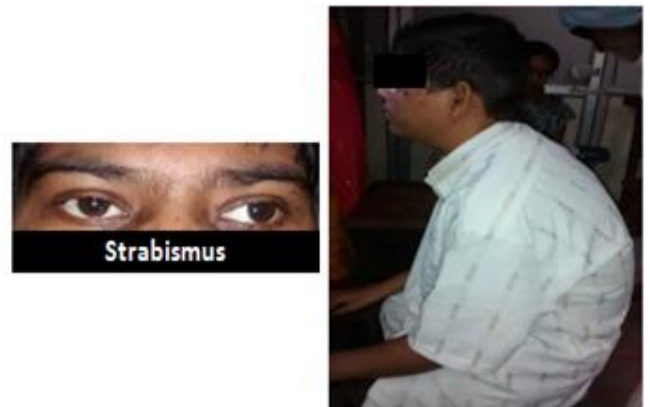
Figure 3: Showing Polydactyly

2. Discussion

Laurence Moon Biedl Bardet syndrome was first defined by Bardet in 1922 as an autosomal recessive disorder characterized by structural and functional abnormalities of organs and tissues with diverse embryonic derivation. The five cardinal features of syndrome include – polydactyly , pigmentary retinopathy , obesity , mental retardation and hypogonadism . Other systemic features include short stature , congenital heart block , deafness and neurological disorders .

Laurence Moon Biedl Bardet syndrome is a rare genetic disorder. Biedl in 1922 added mental deficiency and genital hypoplasia to this syndrome . In 1925 Solis-Cohen and Weiss connected to this syndrome the four patients in one family described by Laurence and Moon in 1966. Solis-Cohen and Weiss coined the name Laurence Moon Biedl syndrome. The cases reported by Laurence and Moon were reevaluated and reported by Hutchinson , the members were found to have a disease characterized by typical pigmentary retinopathy , mental retardation arrest of sexual development and progressive weakness leading to paraplegia.

3. Conclusion

We report a typical case of Laurence Moon Bardet Biedl syndrome in a female of 32 years old with significant family history. She presented with an early onset blindness and all ocular features like Retinitis pigmentosa, optic atrophy, posterior subcapsular cataract, strabismus and nystagmus. She also showed characteristic general features of obesity, polydactyly, syndactyly. She also had mental retardation and developmental delay.

References

- [1] Fauci Braunwald Casper Hauser Coyo Jameson Localso, 17th edition, Harrison's Principles of Internal Medicine Volume-II, Part 15:Endocrinology and Metabolism, Section-I- Endocrinology, 333- Disorders of Anterior Pituitary and Hypothalamus pg-2198.
- [2] Jack J Kanski and Brad Bowling , 7th edition, Clinical Ophthalmology, 15th chapter- Hereditary Fundus dystrophies-Generalized photoreceptor dystrophies.
- [3] Fauci Braunwald Casper Hauser Coyo Jameson Localso, 17th edition, Harrison's Principles of Internal Medicine Volume-II, Part 15:Endocrinology and Metabolism, Section-I- Endocrinology, 340-Disorders of testis and male reproductive system Congenital disorders associated with gonadotropin deficiency , pg 2316.
- [4] Putoux A, Attie-Bitach T, Martinovic J, et al; Phenotypic variability of Bardet-Biedl syndrome: focusing on the kidney. *Pediatr Nephrol.* 2012 Jan;27(1):7-15. Epub 2011 Jan 19.
- [5] Bardet-Biedl Syndrome, Online Mendelian Inheritance in Man (OMIM).
- [6] Pereiro I, Valverde D, Pineiro-Gallego T, et al; New mutations in BBS genes in small consanguineous families with Bardet-Biedl *Mol Vis.* 2010 Feb 1;16:137-43.

- [7] Karaman A; Bardet-Biedl syndrome: a case report. *Dermatol Online J.* 2008 Jan 15;14(1):9.