

Uterine Fibroid Embolization and Overview of Complications

Walid M. Asaad¹

¹Department of Diagnostic and Interventional Radiology, King Abdulaziz University Hospital
Al-Moustashfa Road, Jeddah 22252, Kingdom of Saudi Arabia

Abstract: *Leiomyomas (or fibroids) are exceedingly common lesions. The indications to initiate treatment are based on the symptoms that can arise from their presence. In general, medical therapy should be considered the first line of treatment. Currently, uterine artery embolization (UAE) has been shown to be a safe, efficacious, and a cost-effective alternative to traditional surgical options, with data from long-term studies now available. Appropriate patient evaluation and selection are vital. Here we report a case of symptomatic uterine fibroids which failed medical therapy and showed dramatic improvement after uterine artery embolization and was discharged on appropriate treatment. Additionally, a review of the current literature is discussed.*

Keywords: Fibroid, Leiomyoma, Embolization, Amenorrhea, Myomectomy.

1. Introduction

Uterine fibroids or leiomyomas are estrogen responsive benign tumors composed of smooth muscles and an extracellular matrix of collagen and elastin. They are exceedingly common lesions, occurring in up to 50% of women in some ethnic groups (the incidence is greatest among women of African descent). Although fibroids often are asymptomatic and do not require treatment, symptomatic fibroids (25%-30% of women with fibroids) can cause significant morbidity. The indications to initiate treatment for fibroids are based on the symptoms that arise from their presence. These are most commonly divided into menstrual disturbances and bulk-related symptoms. Menorrhagia or polymenorrhagia are the most common symptoms associated with uterine fibroids. Although intermenstrual bleeding or metromenorrhagia can occur with uterine fibroids, this type of dysfunctional uterine bleeding requires investigation to exclude malignancy or other endometrial pathology [1], [2]. Bulk-related complaints, most often caused by an enlarged fibroid uterus, include back pain, heaviness or pelvic pressure, abdominal bloating, constipation, urinary frequency, and ureteral obstruction.

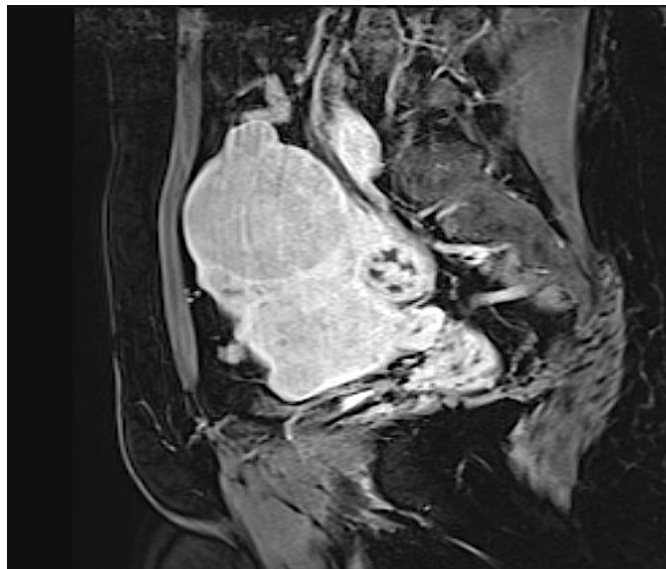
It is interesting to note that the severity of symptoms has not been shown to correlate with fibroid size and even small fibroids can have a significant impact on the quality of a woman's life. All types of fibroids can cause menstrual disturbances or bulk-related symptoms; however, submucosal fibroids are more commonly associated with abnormal uterine bleeding whereas subserosal fibroids are more likely to cause bulk-related symptoms.

Until the past two decades, surgical management was the most commonly practiced therapy for uterine fibroids and uterine artery embolization (UAE) was first used as a temporization procedure prior to hysterectomy or myomectomy. It was not until the 1990s when UAE evolved as an independent therapy for uterine fibroids. The majority of the literature supports the theory that UAE shortens hospital stays and decreases the overall rate of major

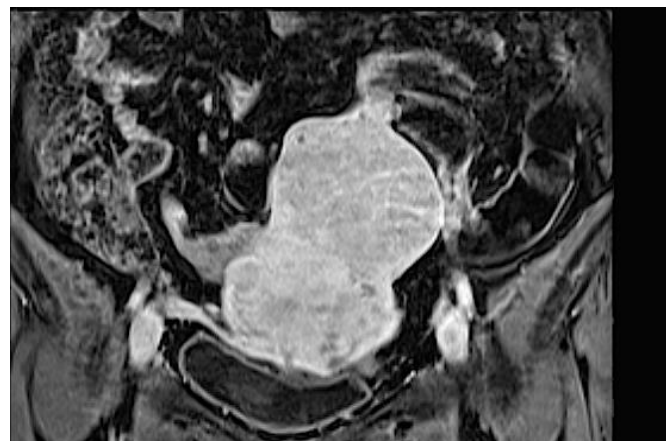
complications [3], [4], [5].

2. Case Report

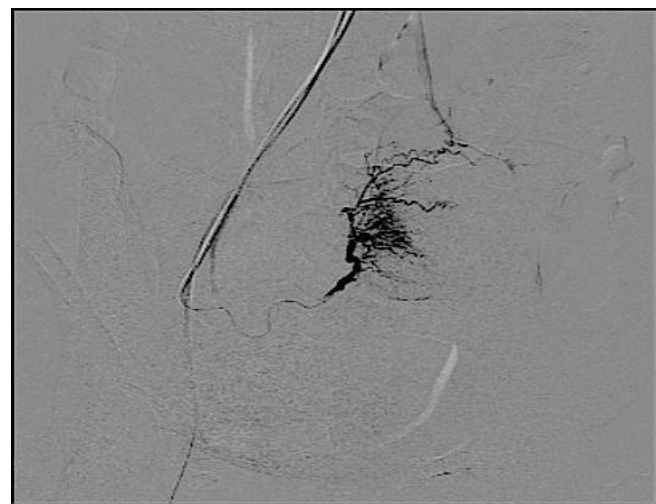
A 43-year-old G1P1 patient with known fibroid disease for several years and prior myomectomy but an otherwise uneventful gynecological history presented to our hospital with menorrhagia and a feeling of tightness and pressure in the pelvic area. Menstrual bleeding had worsened over the previous 7 months and remained unchanged despite medical therapy. Hysterectomy was offered for treatment of menorrhagia. The patient refused surgery and opted for uterine fibroid embolization instead and was referred to the interventional radiology clinic. MRI on admission revealed multiple intramural leiomyomas with a predominant fundal mass (Figure 1). In preparation for the procedure, intravenous antibiotic 1g Cefazoline (Eli Lilly & Co., Indianapolis, IN) was administered prior to the procedure [6]. Under conscious sedation, ultrasound guided access to the right common femoral artery was performed and a pelvic angiogram was obtained to identify any significant supply to the uterus and fibroids from the ovarian artery. In a sequential manner, selective arteriography of the transverse segment of each uterine artery with a combination of a 5Fr Roberts Uterine Catheter (Cook Medical INC., Bloomington, IN) and a 3Fr Progreate Microcatheter (Terumo Corporation, Tokyo, Japan) in a coaxial fashion was performed. Transarterial catheter-directed bilateral embolization of the fibroids was performed using 500–700 µm tris-acryl gelatin microspheres (Embosphere; Biosphere Medical, Paris, France). Total of 30 mg of IV ketorolac during the course of the procedure was administered. No ovarian artery contribution was noted. The procedure itself was uneventful. The patient was admitted for 24hr's to insure adequate pain and nausea control. The patient was discharged the following day on NSAID and pain control medications. Antinausea and stool softeners medications were prescribed as needed. A follow-up phone call the next day insured adequate pain control and no indications of acute complications. The patient was followed with monthly phone calls for 6 months at which time she came for follow up imaging. A contrast-enhanced MRI revealed complete



(a)



(b)



(c)

Figure 1: (a,b) Gadolinium-enhanced, fat-suppressed T1-weighted, sagittal and coronal magnetic resonance imaging (MRI) demonstrate a dominant fundal intramural fibroid. (c)

Prior to embolization, right uterine arteriography demonstrates opacification of the dominant fibroid mass.

infarction of the fibroid masses while perfusion of the surrounding myometrium was preserved (Figure 2). She described her menses being light and regular while tightness

and pressure in the pelvic area had essentially resolved. In addition, she reported vaginal discharge for about 4 months with occasional expulsion of tissue fragments.

3. Discussion

Uterine leiomyoma is a benign and well-defined tumor of the myometrium that can have essentially a submucosal, intramural, or subserosal location. Subserosal and submucosal fibroids may be described as exophytic or pedunculated. Exophytic fibroids have a broad-based attachment to the uterus; pedunculated fibroids are attached to the uterus by a stalk generally narrower than 50% of the diameter of the fibroid.

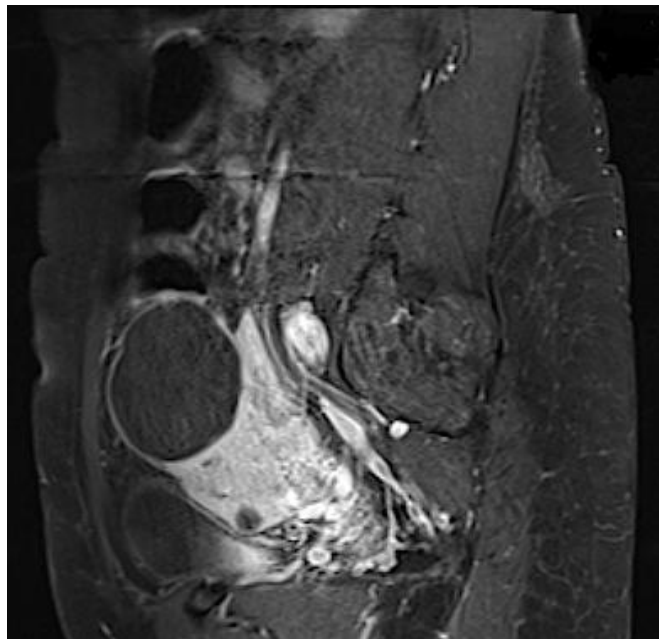
Ideally, the interventional radiologist planning to perform the procedure should have a preprocedure outpatient clinic consultation visit with the patient to develop a relationship and discuss the procedure risks, benefits, and the expected outcome. UAE candidates include women with symptomatic fibroids who express the desire for uterine preservation and avoidance of surgical intervention. The Ontario Uterine Fibroid Embolization Trial. Part 1, highlighted that symptoms, particularly heavy menstrual bleeding, rather than fibroid or uterine size, were responsible for the high life-impact scores in this cohort. The study also illustrates that large numbers of women with highly symptomatic fibroid disease are averse to surgery despite their burden of suffering and are actively seeking alternatives to hysterectomy [7].

Preprocedurerevaluation for UAE should include a comprehensive history and physical examination, a recent gynecologic examination performed by an OB/GYN specialist, a recent Pap smear, an endometrial biopsy for patients with dysfunctional uterine bleeding, and imaging documenting the presence of uterine fibroids. A complete blood count (CBC), renal function tests, coagulation profile, and a pregnancy test should routinely be requested. Additional tests that can be considered are follicle-stimulating hormone (FSH) and estradiol levels before and after the procedure to assess baseline and post procedure ovarian function, which may be of interest due to the potential for ovarian injury during UAE.

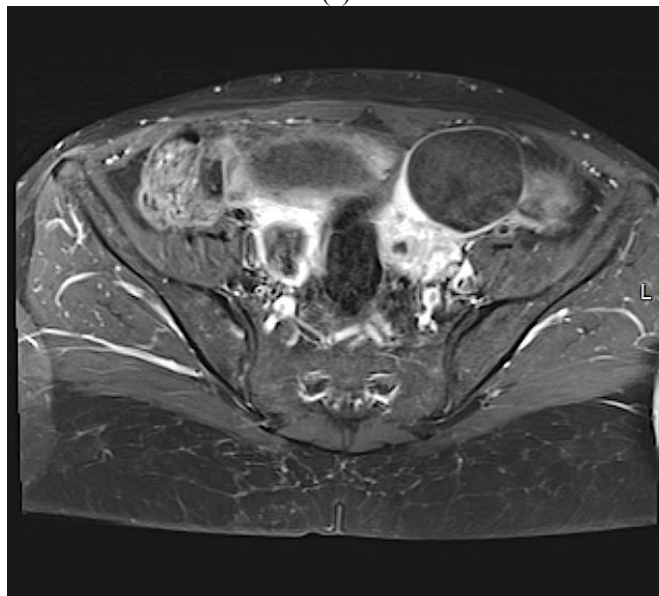
Generally, exclusion criteria include pregnancy; patients with severe renal insufficiency not receiving dialysis; history of pelvic irradiation; ovarian, endometrial, uterine or cervical carcinoma; pelvic inflammatory disease or other pelvic infection and endometritis [8]. The desire to maintain fertility is a relative contraindication because of procedure-related complications such as the need for hysterectomy or the potential for ovarian failure. Therefore, it is currentlyrecommended by the Society of Interventional Radiology and other groups that UAE not be offered as first-line therapy for patients with an explicit desire for future pregnancy [9]. In such individuals, myomectomy is preferred, with UAE reserved for individuals who cannot or will not undergo myomectomy.

Typically, UAE is technically successful in 95 to 99% of cases. The Ontario Uterine Fibroid Embolization Trial. Part 2 revealed that UAE reduced fibroid uterine volume and

provided significant relief of menorrhagia that was unrelated to initial fibroid uterine size or volume reduction. Significant



(a)



(b)

Figure 2: (a,b) Gadolinium-enhanced, fat-suppressed T1-weighted, sagittal and axial magnetic resonance imaging (MRI) demonstrate complete embolization of uterine fibroids.

improvements were reported for menorrhagia (83%), dysmenorrhea (77%) and the mean menstrual duration was significantly reduced (7.6 to 5.4 days). Median uterine and dominant fibroid volume reductions were 35% and 42%, respectively and urinary frequency/urgency also improved (86%). The majority (91%) expressed satisfaction with UAE treatment. A prospective multicenter comparative study between myomectomy and UAE related to the long-term clinical outcomes concluded that UAE was associated with greater sustained improvements in symptom severity and health-related quality of life with fewer complications [10], [11].

From an economically point of view, UAE is less expensive than hysterectomy even when accounting for potential need of repeat procedures or associated complications [12]. Hysterectomy is a major surgical procedure typically requiring 5 days of hospitalization for the immediate postoperative recovery, and the long-term recovery period can range from 4 weeks to as long as 6 months. On the other hand, patients treated with UAE are typically discharged the following day after watchful observation and symptomatic treatment.

UAE do come with complications, however, most common issues that arise are management issues rather than complications. These include pain, post embolization syndrome and vaginal discharge. Natural expulsion of dead fibroid tissue has been reported up to one year and occurs in 2.5%-5% of UAE patients overall [9], [13], [14], [15]. It may occur in as many as 20 to 25% of patients who have dominant submucosal fibroids which usually resolves with spontaneous passage of the tissue [16]. It is important to note that persistent pain cannot be taken lightly. A major complication occurs when an infarcted fibroid persists partially exposed through the cervix — a nidus for infection that may lead to endometritis, pelvic abscess formation, and endometrial ischemic necrosis [17]. These patients will need immediate supportive care including intravenous fluids and antibiotics. In addition, the first-line therapeutic intervention is hysteroscopic removal, and in severe cases when this treatment fails, hysterectomy may be required.

Vaginal discharge has been reported up to 6 months, but usually resolves by one month [18]. This usually results when a small communication forms between an infarcted, superficial fibroid and the endometrial cavity.

Recent series that have examined complication rates in large series of UAE cases have shown rates of significant complications in the range of 1 to 3%. Major complications documented in the acute post procedure phase (up to 24 hours post procedure) include puncture site hematoma, bleeding requiring transfusion, drug reaction, septicemia, and vasovagal response requiring atropine. Patients with venous compression by an enlarged fibroid uterus and with suspected extended hospital stay are susceptible, although uncommon, to develop a pulmonary embolus. Such patients may benefit from daily subcutaneous heparin injections. Spies et al reported a pulmonary embolus as a single major complication in a series of 200 consecutive patients and that patient was successfully treated with therapeutic anticoagulation [19]. In the subacute (from 24 hours to 1 week postprocedure) to chronic phase (> one week postprocedure), major complications reported include sepsis, pelvic abscess, hematometra, uterine rupture secondary to uterine necrosis, and uterine necrosis requiring hysterectomy [3], [4], [20], [21], [22], [23], [24].

In multicenter trials, the major complication rates reported consistently reflect a lower number of major adverse events (AE) related to UAE as opposed to major AEs related to surgical management. In the REST trial (2007), the major complication rate for UAE was 12% within the first year versus 20% for surgically managed patients [4]. In the HOPEFUL trial (2007), UAE patients experienced a 4.5%

major complication rate compared with 14.8% in the surgical patients [21]. In the EMMY trial (2005), a 1.3% major complication rate was assigned to UAE and a 1.2% major complication rate was assigned to surgical patients. However, when bleeding requiring blood transfusion is added to the calculations, the UAE major complication rate remains 1.3%, but the surgical major complication rate increases to 14.5% [3].

Nontarget organ embolization has been documented, and is most likely to affect the ovaries, given the extensive collateral vascular network between the ovarian and uterine arteries. In cases of secondary ovarian embolization, patients may experience transient or permanent amenorrhea and may experience premature menopause. The published data from the FIBROID Registry, revealed that 7.3% of patients undergoing UFE developed amenorrhea with 86% of these patients were 45 years of age or older [25]. In the Ontario Uterine Fibroid Embolization Trial. Part 2, Amenorrhea occurring after the procedure was highly age dependent, ranging from 3% (1%–7%) in women under age 40 to 41% (26%–58%) in women age 50 or older [26].

However, nontarget organ embolization is a largely preventable complication. Hehenkamp et al described using larger polyvinyl alcohol (PVA) particles of 500 to 700 μ m when anastomosis with an ovarian artery is observed so as to prevent the particles from reaching the distal organ [3]. Pelage et al also demonstrated the same [27]. In 2005, Spies et al reported the first results comparing 36 UAE patients treated with either spherical PVA or Embospheres [28]. In this report, patients treated with Embospheres reported a greater improvement in quality of life score compared with patients treated with spherical PVA. In addition, pelvic MRI at 3 months following UAE showed a significantly higher fibroid infarction rate. In 2008, Siskin et al published a prospective, randomized study comparing fibroid infarction using spherical PVA and Embospheres [29]. The authors concluded that given the known risk of recurrence in patients with persistent fibroid enhancement, Embospheres should be the preferred embolic agent of choice for UAE.

Loss of ability to achieve orgasm, both internal and clitoral, was reported by Lai et al in a 41-year-old woman 6 days after UFE [30]. By her 6-month follow up, she reported an improvement in her pelvic pain, increase in energy and libido, and had regained the ability to achieve clitoral orgasm while her inability to achieve internal orgasm persisted. This finding may have been related to nontarget embolization of cervicovaginal arterial branches.

Fertility after UAE remains a major issue and in fact patients are advised against attempting pregnancy postprocedure as there is an increased risk of abortion and still births. In the literature, however, numerous successful pregnancies and successful live births after UAE are documented, including both normal vaginal deliveries and cesarean deliveries. Dutton et al report as high as 19 successful live births [21]. Ravina et al report 6 successful pregnancies [32] and Edwards et al document 2 successful live births [4]. However, the study by Mara et al (2008) directly examined the differences in pregnancy rates in patients who underwent UAE procedure compared with those who underwent

myomectomy. It concluded, UAE is less invasive and as symptomatically effective and safe as myomectomy, but myomectomy appears to have superior reproductive outcomes in the first 2 years after treatment but definitive case comparison should need a larger population and a longer follow up [33].

In 2004, the Society of Interventional Radiology produced quality improvement guidelines for interventional radiologists performing UAE to summarize the literature and delineate expected outcomes of the procedure [9]. These guidelines were created by performing an in-depth literature search of peer-reviewed articles and the intended purpose of the guidelines was to “insure the standard of care expected of all physicians” who perform UAE. Expected outcomes were defined as a fibroid and uterine size reduction between 50 to 60% and 40 to 50%, respectively, a reduction in bulk-related symptoms ranging between 88 to 92%, elimination of dysfunctional uterine bleeding in > 90% of patients, and elimination of all fibroid-related symptoms in 85% of patients following UAE [34]. As far as UAE complications, the guidelines produced suggested thresholds for various complications, including transient amenorrhea (10%), permanent amenorrhea (age < 45 years = 3%, age > 45 years = 15%), transcervical fibroid expulsion (5%), endometrial or uterine infection (2%), uterine necrosis (1%), and nontarget embolization (1%).

4. Conclusion

UAE has emerged as a valuable treatment for fibroid disease. The popularity of the procedure can be attributed to the safety and efficacy of the procedure as well as the high patient satisfaction reported in the literature. However, the procedure is not without risk of complications therefore proper patient selection and meticulous procedural technique are essential for achieving UAE success.

References

- [1] Spies JS, Pelage JP. Uterine artery embolization and gynecologic embolotherapy. Philadelphia: Lippincott Williams & Wilkins; 2005:3–18
- [2] CarinGonsalves, Uterine Artery Embolization for Treatment of Symptomatic Fibroids. *Semin Intervent Radiol* 2008;25:369–377
- [3] Hehenkamp WJ, Volkers NA, Donderwinkel PF, et al. Uterine artery embolization versus hysterectomy in the treatment of symptomatic uterine fibroids (EMMY trial): Peri- and postprocedural results from a randomized control trial. *Am J ObstetGynecol* 2005;193:1618–1629
- [4] Edwards RD, Moss JG, Lumsden MA, et al. Uterine artery embolization versus surgery for symptomatic uterine fibroids. The REST investigators. *N Engl J Med* 2007;356:360–370
- [5] Tami C. Carrillo, et al. Uterine Artery Embolization in the Management of Symptomatic Uterine Fibroids: An Overview of Complications and Follow-up. *Semin Intervent Radiol* 2008;25:378–386
- [6] Ali Zarrinpar, Robert K. Kerlan, Jr., A Guide to Antibiotics for the Interventional Radiologist. *Seminars*

- in Interventional Radiology, volume 22, number 2, 2005
- [7] Pron, Gaylene et al. The Ontario Uterine Fibroid Embolization Trial. Part 1. Baseline patient characteristics, fibroid burden, and impact on life Fertility and Sterility, Volume 79, Issue 1, 112 – 119
 - [8] Goodwin SC, Bonilla SM, Sacks D, et al. Reporting standards for uterine artery embolization for the treatment of uterine leiomyomata. J VascInterv Radiol 2001;12(9): 1011–1020
 - [9] Hovsepian DM, Siskin GP, Bonn J, et al. Quality improvement guidelines for uterine artery embolization for symptomatic fibroids. J VascInterv Radiol 2004;15:535–541
 - [10] Pron G, Bennett J, Common A, et al. The Ontario Uterine Fibroid Embolization Trial. Part 2. Uterine fibroid reduction and symptom relief after uterine artery embolization for fibroids. FertilSteril 2003;79(1):120–127
 - [11] Siskin GP, Shlansky-Goldberg RD, Goodwin SC, et al. A prospective multicenter comparative study between myomectomy and uterine artery embolization with polyvinyl alcohol microspheres: Long-term clinical outcomes in patients with symptomatic uterine fibroids. J VascInterv Radiol 2006;17: 1287–1295
 - [12] Wu O, Briggs A, Dutton S, et al. Uterine artery embolization or hysterectomy for the treatment of symptomatic uterine fibroids: a cost-utility analysis of the HOPEFUL study. BJOG 2007;114:1352–1362
 - [13] Spies JB, Spector A, Roth AR, Baker CM, Mauro L, Murphy-Skrzynarz K. Complications after uterine artery embolization for leiomyomas. ObstetGynecol 2002;100: 873–880
 - [14] Berkowitz RP, Hutchins FL, Worthington-Kirsch RL. Vaginal expulsion of submucosal fibroids following uterine artery embolization: a report of three cases. J Reprod Med 1999;44:373–376
 - [15] Jones K, Walker WJ, Sutton C. Sequestration and extrusion of intramural fibroids following arterial embolization: a case series. Gynaecologic Endoscopy 2000;9:300–313
 - [16] McLucas B, Goodwin S, Adler L, Rappaport A, Reed R, Perella R. Pregnancy following uterine artery embolization. Int J GynObstet 2001;74:1–7
 - [17] Gabriel H, Pinto CM, Kumar M, et al. MRI detection of uterine necrosis after uterine artery embolization for fibroids. AJR Am J Roentgenol 2004;183:733–736
 - [18] Walker WJ, Carpenter TT, Kent ASH. Persistent vaginal discharge after uterine artery embolization for fibroid tumors: 939 cause of the condition, magnetic resonance imaging appearance, and surgical treatment. Am J ObstetGynecol 2004;190: 1230–1233
 - [19] Spies JB, Ascher SA, Roth AR, Kim J, Levy EB, Gomez- Jorge J. Uterine artery embolization for leiomyoma. ObstetGynecol 2001;98:29–34
 - [20] Andersen PE, Lund N, Justesen P, et al. Uterine artery embolization of symptomatic uterine fibroids. Acta Radiol 2001;42:234–238
 - [21] Dutton S, Hirst A, McPherson K, Nicholson T, Maresh MA. UK Multicenter retrospective cohort study comparing hysterectomy and uterine artery embolization for the treatment of symptomatic uterine fibroids (HOPEFUL study): main results on medium term safety and efficacy. BJOG 2007;114:1340–1351
 - [22] McLucas B, Adler L, Perrella R, et al. Uterine fibroid embolization: nonsurgical treatment for symptomatic fibroids. J Am CollSurg 2001;192:195–105
 - [23] SiskinGP,StainkenBF,DowlingK,etal.Outpatientuterine artery embolization for symptomatic uterine fibroids: experience in 49 patients. J VascInterv Radiol 2000;11(3):305–311
 - [24] Pinto I, et al. Uterine fibroids: uterine artery embolization versus abdominal hysterectomy for treatment: a prospective, randomized, and controlled clinical trial. Radiology 2003; 226:425–431
 - [25] Spies JB, Myers ER, Worthington-Kirsch R, et al. The FIBROID registry: symptom and quality-of-life status 1 year after therapy. ObstetGynecol 2005;106:1309–1318
 - [26] Pron, Gaylene et al. The Ontario Uterine Fibroid Embolization Trial. Part 2 Uterine fibroid reduction and symptom relief after uterine artery embolization for fibroids. Fertility and Sterility, Volume 79, 2003 Jan;79(1):120-7
 - [27] Pelage JP, Laurant A, Wassef M, et al. Uterine artery embolization in sheep: comparison of acute effects with polyvinyl alcohol particles and calibrated microspheres. Radiology 2002;224:436–445
 - [28] Spies JB, Allison S, Flick P, et al. Spherical polyvinyl alcohol versus tris-acryl gelatin microspheres for uterine artery embolization for leiomyomas: results of a limited randomized comparative study. J VascInterv Radiol 2005;16:1431
 - [29] Siskin GP, Beck A, Schuster M, et al. Leiomyoma infarction after uterine artery embolization: a prospective randomized study comparing tris-acryl gelatin microspheres versus polyvinyl alcohol microspheres. J VascInterv Radiol 2008; 19(1):58–65
 - [30] Lai AC, Goodwin SC, Bonilla SM, et al. Sexual dysfunction after uterine artery embolization. J VascInterv Radiol 2000; 11:755–758
 - [31] Ahmad A, Qadan L, Hassan N, Najarian K. Uterine artery embolization treatment of uterine fibroids: effect on ovarian 22. function in younger women. J VascInterv Radiol 2002; 13:1017–1020
 - [32] RavinaJH,HerbetreauD,Ciraru-VigneronN,etal.Arterial embolization to treat uterine myomata. Lancet 1995;346: 671–672
 - [33] Mara M, Maskova J, Fucikova Z, et al. Midterm clinical and first reproductive results of a randomized controlled trial comparing uterine fibroid embolization and myomectomy. Cardiovascular Intervent Radiol 2008;31:73–85
 - [34] Goodwin SC, Spies JB, Worthington-Kirsch R, et al. Uterine artery embolization for treatment of leiomyomata: long-term outcomes from the FIBROID Registry. ObstetGynecol 2008;111(1):22–33