

# A Rare Cause of Chronic Cough: Tracheobronchopathia Osteochondroplastica

Pinar CIMEN<sup>1</sup>, MD, Mehmet UNLU<sup>2</sup>, MD

<sup>1,2</sup>Izmir Training and Research Hospital for Thoracic Medicine and Surgery, Pulmonary Division, 35210 Yenisehir, Izmir-Turkey

**Abstract:** *Tracheobronchopathia osteochondroplastica (TO) is a rare disease of unknown etiology and only sporadic cases have been reported in the literature. This disease may be presented with a nonspecific symptom such as persistent cough and exact diagnosis may be delayed. This report describes a case presented with an only symptom of prolonged cough and could be diagnosed lately as TO. Physicians should consider TO in the differential diagnosis of persistent cough and further evaluation should be performed in order to identify the underlying cause in patients with chronic cough.*

**Keywords:** Tracheobronchopathia osteochondroplastica, chronic cough, bronchoscopy, diagnosis, treatment

## 1. Introduction

Tracheobronchopathia osteochondroplastica (TO) is an uncommon benign disease of unknown etiology characterized by multiple cartilaginous or bony submucosal nodules which project into the tracheobronchial lumen. Clinical manifestations of patients with TO are variable and nonspecific, and the disease may be manifested by prolonged cough leading delay of the diagnosis. Here we describe a case with a persistent cough and poor response to antitussive drugs which could be diagnosed as TO after 6 months.

## 2. Case Report

A 58-year-old female presented to our hospital with progressive dry cough for the last 6 months. She had been prescribed antitussive drugs for several times but her complaints were not reduced. She was a housewife and had no work-life history. There was no past history of a chronic disease. Her smoking history was 6 packs/year and she had been quitted smoking more than 10 years ago. She had never consumed illicit drugs and had no allergies.

On admission, the patient had a respiratory rate of 15 breaths/minute, a blood pressure of 120/70 mmHg, and a heart rate of about 80 beats/minute with sinus rhythm. Chest auscultation revealed normal lung sounds. Examination of the blood samples revealed only iron deficiency anemia (haemoglobin: 10.5 g/dl). Number of leukocytes, thrombocytes, and results of blood chemistry were within normal limits. Erythrocyte sedimentation rate was 10 mm/h and serum level of C-reactive protein was 0.5 mg/dl. Pulse oximeter revealed oxygen saturation as 98% on room air.

Her chest radiograph was including normal radiological features. Computerized tomography of the thorax (Thorax-CT) demonstrated multiple calcified nodules in the anterolateral wall of trachea, sparing the posterior tracheal membrane (**Figure 1**). She underwent flexible bronchoscopy (FOB) which showed that submucosal nodules protruded into the airway lumen (**Figure 2**). Histopathological examination of forceps biopsies taken from these nodules found ossification and cartilage in the submucosal layer

(**Figure 3**). Based on clinical, radiological and histopathological findings, she was diagnosed as TO. She was treated with inhaled corticosteroids and 3 months later her symptoms significantly attenuated.

## 3. Discussion

TO was reported firstly by Wilks in 19th century in a man with tuberculosis (**1**). The etiology of the disease is still unknown and the incidence of TO ranges from 0.01% to 4.2% (**2, 3**). There is no gender predominance. Although TO is usually diagnosed in person over 50 years old, it may also found in children (**4**).

Clinical manifestations of TO patients are variable and nonspecific. Some patients are asymptomatic while others may suffer from persistent cough, hemoptysis, dyspnea, dryness of throat, recurrent lower respiratory tract infection, atelectasis, and difficult intubation (**5, 6**). Because typical symptoms are absent, TO is most likely under diagnosed. Jabbardarjani et al. showed that chronic dyspnea was the most common symptom in study which evaluated 10 patients with TO (**7**). However, Leske et al. found that the most frequent (%54) complaint was chronic cough (**5**). In addition, some patients were initially thought to have asthma because of presentation with recurrent wheezing (**8**). The patient in this case was also suffering from persistent dry cough without any other respiratory symptoms which lead to a delay in diagnosis.

The X-ray appearance of TO has no any characteristics. Thus, a clear chest radiograph does not exclude the diagnosis of TO. Thorax-CT is more valuable in identifying tracheobronchial lesions. Characteristic feature of TO in Thorax-CT is multiple submucosal calcified nodules involving the anterior and lateral walls of trachea and main bronchi, with sparing of posterior membranous portions (**9**). There are small (typically 3 to 8 mm) calcific nodules along inner tracheal aspect and protruding into the tracheal lumen. Even though imaging studies may give clue to the diagnosis, bronchoscopy is the most definitive diagnostic test. The bronchoscopic appearance is characterized by the multiple, varied size smooth whitish nodules (**10**). These nodules are hard on touch and gives gritty sensation while passing the scope through the lumen. Biopsy is no essential since the

typical appearance of FOB is enough to make a diagnosis. However, histopathological findings may help to rule out other diseases such as tracheobronchial amyloidosis, relapsing polychondritis, mucoepidermoid carcinoma, papillomatosis, and sarcoidosis (11, 12). When biopsy is performed, the histopathological features are characterized by ossification and calcification in the submucosa, and mucosal squamous metaplasia (13). In this case, forceps biopsy was performed for differential diagnosis and histopathological study demonstrated ossification and cartilage formations in the submucosa compatible with TO.

There is no definitive treatment available for TO and treatment is only offered to symptomatic cases (14). Management mainly includes maintaining airway humidity, reduction of airway irritation and treatment of respiratory infections. Inhaled corticosteroids have also been used for deal with TO. Leske et al. treated respiratory condition with inhaled corticosteroids in 8 of the 41 TO cases (5). In severe cases like airway stenosis, various bronchoscopic interventions have been tried like removal of nodules by forceps, laser ablation, cryotherapy and external beam irradiation mechanical measures to remove obstruction nodules using either cryotherapy, laser excision, external beam irradiation, radiotherapy, stent insertion or surgical resection therapy (7, 15). Prognosis is generally good but it is related with degree of airway involvement and luminal narrowing.

In conclusion, physicians should consider TO in patients with chronic cough and FOB should be performed in order to uncover the underlying cause.

#### 4. Conflict of Interest

The authors have no conflict of interest to disclose. No acknowledgement, no financial or material support. Written informed consent was obtained from the patient for publication of this case report and accompanying images. A copy of the written consent is available for review by the Editor-in-Chief of this journal.

PC: Concept and design of the study, acquisition of data, analysis and interpretation of data, revising the article critically for important intellectual content, final approval of the version to be published

MU: Concept and design of the study, acquisition of data, analysis and interpretation of data, revising the article critically for important intellectual content, final approval of the version to be published

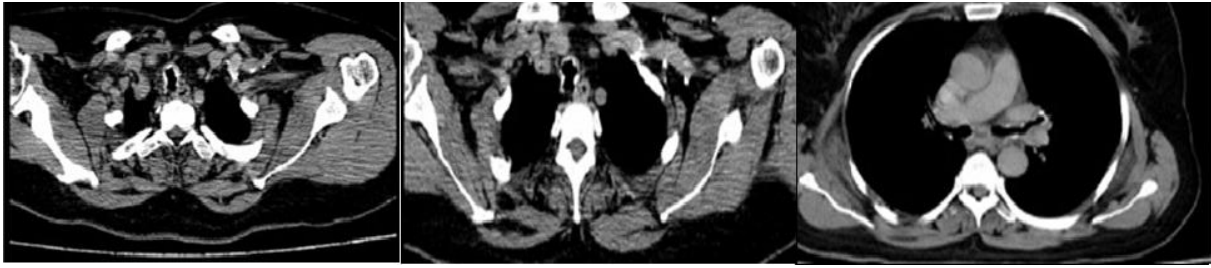#### References

- [1] Wilks S. Ossific deposits on the larynx, trachea and bronchi. *Trans Pathol Soc Lond* 1857;8:88.
- [2] Lundgren R, Stjernberg NL. Tracheobronchopathia osteochondroplastica. A clinical bronchoscopic and spirometric study. *Chest* 1981;80:706-9.
- [3] Baran A, Gungör S, Unver E, Yilmaz A. Tracheobronchopathia osteochondroplastica: a case report. *Tuberk Toraks* 2004;52:183-5.
- [4] Simsek PO, Ozcelik U, Demirkazik F, Unal OF, Orhan D, Aslan AT, et al. Tracheobronchopathia osteochondroplastica in a 9-year-old girl. *Pediatr Pulmonol* 2006;41:95-7.
- [5] Leske V, Lazor R, Coetmeur D, Crestani B, Chatté G, Cordier JF; Groupe d'Etudes et de Recherche sur les Maladies "Orphelines" Pulmonaires (GERM"O"P). Tracheobronchopathia osteochondroplastica: a study of 41 patients. *Medicine (Baltimore)* 2001;80:378-90.
- [6] Coëtmeur D, Bovyn G, Leroux P, Niel-Duriez M. Tracheobronchopathia osteochondroplastica presenting at the time of a difficult intubation. *Respir Med* 1997;91:496-8.
- [7] Jabbaridajani HR, Radpey B, Kharabian S, Masjedi MR. Tracheobronchopathia osteochondroplastica: presentation of ten cases and review of the literature. *Lung* 2008;186:293-7.
- [8] Hayes D Jr. Tracheopathia osteoplastica misdiagnosed as asthma. *J Asthma* 2007;44:253-5.
- [9] Onitsuka H, Hirose N, Watanabe K, Nishitani H, Kawahira K, Matsuura K, et al. Computed tomography of tracheopathia osteoplastica. *AJR Am J Roentgenol* 1983;140:268-70.
- [10] Prince JS, Duhamel DR, Levin DL, Harrell JH, Friedman PJ. Nonneoplastic lesions of the tracheobronchial wall: radiologic findings with bronchoscopic correlation. *Radiographics* 2002;22 Spec No:S215-30.
- [11] Prakash UB. Tracheobronchopathia osteochondroplastica. *Semin Respir Crit Care Med* 2002;23:167-75.
- [12] Meyer CN, Døssing M, Broholm H. Tracheobronchopathia osteochondroplastica. *Respir Med* 1997;91:499-502.
- [13] Abu-Hijleh M, Lee D, Braman SS. Tracheobronchopathia osteochondroplastica: a rare large airway disorder. *Lung* 2008;186:353-9.
- [14] Zhang XB, Zeng HQ, Cai XY, Zhang YJ. Tracheobronchopathia osteochondroplastica: a case report and literature review. *J Thorac Dis* 2013;5:E182-4.
- [15] Khan AM, Shim C, Simmons N, Chung V, Alterman DD, Haramati LB, et al. Tracheobronchopathia osteochondroplastica: a rare cause of tracheal stenosis--"TPO stenosis". *J Thorac Cardiovasc Surg* 2006;132:714-6.

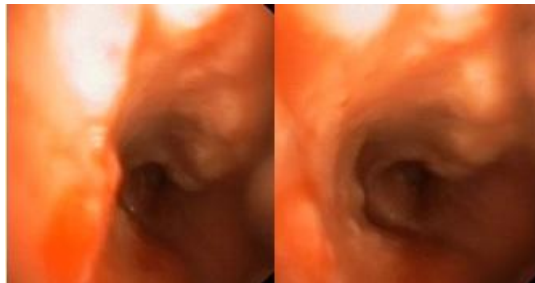
#### Author Profile

**Dr. Pinar CIMEN** is a specialist of Pulmonology in Izmir Training and Research Hospital for Thoracic Medicine and Surgery, Izmir-TURKEY.

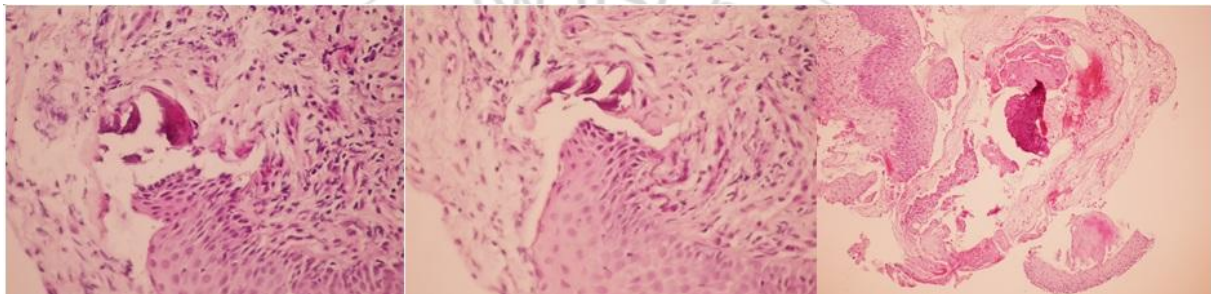
**Dr. Mehmet UNLU** is a specialist of Pulmonology in Izmir Training and Research Hospital for Thoracic Medicine and Surgery, Izmir-TURKEY.



**Figure 1:** Thorax-CT images of the patient on admission



**Figure 2:** FOB images of the patient



**Figure 3:** Histopathological view of the biopsy demonstrating ossification and cartilage formations in the submucosa

